

Original Research Article

Cryptosporidiosis in HIV Infected and Non-Infected Patients with Diarrhoea in a Teaching Hospital Hyderabad, India

Soumendra Nath Maity¹, Syed Shafeequr Rahman¹,
Cinthaparthi Mallikarjun Reddy², Hima Bindu¹ and Indu kapur¹

¹MallaReddy Institute of Medical Sciences, Hyderabad, India

²Mallareddy Medical college for Women, Hyderabad, India

*Corresponding author

ABSTRACT

Keywords

Human
Immuno-
deficiency
Virus (HIV),
Protozoa,
*Cryptosporidium
parvum*,
Diarrhea,
Modified Zeihl-
Neelsen staining

Diarrhea is a common complication among HIV infected individuals. *Cryptosporidium parvum* is the most common parasite-causing diarrhea in immunocompromised patient, mainly affect children and elderly individuals. The study is designed to know the prevalence of Cryptosporidiosis in HIV patients and non-HIV patients attending our hospital. Materials and Methods- We examined 57 stool samples from HIV infected patients with diarrhea and 754 faecal samples from non-HIV patients with diarrhea by modified Ziehl-Neelsen and Giemsa staining. Findings- 22 stool samples were positive for oocyst of *Cryptosporidium* in HIV infected patients and 19 were positive in Non-HIV patients. All 41 stool samples were positive for *Cryptosporidium* by modified Ziehl-Neelsen method and 39 by Giemsa staining. Conclusions- There is a high prevalence of Cryptosporidiosis in HIV infected patients and simple modified ZN staining can detect oocyst in stool sample.

Introduction

Gastrointestinal infections are more common in non-hygienic places, especially in developing countries. Intestinal parasitic infections are more common in immunocompromised patients, children and elderly individuals (Celine Nguefeu Nkenfou et al., 2013). Worldwide emergence of Human Immunodeficiency Virus (HIV) has become a major public health problem. AIDS is the end stage of Human Immunodeficiency Virus infection, which leads to decrease in the immunity

level in affected persons. Due to the impaired immunity, these persons become more liable to infection with opportunistic microorganisms (Aruna Aggarwal et al., 2005).

Opportunistic infections in HIV infected patients vary from region to region (Ayyagari A et al., 1999). As per National AIDS Control Organisation (NACO) data, tuberculosis is the most common infection in AIDS patients followed by candidiasis and

cryptosporidiosis (NACO, 1999). Parasitic infections are more common in developing countries than developed countries (Framm SR et al., 1997). The etiological agents of gastroenteritis include infections with bacteria, parasites, virus and fungi (Mitra AK et al., 2001). Intestinal parasites have been reported major cause of severe chronic diarrhea in HIV infected patients (Janoff EN et al., 1988). Among all the parasites coccidian parasites, *Cryptosporidium parvum*, *Isospora belli*, *Cyclospora cayetanensis* and *Entamoeba histolytica* are the most common etiological agents causing diarrhea in HIV infected persons worldwide (Ekejindu IM et al., 2010; Hammouda NA et al., 1996).

Cryptosporidium, intracellular protozoa is responsible for causing diarrhea in animals and humans worldwide. Human infections are transmitted through ingestion of contaminated food and water or by contact with infected animals (SitaraSwarna RA et al., 2008). *Cryptosporidium* is most common parasitic agent-causing diarrhea in HIV infected persons, usually causing bulky and intermittent diarrhoea with non-bloody stool, abdominal pain and loss of weight (Kotler DP, 1995). In developing countries children are affected by cryptosporidiosis with or without HIV infection (SitaraSwarna RA et al., 2008). Our study was therefore aimed to determine the prevalence of cryptosporidiosis in HIV and non- HIV infected patients in Hyderabad in order to create awareness among the community and highlight the importance of oocysts detection in routine stool examination.

Materials and Methods

A retrospective study was conducted at Malla Reddy Hospital, Hyderabad over a period of 1 and 1/2 year from March 2014 to September 2015. 57 faecal samples from

HIV reactive patients with symptoms of diarrhoea and 754 stool samples from HIV non-reactive patients with diarrhoea were included in this study. Patients were provided with a clean, wide mouthed dry plastic container for collection of stool samples with instructions to transfer them immediately to the microbiology laboratory. All the stool samples were processed for wet mount and smear examination. The smears were stained by modified Ziehl-Neelsen and Giemsa stains (Ortolani EL, 2000; Karyakarte R et al., 2005; MacPherson DW et al., 1993). The stained preparations were examined under oil immersion lens to detect the oocysts of *Cryptosporidium parvum*.

Results and Discussion

Out of a total of 811-stool samples which were examined, 754 samples were from HIV non-reactive patients and the remaining 57 were from HIV reactive patients (Table2). 567 (75.2%) were male and 244 (32.4%) female patients were included in this study (Table1). Among the 57 HIV reactive patients 38 (66.7%) were male patients and 19 (33.3%) female patients (Table1). 22 (38.6%) stool samples were positive for oocysts of *cryptosporidium parvum* in HIV infected patients. In HIV non infected patients 19 (2.5%) out of 754 samples were positive for oocyst of *Cryptosporidium parvum* (Table2). In all 41 (100%) samples showed the presence of cryptosporidium oocysts by the modified Ziehl-Neelsen method and 39 (95.1%) by Giemsa staining (Table3). Figure 1 shows the oocysts of *Cryptosporidium parvum* by modified Ziehl-Neelsen staining method.

Rather than the bacteria, the most common and major causes of death and morbidity in HIV reactive individuals are the intestinal protozoan parasites (Janoff EN et al., 1988). In immunocompetent and healthy

individuals the disease produced by these organisms is very mild and self-limiting but the case is not so bright in immunocompromised individuals. These patients suffer from profuse watery diarrhoea, which can even be life threatening at times (Kotler DP, 1995).

This study assesses the prevalence of intestinal protozoan parasitic infections in HIV infected and non-infected individuals. A number of human cases have been documented in individuals who maintained close contact with bovine animals such as cow and buffalos, which points to the fact that cryptosporidiosis is a zoonotic disease (Narayan Shrihari et al., 2011). *Cryptosporidium* has gained importance as

causative agent of diarrhoea in AIDS patient. Other than the gastrointestinal symptoms *Cryptosporidium* can also cause respiratory tract infection, cholecystitis and even hepatitis (K.D. Chatterjee, CBS Publishers and Distributors Pvt.Ltd. New Delh). Prevalence of cryptosporidiosis ranges from 3% in the developed countries to as high as even 50% in the developing countries (Goldstein ST et al., 1996). According to the study done by Ayyagari et al (1999) the prevalence of *Isospora belli* was reported to be high in North India. However Kumar SS et al (2002) reported that the commonest parasite in HIV seropositive individuals was *Cryptosporidium parvum* in South India.

Table.1 Sex Wise Distribution of HIV Reactive and Non-Reactive Patients with Diarrhoea

Sex	HIV-infected patients with diarrhoea	HIV-non infected patients with diarrhoea
Male	38 (66.7%)	567 (75.2%)
Female	19 (33.3%)	244 (32.4%)

Table.2 *Cryptosporidium parvum* Oocysts Positive in HIV and Non-HIV Patients

Patients status	Total cases	Positive for oocysts
HIV-reactive patients	57	22 (38.6%)
HIV non-reactive patients	754	19 (2.5%)

Table.3 Test Procedures to Detect Oocysts in Faecal Samples

Assay procedure	No. of Stool	
	Negative	Positive
Modified Ziehl-Neelsen Staining	0	41 (100%)
Giemsa Staining	2	39 (95.1%)

Fig.1 Oocysts of *Cryptosporidium parvum*

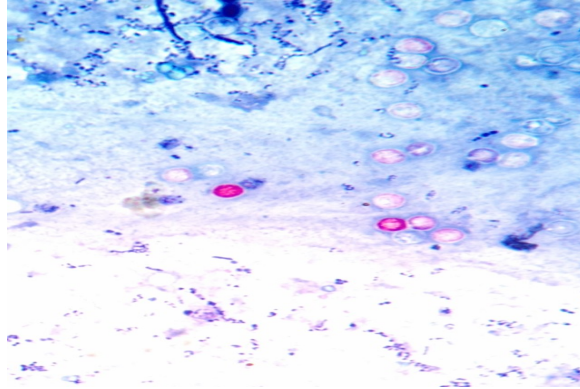


Figure.1 Shows the oocysts of *Cryptosporidium parvum* by Modified Ziehl-Neelsen Staining Method

According to our study *Cryptosporidium parvum* (38.6%) was found to be the most common parasitic cause of diarrhoea in HIV positive cases. Similar results was seen in studies carried out by Basak et al (2010); Sadraei et al (2005); Tuli et al (2008) and Mohandas et al (2002). However the prevalence of *Cryptosporidium parvum* was found to be lower when compare to that of *Isospora belli* as reported by Mukhopadhyaya et al (1999); Gupta et al (2008).

The study conducted by Nwokediuko et al (2002) in South-eastern Nigeria found no *Cryptosporidium* in stool samples of HIV-infected and non-infected patients with diarrhoea. Yemisi et al (2007) reported 52.7% cryptosporidiosis in HIV infected patients with diarrhoea.

In our study cryptosporidiosis was found to be in 2.5% of HIV non-infected individuals. Yu et al (2004), 10.6% and 1% by Chai et al (1996) and Jong-Kyu LEE et al (2005) reported 8.2% cryptosporidiosis in HIV non-infected individuals respectively. Worldwide cryptosporidiosis was present in 6.1% of diarrhoeal patients in developing countries but only 2.1% in developed countries (Adal KA, Raven Press, New York). Based on our

findings we can say that cryptosporidiosis occurs less frequently in India as compared to the other developing countries. The modified Ziehl-Neelsen staining technique was preferred because of the poor colour contrast provided by the Giemsa technique as shown by other authors also.

The main cause of cryptosporidiosis in rural areas is due to contaminated water supply and lack of personal hygiene. The best prophylactic measure would be to improve general sanitation, water supply and to educate HIV infected individuals about the disease.

In conclusion, Cryptosporidiosis is an important waterborne illness, prevention of its transmission by water is necessary to protect public health. Faecal smears can be stained with the modified Zeihl-Neelsen technique and negative smears can be confirmed by the Sheather sugar floatation technique, ELISA and Molecular methods. Our study highlights the importance of evaluation of HIV infected as well as non-HIV patients with diarrhea for intestinal protozoal infections which may help in better management and to improve the quality of life of such patients.

References

- Adal KA, Sterling CR, Guerrant RL. Cryptosporidium and related species. In infections of the Gastrointestinal Tract, Blaser MJ, Smith PD, Ravdin JI, Greenberg HB, Guerrant RL (eds.), p1107-1128, Raven Press, New York.
- Aruna Aggarwal, Usha Arora, Renuka Bajaj, Kavita Kumari. Clinico-microbiological Study in HIV Seropositive Patients. *JACM*; 2005; 6(2): 142-5.
- Ayyagari A, Sharma AK, Prasad KN et al. Spectrum of opportunistic infections in Human Immunodeficiency Virus (HIV) infected cases in a tertiary care hospital. *Indian J Med Microbiol* 1999; 17: 78-80.
- Basak S, Bose S, Mallick SK, Ghosh AK. Intestinal parasitic infections in HIV seropositive patients- A study. *Journal of Clinical and Diagnostic Research*; 2010; 4: 2433-37.
- Celine Ngufeu Nkenfou, Christelle Tafou Nana, Vincent Khan Payne. Intestinal Parasitic Infections in HIV Infected and Non-Infected Patients in a Low HIV Prevalence Region, West-Cameroon. *PLOS ONE*; 2013; 8(2).
- Chai JY, Lee SH, Guk SM, Lee SH. An epidemiological survey of Cryptosporidium parvum infection in randomly selected inhabitants of Seoul and Jeollanam-do. *Korean J Parasitol*; 1996; 34: 113-119.
- Ekejindu IM, Ele PU, Okonkwo SO, Ezenwagu OC, Ezeagwuna DA. Intestinal parasitic infection among HIV-seropositive and HIV-seronegative individuals at Nnewi, South Eastern Nigeria. *World Journal of Medical Sciences*; 2010; 5: 7173.
- Framm SR, Soave R. Agents of diarrhea. *Med Clin North Am* 1997; 81: 427-47.
- Goldstein ST, Juranek DD, Ravenholt O. Cryptosporidiosis: an outbreak associated with drinking water despite state-of-the art water treatment. 1996; *Ann. Intern. Med.* 116: 840-842.
- Gupta S, Narang S, Nunavath V, Singh S. Chronic diarrhoea in HIV patients: Prevalence of coccidian parasites. *Indian J Med Microbiol*; 2008; 26(2): 172-175.
- Hammouda NA, Sadaka HA, EI-Gebaly WM, EI-Nassery SM. Opportunistic intestinal protozoa in chronic diarrheic immunosuppressed patients. *J Egypt Soc Parasitol* 1996; 26: 143-53.
- Janoff EN, Smith PD. Prospectives on gastrointestinal infections in AIDS. *Gastroenterol Clin North Am* 1988; 17: 451-63.
- Jong-Kyu LEE, Hyeon-Je SONG and Jae-Ran YU. Prevalence of diarrhea caused by Cryptosporidium parvum in non-HIV patients in Jeollanam-do, Korea. *Korean Journal of Parasitology*; 2005; 43: 111-114.
- K.D. Chatterjee. *Parasitology*; 13th edition. p134-135; CBS Publishers and Distributors Pvt.Ltd. New Delhi.
- Karyakarte R, Damle A, Medical Parasitology, In: Other members of Phylum Apicomplexa, Chapter 6, Arunbhasen Book and Allied(P) Ltd, Kolkata; 2005:91.
- Kotler DP. Gastrointestinal manifestations of human immunodeficiency virus infection. *Adv. Intern, Med.* 1995; 40: 197-242.
- Kumar SS, Ananthan S, Lakshmi P. Intestinal parasitic infections in HIV infected patients with diarrhoea in Chennai. *Indian J Med Microbiol*, 2002; 20(2): 88-89.
- MacPherson DW, McQueen R, Cryptosporidiosis: Multiattribute evaluation of six diagnostic methods, *Journal of Clinical Microbiology*, 1993; 31(2): 198-202.

- Mitra AK, Hernandez CD, Hernandez CA, Siddiq Z. Management of diarrhea in HIV infected patients. *Int J STD AIDS* 2001; 12: 630-9.
- Mohandas K, Sehgal R, Sud A, Malla N. Prevalence of intestinal parasitic pathogens in HIV seropositive individuals in Northern India. *Jpn J infect Dis*; 2002; 55: 83-84.
- Mukhopadhyaya A, Ramakrishna BS, Kang G, Pulimood AB, Mathan MM, Zachariah A, Mathai DC. Enteric pathogens in Southern India HIV infected patients with and without diarrhoea. *Indian J Med Res*; 1999; 109: 85-89.
- NACO. Epidemiology of HIV/AIDS. HIV/AIDS Surveillance in India. Spectrum of opportunistic infection in AIDS in India. In: Specialists Training and Reference Module. National AIDS Control Organisation, New Delhi 1999; 1-11, 12-17, 111-120.
- Narayan Shrihari, Kumudini T.S, Mariraj. J, Krishna. S. The prevalence of Cryptosporidiosis in HIV seropositive individuals and detection of *Cryptosporidium parvum* oocysts by Modified Ziehl-Neelsen staining, Giemsa staining and Sheather sugar flotation technique in a tertiary care hospital. *Journal of Pharmaceutical and Biomedical Sciences*; 2011; 12(09).
- Nwokediuko SC, Bojuwoye BJ, Onyenekwe B. Apparent rarity of Cryptosporidiosis in human immunodeficiency virus (HIV)-related diarrhoea in Enugu, South-Eastern Nigeria. *Niger. Postgrad. Med. J.* 2002; 9:70-73.
- Ortolani EL. Standardization of the modified Ziehl-Neelsen technique to stain oocysts of *Cryptosporidium* species, *Rev Brazil Journal Vet Parasitol*, 2000; 9(1): 29-31.
- Sadraei J, Rizvi MA, Baveja UK. Diarrhoea, CD4 cell counts and opportunistic protozoa in India HIV infected patients. *Parasitol Res*, 2005; 97: 270-73.
- SitaraSwarna RA, PremiSankaran, Gagandeep Kang, *Cryptosporidium* species in HIV infected individuals in India: An overview, *The National Medical Journal of India*, 2008; 21 (4): 178-84.
- Tuli L, Gulati AK, Sundar S, Mohapatra TM. Correlation between CD4 counts of HIV patients and enteric protozoan in different seasons- An experience of a tertiary care Hospital in Varanasi. *BMCV, Gastroenterology*, 2008; 8:36.
- Yemisi OA, Rofiat OL, Samuel ST, Sunday AF, Oluwaseyi AA. Cryptosporidiosis in HIV infected patients with diarrhoea in Osun State Southwestern Nigeria. *Eur. J. Gen. M*; 2007; 4(3): 119-122.
- Yu JR, Lee JK, Seo M, Kim SI, Sohn WM, Huh S, Choi, HY, Kim TS. Prevalence of cryptosporidiosis among the villagers and domestic animals in several rural areas of Korea. *Korean J Parasitol*; 2004; 42: 1-6.