

Case Study

Left Atrial Myxoma Presenting with Orthostatic Hypotension in a 30 Year Young Female: A Case Report and Review

Sandeep Kumar*, Swati Singh and Adil Ahmad

Senior Resident Cardiology, J.N.Medical College, AMU, Aligarh, India

*Corresponding author

ABSTRACT

Keywords

Atrial Myxoma, Orthostatic Hypotension, atrial tumors

Cardiac tumors are divided into primary and secondary tumors. Primary cardiac tumors are very rare, with an autopsy incidence of 0.001% to 0.03%¹. Most (>80%) primary cardiac tumors are benign, and myxoma is by far the most common^{1,2}. Myxoma constitutes about 50% of all benign cardiac tumors in adults. Most myxomas (>80%) are found in the left atrium. We report a rare case of a massive left atrial myxoma causing mitral valve obstruction and presenting as positional dizziness. Though cardiac myxomas are known to present with various non-specific clinical symptoms¹, orthostatic hypotension is not listed as a presenting symptom of atrial tumors in most textbooks of internal medicine or cardiology¹. So this case is rare in this sense.

Introduction

Cardiac tumors are divided into primary and secondary tumors. Primary cardiac tumors are very rare, with an autopsy incidence of 0.001% to 0.03%¹, accounting for <5% of all cardiac tumors. Secondary, or metastatic cardiac tumors are 30 times more common than primary neoplasms with an autopsy incidence of 1.7% to 14%³.

Most myxomas (>80%) are found in the left atrium and in decreasing frequencies in the right atrium, right ventricle, and left ventricle. The incidence of cardiac myxoma peaks at 40 to 60 years of age, with a female-to-male ratio of approximately 3:1. These cardiac growths can masquerade as mitral stenosis, infective endocarditis and collagen

vascular disease. Atrial myxomas are found in approximately 14-20% of the population and can lead to embolization, intercardiac obstructions, conduction disturbances and lethal valve obstructions.

We present the case of a 30 year-old female with a large atrial myxoma, who presented with complaints of positional dizziness and who was found to have a grade 3/6 systolic murmur, and significant orthostatic hypotension.

Clinical Manifestations

Commonly observed symptoms and signs are dyspnea, orthopnea, paroxysmal

nocturnal dyspnea, pulmonary edema, cough, hemoptysis, edema, and fatigue. Symptoms may be worsened in certain body positions, due to motion of the tumor within the atrium. On physical examination, a characteristic “tumor plop” may be heard early in diastole^{4,5}. Constitutional symptoms (e.g., fever, weight loss) are seen in around 30 percent of patients.

Laboratory abnormalities (e.g., anemia and elevations in the erythrocyte sedimentation rate, C-reactive protein, or globulin level) are present in 35% usually those with systemic symptoms⁵.

There are several mechanisms by which cardiac tumors may cause symptoms. The obstruction of circulation through the heart or heart valves produce symptoms of heart failure. Atrial myxoma may interfere with heart valves causing regurgitation. The direct invasion of the myocardium may result in impaired contractility, arrhythmias, heart block, or pericardial effusion with or without tamponade. The invasion of the adjacent lung may cause pulmonary symptoms and may mimic bronchogenic carcinoma. Finally, left atrial tumors may release tumor fragments or thrombi into the systemic circulation, leading to embolization which is usually systemic but can be pulmonary. The most serious complications of such embolization are neurologic. The rate of growth is unknown, as myxomas are mostly managed with surgical resection and only very rarely are medically managed due to contraindications to surgery^{6,7}.

Case Report

A 30-year-old female presented with complaint of dizziness upon standing, which was relieved by lying down. Vital signs were blood pressure of 134/80 mmHg in supine position, with drop in the blood

pressure from 134/80 mmHg to 100/74 mmHg within 3 minutes after standing, with compensatory increase in pulse rate; respiratory rate of 16 breaths per minute and temperature of 36.5 °C.

On physical exam, patient was conscious and oriented with time, place and person with no focal neurological deficit. JVP was normal with normal wave pattern. Lungs were clear to auscultation bilaterally with no wheezing. Cardiovascular examination was notable for a grade 3/6, holosystolic murmur at the left lower parasternal area with no diastolic murmur present. There was no evidence of any tumor 'plop'.

The patient had no prior history of heart murmurs, syncope, shortness of breath, or chest pain. Abdomen was soft, non-tender, non-distended with normal bowel sounds in all four quadrants. Pulses were intact bilaterally in upper and lower extremities with no edema.

Laboratory findings were as follows: WBC 4500/ul, Hb 9 g/dl, Hct 30.2 %, Platelets 2 lakh /ul. Electrolyte panel findings were as follows: Na 130 mmol/L, K 4.1 mmol/L, BUN 11 mg/dl, S.Cr 0.8 mg/dl, random blood glucose: 96 mg/dl. ECG showed normal sinus rhythm.

Transthoracic Echocardiogram (TTE) was performed which showed a large atrial myxoma of size 30x34 mm attached to interatrial septum at Fossa Ovalis with small stalk, occupying the majority of the left atrium and prolapsing into left ventricle during diastole through mitral valve [figure - 1 and figure 2] with mitral regurgitation [figure 3], mitral valve diastolic velocity was increased i.e. 2.4 m/s, with normal EF-60%. A diagnosis of left atrial myxoma was made and the case was referred to another hospital for surgical intervention.

Results and Discussion

Our patient had not presented with the common symptoms associated with atrial myxoma including chest pain, dyspnea, orthopnea, peripheral embolism or syncope. Though cardiac myxomas are known to present with various non-specific clinical symptoms⁸, orthostatic hypotension is not listed as a presenting symptom of atrial tumors in most textbooks of internal medicine or cardiology¹. An extensive search of literature revealed only few cases that reported orthostasis as a presenting symptom of a left atrial myxoma⁹.

Common causes of orthostasis includes neurogenic dysfunction, autonomic failure, antihypertensive medications and intravascular volume depletion¹⁰ but atrial myxoma may be kept in differential diagnosis of orthostasis specially in young populations in which more common causes of orthostatic hypotension like autonomic dysfunction, antihypertensive medications are less prevalent. Patient was followed after surgery and now she is asymptomatic.

Diagnostic Workup

The primary goals of the initial evaluation should be to ascertain whether or not a cardiac tumor is present. If present then the location of the lesion within the heart, movement of tumor during cardiac cycle, valve morphology, any systolic or diastolic gradient across valves and, to the extent possible whether a tumor is benign or malignant.

This information is vital in planning further evaluation and management. Chest X-ray, Echocardiography, cardiac MRI, and ultrafast CT along with excisional biopsy of tumor should be done to address all these questions.

Echocardiography

Echocardiography is main initial imaging modality due to its wide availability, low cost and noninvasive nature. It provides good quality images of both the myocardium and the cardiac chambers. It can usually identify the presence of a mass and its location within the chambers.

In addition, echocardiography may provide information about any obstruction to the circulation, as well as the likelihood that the tumor could be a source of emboli¹¹. Although Transesophageal Echocardiography (TEE) is Superior than TTE due to the proximity of the esophagus to the heart, the lack of intervening lung and bone, and the ability to use high-frequency imaging transducers, it is not available at all the centres.

Cardiac MRI and Computed Tomography

Although both cardiac MRI and ultrafast CT provide noninvasive, high resolution images of the heart, MRI generally is preferred. In addition to furnishing detailed anatomic images, the T1- and T2-weighted sequences reflect the chemical microenvironment within a tumor, thereby offering clues as to the type of tumor that is present. However, CT scanning is still useful when MRI is not immediately available or is contraindicated¹².

PET scan

Positron Emission Tomography (PET) has been useful in identifying cardiac involvement in the patients with metastatic tumors, atrial myxoma or lipomatous septal hypertrophy¹³.

Figure 1 Transthoracic Echocardiogram Demonstrating a Large Atrial Myxoma Prolapsing across the Mitral Valve into the Left Ventricle During Diastole (A), and the Myxoma Filling the Entire Left Atrium in systole (B)

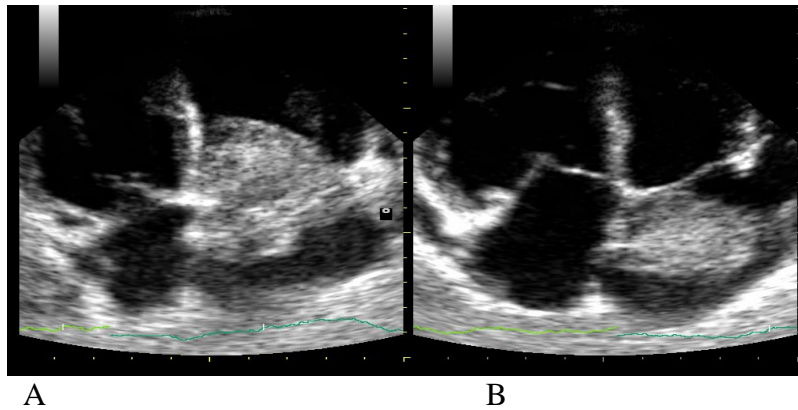


Figure.2 Parasternal Long Axis View of Echocardiogram Showing Left Atrial Myxoma Prolapsing into Left Ventricle Through Mitral Valve During Diastole

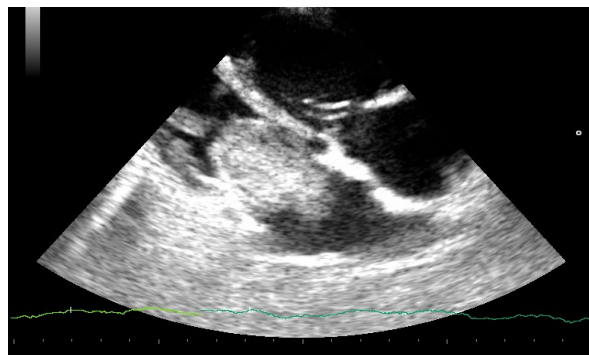
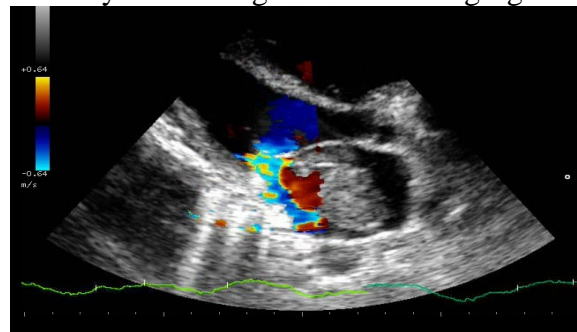


Figure.3 Transthoracic Echocardiogram Parasternal Long Axis View Demonstrating a Large Atrial Myxoma along with Mitral Regurgitation



Treatment and Prognosis

The only definitive treatment of cardiac myxoma is surgical removal. Generally, after median sternotomy, the myxoma is excised surgically with the patient under

cardiopulmonary bypass and cardioplegic arrest. The tumor is removed by either right or left atriotomy or combine atriotomy, depending on the site and extent of the tumor. The choice of technique also depends on associated conditions that needsurgical

intervention, such as valve repair or replacement and coronary disease if present. Life-long follow-up is needed because myxomas have some tendency to recur. Recurrence rates vary but range from 5% to 14%. The time to recurrence in different series has varied from 0.5 to 6.5 years¹⁴.

Reference

1. Benign Primary Cardiac Tumors
McManus B: Primary tumors of the heart. In Bonow RO, Mann DL, Zipes DP, Libby P (eds): Braunwald's Heart Disease. 9th ed. Philadelphia, Elsevier Saunders, 2011, pp 1638–1650.
2. Burke A, Virmani R: Pediatric heart tumors. *Cardiovasc Pathol* 17:193, 2008.
3. Al-Mamgani A, Baartman L, Baaijens M, et al: Cardiac metastases. *Int J Clin Oncol* 13:369,2008.
4. Kolluru A, Desai D, Cohen GI. The etiology of atrial myxoma tumor plop. *J Am Coll Cardiol.* 2011;57(21):e371.
5. Aggarwal SK, Barik R, Sarma TC, Iyer VR, Sai V, Mishra J, Voleti CD. Clinical presentation and investigation findings in cardiac myxomas: new insights from the developing world. *Am Heart J.* 2007;154(6):1102-1107
6. Pinede L, Duhaut P, Loire R. Clinical presentation of left atrial cardiac myxoma. A series of 112 consecutive cases. *Medicine (Baltimore).* 2001;80(3):159-172.
7. Burke AP, Gomez-Roman JJ, Loire R, et al. World Health Organization: Tumours of the lung, pleura, thymus and heart. IARC Press 2004.
8. Jelic J, Milici D, Alfirevi I, Ani D, Baudoin Z, Bulat C, Coric V, Dadic D, Husar J, Ivancan V, Korda Z, Letica D, Predrijevac M, Ugljen R, Vucemilo I: Cardiac myxoma: diagnostic approach, surgical treatment and follow-up. *J Cardiovasc Surg* 1996, 37(6):113-117.
9. Takemura G, Kotoura H, Nishioka A, Kobayashi T, Uegaito T, Miura A, Inagaki M, Wada T, Watanabe R: A case of cardiac tumor found during examination in orthostatic hypotension. *Koykyu To Junkan* 1990, 38(3):257-259.
10. Low P: Prevalence of orthostatic hypotension. *Clin Auton Res* 2008, 18:8-13.
11. Yoo M, Graybeal DF. An echocardiographic-confirmed case of atrial myxoma causing cerebral embolic ischemic stroke: a case report. *Cases J.* 2008;1(1):96.
12. Rahmanian PB, Castillo JG, Sanz J, Adams DH, Filsoufi F. Cardiac myxoma: preoperative diagnosis using a multimodal imaging approach and surgical outcome in a large contemporary series. *Interact Cardiovasc Thorac Surg.* 2007;6(4):479-483.
13. Johnson TR, Becker CR, Wintersperger BJ, Herzog P, Lenhard MS, Reiser MF. Images in cardiovascular medicine. Detection of cardiac metastasis by positron emission tomography-computed tomography. *Circulation.* 2005;112(4):e61-62.
14. Pinede L, Duhaut P, Loire R: Clinical presentation of left atrial cardiac myxoma. A series of 112 consecutive cases. *Medicine (Baltimore)* 80:159, 2001.