



Case Study

A Rare Case of Autoimmuno Polyglandular Syndrome Type I in two Siblings: First Case from Eastern India

Nupur Pal^{1*}, Hirak Jyoti Raj¹, Anasua Das² and Prasanta K Maiti¹

¹Department of Microbiology, Institute of Post-Graduate Medical Education & Research, 244 AJC Bose Road. Kolkata-700020, India

²Consultant Pediatrician, ILS hospital, Kolkata, West Bengal, India

*Corresponding author

ABSTRACT

Keywords

Autoimmuno Polyglandular Syndrome, Mucocutaneous Candidiasis, Hypoparathyroidism

Autoimmuno Polyglandular Syndrome type I is a very rare autosomal recessive juvenile disorder characterized by the the triad of mucocutaneous candidiasis, hypoparathyroidism, and adrenal insufficiency requiring at least two of these three components for diagnosis. Here two siblings presented with mucocutaneous Candidiasis and ectodermal dystrophy whereas elder sister developed hypoparathyroidism at this stage, fulfilling the diagnostic criteria of APS I.

Introduction

The Autoimmuno Polyglandular Syndromes consist of a broad spectrum of autoimmune disorders and are divided into a very rare juvenile (APS type I) and a relatively common adult type with (APSII) or without adrenal failure (APSIII). Type I polyglandular autoimmune syndrome is a very uncommon disease with a frequency of < 1/100 000 and female, male ratio is 0.8:1 to 2.4:1.¹ APS I, also known as autoimmune polyendocrinopathy, candidiasis and ectodermal dystrophy (APECED), usually manifests in infancy or childhood at age 3–5 or in early adolescence and characterised by the triad of mucocutaneous candidiasis, hypoparathyroidism, and adrenal

insufficiency². In most cases, mucocutaneous candidiasis precedes the other immune disorders, usually followed by hypoparathyroidism.

Case Report

A nine year old girl attended to emergency department with carpopedal spasm and admitted to pediatrics ward for investigation and management. There are history of intermittent fever and recurrent respiratory tract infection since infancy. Patient had history of oral ulceration for last five years and deformed and destroyed nails of all hands and toes fingers for five years

(figure1). She had born at term by LUCS. Birth weight was 3.4kg. Her developmental milestones were within normal limits. The child had been exclusively breast fed since birth. Her immunization history was upto date. In family there is only younger brother who is now four year and four months old and presents with same features like oral thrush and nail damage for last three years. (figure2). There is no known history of consanguinity between parents. Examination revealed mild pallor with extensive oral thrush. Her temperature was 35.5°C. She was stable in respect to cardiovascular parameters with a pulse rate of 90bpm and blood pressure 98/58mmHg. Cardiovascular and respiratory examination was normal and her abdomen was soft with mild hepatomegaly but no splenomegaly. After initial assessment the impression was that due to hypoparathyroidism she was developing carpopedal spasm and an autoimmune polyendocrine syndrome should be considered. Initial serum calcium was 5.3 mg/dl. Other baseline investigations, Chest X ray and Ultrasonography abdomen were within normal limit. A calcium gluconate infusion and intravenous fluids were commenced. Blood was sent further for Ca^{++} , PO_4^{-3} , Vitamin D and other endocrinal investigations. Investigations revealed that the level of her Ca^{++} , PO_4^{-3} and 25 (OH) Vit D were 6.7 mg/dl, 5 mg/dl and 21.95 IU/dl respectively. Her ionized parathormone was <3 pg/ml (normal range 10-69), TSH 4.93 ug/ml (0.27-4), FT4 1.28 ng/dl (0.8-1.90) and Cortisol 6.96 ug/dl (5-25) as disclosed by biochemical investigations.

Microbiological investigation from oral lesions and nails revealed the growth of *Candida tropicalis* confirmed by morphological and biochemical tests from both siblings. Direct oral and nail scrapings from both siblings revealed budding yeasts

(fig3a), which grown on Sabouraud Dextrose Agar (SDA) as typical creamy colonies. The yeast isolates were identified with Hichrome differentiations agar (figure3b) and API 32C yeast identification kit (BioMerieux). Blastoconidia in small groups along with pseudohyphae developed on corn meal agar (fig3c).

The patient's carpopedal spasms were well controlled on supplemental calcium. Patient was discharged home with calcium, Vitamin D supplement and cotrimazole ointment for oral thrush and tab fluconazole for candidal onychomycosis for both siblings. She is under regular outpatient follow up.

Results and Discussion

Autoimmune polyendocrinopathy candidiasis ectodermal dystrophy (APECED) is a rare autosomal recessive disease caused by mutations of a single gene named autoimmune regulator gene (*AIRE*), which results in a failure of T cell tolerance within the thymus². Although APECED is rare, it is relatively more frequent in some populations 1: 9000 in the Iranian Jews³ 1:25000 in Finns⁴. Immunologically, the disorder is characterized by lymphocytic infiltrate of target organs and appearance of serum autoantibodies against several defined tissue-restricted antigens, predicting or correlating with functional failure^{5,6}. The clinical diagnosis of APS I requires the presence of at least two of the three major components⁷. New diagnostic criteria for the diagnosis of APECED as reported by Husebye et al suggested that one of the following three criteria is necessary for a definitive diagnosis⁷:

i. presence of at least two of the three major components: chronic mucocutaneous candidiasis, hypoparathyroidism, or adrenal Insufficiency.

ii. only one major component if a sibling is affected by APECED.

iii. disease-causing mutations in both *AIRE* genes.

Mucocutaneous Candidiasis has been reported as the first sign to appear in most (70-80%), it is often followed by hypoparathyroidism (80-85%), before the age of 10 yrs, and later by adrenal insufficiency (60-70%)¹. The diagnosis of our case was made on the basis of mucocutaneous Candidiasis and hypoparathyroidism, as mentioned in the literature, along with nail dystrophy. The girl child was screened for other

autoimmune diseases, but none was detected at this stage. Her younger sibling is also suffering from oral Candidiasis with nail dystrophy. Nail dystrophy in both siblings may be due to candidal onychomycosis or it is inclusive within ectodermal dystrophy. The reason for marked susceptibility to mucocutaneous candidiasis without systemic involvement is still poorly understood although autoantibodies to cytokines seem to be implicated in the pathogenesis². Recently, a role of specific neutralizing autoantibodies against the Th17-related cytokines IL-22 and IL-17F, and the concomitant loss of Th17 and Th22 cells, has been hypothesized in the pathogenesis of the CMC^{2,8}.

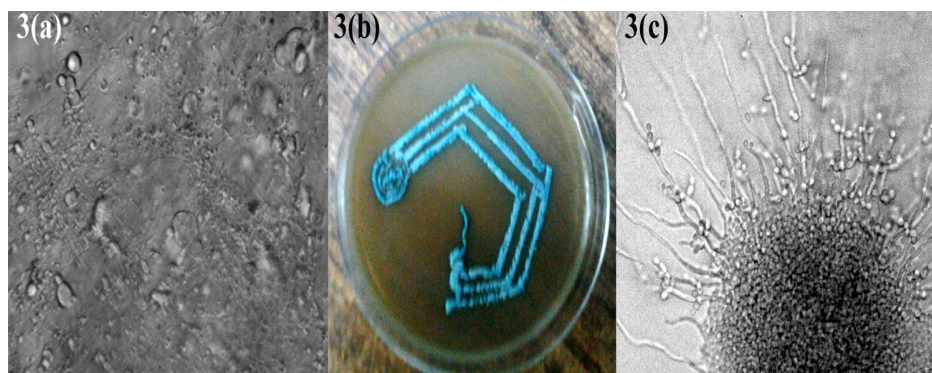
Figure.1 Boy Sibling Showing Oral Thrush and Nail Dystrophy

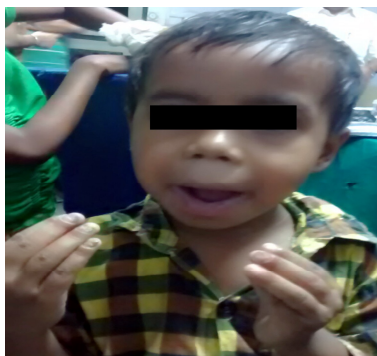

Figure.2 Girl Sibling Showing Oral Thrush and Nail Dystrophy

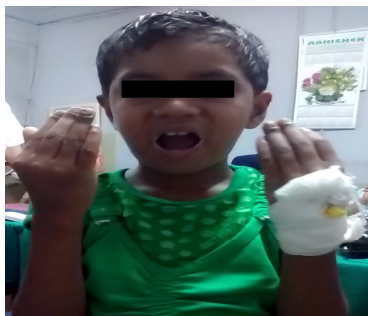

Figure.3a Microscopic View of Direct KOH Preparation Showing Budding Yeast; **3b**.Dark Blue Coloured Colonies of *Candida Tropicalis* on HiChrome Differentiation Agar; **3c**.Blastoconidia in Small Groups along with Pseudohyphae Developed on Corn Meal Agar



Survival is usually limited. The overall mortality of patients with APS I vary widely on the basis of the clinical spectrum. The most serious autoimmune manifestations are fulminant necrotizing hepatitis, severe malabsorption, and tubulointerstitial nephritis. Suboptimal hormonal substitution or inadequate management of Addisonian crisis may also increase the mortality risk. Furthermore, patients with long-lasting oral candidiasis are at increased risk of esophageal squamous cell carcinoma. In the Finnish series, 10.5% of patients over 25 years of age developed squamous cell carcinoma of the oral cavity or of the esophagus⁹. Betterle *et al* in their study of 41 cases, over around 30 years, found death occurring in 10% of cases, and cumulative survival around 75% by 48 years^{10, 11}. Disease targeted therapy is not currently available and the treatment mainly relies on hormone replacement and caring for clinical symptoms.

In conclusion; all patients with an autoimmune disease should be considered at risk for the other autoimmune diseases. Early detection of the disease may reduce morbidity and mortality significantly in the patients with autoimmune polyglandular syndrome.

Reference

1. Kahaly GJ. Polyglandular autoimmune syndromes. *Eur J Endocrinol.* 2009; 161:11-20.
2. Capalbo D, De Martino L, Giardino G, Di Mase R, Di Donato I, Parenti G, *et al.*, Autoimmune polyendocrinopathy candidiasis ectodermal dystrophy: insights into genotype-phenotype correlation. *Int J Endocrinol.* (2012) 2012:353250. 10.1155/2012/353250
3. Ahonen P, Myllarniemi S, Sipila I and Perheentupa J. Clinical variation of autoimmune polyendocrinopathy-candidiasis-ectodermal dystrophy (APECED) in a series of 68 patients. *N Engl J Med.* 1990; 322(26):1829–36.
4. Zlotogora J and Shapiro MS. Polyglandular autoimmune syndrome type I among Iranian Jews. *J Med Genet.* 1992; 29(11): 824–6.
5. Husebye ES, Gebre-Medhin G, Tuomi T *et al.*, Autoantibodies against aromatic L-amino acid decarboxylase in autoimmune polyendocrine syndrome type I. *J Clin Endocrinol and Metab.* 1997; 82 (1): 147–50.
6. Oderbergh AS, Myhre AG, Ekwall O *et al.*, Prevalence and clinical associations of 10 defined

- autoantibodies in autoimmune polyendocrine syndrome type I. *J Clin Endocrinol and Metab.* 2004; 89 (2): 557–62.
7. Husebye ES, Perheentupa J, Rautemaa R, and Ampe OK. Clinical manifestations and management of patients with autoimmune polyendocrine syndrome type I. *J Intern Med.* 2009; 265(5): 514–29.
 8. Martinez GJ, Nurieva RI, Yang XO and Dong C. Regulation and function of proinflammatory TH17 cells. *Annals of the New York Academy of Sciences.* 2008; 1143: 188–211.
 9. Perheentupa J, Autoimmune polyendocrinopathy-candidiasis-ectodermal dystrophy. *J Clin Endocrinol and Metab.* 2006; 91(8): 2843–50.
 10. Betterle C, Greggio NA, Volpato M. Autoimmune Polyglandular Syndrome Type – I. *J Clin Endocrinol and Metab.* 1998; 83: 1049-55.
 11. Khan GQ, Hassan G, Kadls S. *et al.*, Polyglandular Autoimmune Syndrome Type-I. Report of First Case from India. *J Assoc Physicians India.* 2001; 49: 140-1.