

## Case Report

# Otogenic Tetanus – a Case Report, Pointing out Importance of Microbiological Diagnosis and immunization as Preventive Measure

Ingole Kishor, Mundhada Sapana\*, Jadhav Ashwini and Bawane Rashmi

Department of Microbiology, Dr.V.M. Government Medical College in front of District court, Solapur 413003, Maharashtra, India

\*Corresponding author

## ABSTRACT

### Keywords

Otogenic Tetanus, Tetanus toxoid, *Clostridium tetani*

This is a case report of otogenic tetanus in a 6 year female with history of incomplete immunization, who presented with history of fever, trismus, difficulty in swallowing and breathing, non-foul smelling discharge from left ear, neck stiffness and single episode of convulsion. Gram staining and Culture of ear discharge sample diagnosed it to be *Clostridium tetani* infection. Patient was successfully treated with Antitetanus serum and Tetanus toxoid along with supportive management. After 5 weeks patient was discharged.

## Introduction

Tetanus is the clinical manifestation of infection with *Clostridium tetani*. The exotoxintetanospasmin produced by tetanus bacilli acts on the spinal cord and causes painful muscular contractions, especially of the neck and masseter muscles, thus the colloquial name "lockjaw". More severe symptoms include respiratory problems, coma and death. Tetanus spores are ubiquitous in the environment and can infect any exposed wound.<sup>1</sup>The natural course of the disease typically begins with a wound contaminated by soil, manure, or rusted metal. Puncture injuries are the most common method of entry, but tetanus has been reported after fractures, burns, animal scratches, otitis media, contaminated

surgical wounds involving the gastrointestinal tract or abortions, as well as umbilical cord contamination.<sup>2,3</sup> Prevention of tetanus is achieved through appropriate wound care and immunization.

## Case Report

A 6-year-old girl child, was admitted to hospital with a three-day history of fever and pain along the left side of the lower jaw and difficulty in opening mouth. Since then she developed difficulty in swallowing and breathing. There was history of discharge from the left ear since 2 days. When asked about history of any penetrating injury,

parents told that while playing girl inserted a hairpin into her left ear 5 days back. Tetanus toxoid (TT) was not given to her after this incidence. There was also history of close contact with pet dog at home. But no history of bite or scratch caused by the pet. Patient had incomplete immunization history, she had completed her immunization till age of 1 year only. She missed her booster doses of trivalent vaccine of diphtheria, pertussis and tetanus (DPT) at age of 16-24 months and 5-6 years of age.

On clinical examination, patient was unable to open her jaw more than 1inch. Reflexes were brisk but symmetrical. Patient was anxious. A slight degree of neck stiffness was noted with single episode of convulsion. Her temperature was 100<sup>0</sup> F. (37.8° C.) and the pulse rate was 130/min. Pus was discharging from the left ear, but there was no tenderness, swelling, or oedema over the mastoid. Based on the patient's history of trauma, incomplete vaccination coverage, absence of any local cause for trismus, a diagnosis of tetanus was entertained as a distinct possibility, with meningitis and rabies being other possible diagnosis.

Swabs from discharging from ear and cerebrospinal fluid after lumbar puncture were send for microbiological processing. A course of intravenous cefotaxime and ciprofloxacin was started. Patient could not maintain an adequate fluid intake, and so intravenous fluid and electrolyte replacement were started. Regular ear toilet was done; still the ear kept discharging a small amount of pus. Patient had some difficulty in swallowing and had some spill over into her respiratory tract. She was transferred to intensive care unit. Under anaesthesia, a feeding-tube was introduced and bronchial toilet was carried out. As adequate spontaneous respiration could not be maintained, the patient was shifted on

ventilator. Tracheostomy was carried out and the patient was maintained fully for 2 weeks on the ventilator.

### **Bacteriological Data**<sup>4,5</sup>

Direct gram staining from swab shown Gram positive bacilli, some of them showed round terminal spore. Preliminary diagnosis of *Clostridium tetani* infection was given, so that the treatment could be started immediately. The patient was given antitetanus serum intramuscularly with no side effects and over the next 48 hours the trismus lessened. For confirmation of diagnosis, swabs were inoculated into Robertson's cooked meat broth, which was then incubated at 37<sup>0</sup> C. Films were made from the broth 48 hours later and stained by Gram's method which showed frequent gram positive bacilli. A few were "drumstick" forms with terminal round spores. Proteolytic changes were noted in Robertson's cooked meat broth.

Further processing were carried out on the two inoculated broth cultures. Each was heated upto 60° C for one hour and then inoculated on two blood agar plates. One of them was incubated anaerobically and the other aerobically. No growth was obtained on aerobically kept blood agar plate. While gray, matte surface, irregular margin, translucent, flat growth showing a fine fimbriated swarming was obtained on the anaerobic plate. Gram-stained films from this showed gram positive bacilli, some with "drumstick" appearance. Confirmed diagnosis of clostridium tetani infection was given, based on which intravenous metronidazole was started along with Diazepam.

No pathogenic microorganism was found on gram stain and culture of cerebrospinal fluid.

Weaning from the ventilator was commenced after 2 weeks and the tracheostomy tube was removed seven days after that left external otitis settled quickly. Five days later she was able to start walking and the residual muscle stiffness had disappeared. First booster dose of tetanus toxoid was given to patient before leaving hospital and second booster 1 month later on OPD basis.

## Results and Discussion

Otogenic tetanus is a generalised intermittent neurological disorder with spasticity, muscle spasms and autonomic disturbance caused by the neurotoxin-tetanospasmin elaborated by *Clostridium tetani* from an otogenic source. Strictly speaking, the disease is preventable by immunization.<sup>6</sup>Boyle et al<sup>7</sup> points out that two forms of otogenic tetanus are found. One resulting from trauma like foreign-body trauma. Convulsions resulting in this form of ototetanus are acute, severe, and generalized. Whereas the other form in which tetanus supervenes in pre-existing suppurative ear disease, or perhaps becomes overt from a latent state, the clinical picture is much less severe. The case reported above falls into first category. Incubation period of tetanus in patient was very short due to shorter route between the ear and the central nervous system.

Prompt diagnosis and treatment of tetanus improves the prognosis.<sup>8</sup>A common reason for delayed treatment is the often confusing differential diagnosis but confirmed laboratory diagnosis improves outcome.<sup>2</sup> In present case report, depending on history and clinical presentation of patient, differential diagnosis of tetanus, rabies and meningitis were given. Confirmed diagnosis of tetanus was given based on gram stain and culture report.

According to Onuki T<sup>9</sup>, rapid gram staining report is expected to improve recovery from *Clostridium tetani* infection. In our case report, preliminary diagnosis of *Clostridium tetani* was given from direct gram staining of ear discharge. Based on which antitetanus serum was given to patient which improved outcome of patient along with supportive management. Early treatment with antitetanus serum is critical, because it binds free toxin. However, it does not treat the effects of toxin protected within the neuron or cell body. Treatment of the effects of toxin already within the nervous system is purely supportive.<sup>10</sup>

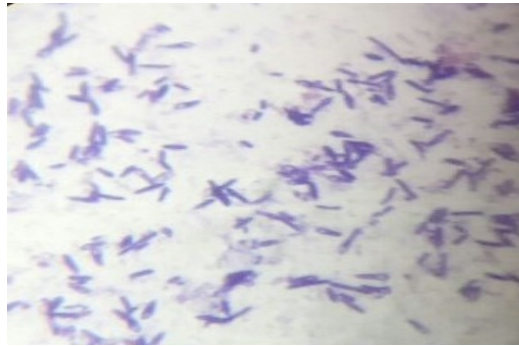
Tetanus is currently responsible for 1.2 million deaths in the developing world. Vaccination is the only way to prevent it as infection by *Clostridium tetani* does not confer immunity. Despite the widespread availability of a safe and effective vaccine against tetanus, it remains a major health problem in developing countries like India, main reason behind it could be the low immunization coverage rate.<sup>11</sup> Previous reports indicate that low immunization coverage rates for children are associated with low socioeconomic status, incomplete or unknown immunization status, urban dwelling, impoverished neighbourhoods, single-parent families, mobile populations and minority cultural status.<sup>12,13</sup> It is a disease associated with a high morbidity and mortality worldwide.<sup>11</sup>

In India, according to National immunization schedule, active immunization against tetanus is done with administration of tetanus toxoid as trivalent vaccine of diphtheria, pertussis and tetanus (DPT) at 6, 10, 14 weeks and boosters at 16-24 months and 5-6 years of age. Afterwards only tetanus toxoid (TT) is given at 10 and 16 years of age.<sup>13</sup> In our case report, patient had missed her two booster doses of tetanus

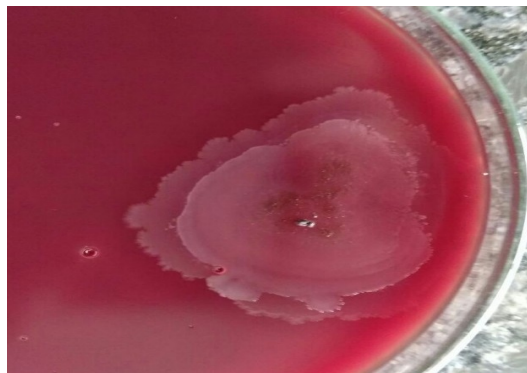
toxoid at the age of 16-24 month and 5-6 year in her routine immunization schedule. Even after penetrating injury in ear she had not received tetanus toxoid and she

developed otogenic tetanus. This signifies importance of tetanus toxoid as preventive measure in case of tetanus.

**Photograph.1** Gram Stain Showing Gram Positive Bacilli, some of them Showed Round Terminal Spore



**Photograph.2** Gray, Matte Surface, Irregular Margin, Translucent, Flat Growth Showing a Fine Fimbriated Swarming on the Anaerobic Blood Agar Plate



**Photograph.3** Proteolytic Changes by Clostridium Tetani in Robertson's Cooked Meat Broth



In conclusion, situation were clinical diagnosis of tetanus is not confirmed, microbiological diagnosis such as gram stain and culture play an important role in diagnosis and improving prognosis of patient. The only way of prevention of tetanus is immunization. In present case report there was history of incomplete immunization due to unawareness of importance of vaccination by parents. So it is important to strengthen existing immunization program coverage for vaccine preventable diseases like tetanus and educating people and health care worker regarding importance of immunization against tetanus.

### Reference

1. Hopkins JP, Riddle C, Hollidge M, Wilson SE. Systemic review of tetanus in individuals with previous tetanus toxoid immunization. *CCDR*.2014: vol 40-17.
2. Bleck TP. Pharmacology of tetanus. *Clinical Neuropharmacol* 1986; 9: 103–20.
3. Roper MH, Vandelaer JH, Gasse FL. Maternal and neonatal tetanus. *Lancet* 2007; 370: 1947–59.
4. Winn WC, Allen SD, Janda WM, Koneman EW, Procop GW, Schreckenberger PC, et al. Anaerobic bacteria. Colour atlas and textbook of diagnostic Microbiology. 6th ed. Philadelphia: Lippincott Williams and Wilkins; 2006. p. 878-939.
5. Murry P, Baron E, Jorgensen J, Pfaller M, Tenover FC, Tenover R. Clostridia. Manual of Microbiology.8th ed.Washington ,D.C.:ASM press ;2003.p.835-856.
6. Akinbohun A, Ijaluola G. Otogenic Tetanus Among Children In Ibadan, Nigeria. *The Internet Journal of Otorhinolaryngology*. 2008;Vol 10 (2).
7. Boyle, I. T., Brown, W. C., & Richardson, E. A. Otogenic tetanus: Report of a case with bacteriological findings. *British medical journal*.1965; vol2-5453: 89.
8. Patel JC, Mehta BC. Tetanus: study of 8,697 cases. *Indian J Med Sci* 1999; 53: 393–401.
9. Onuki T, Nihonyanagi S, Nakamura M, Ide T, Hattori J, Kanoh Y, Soma K. Clostridium tetani isolated from patients with systemic tetanus. *Kansenshoqaku Zasshi*.2013 Jan;87(1):33-8.
10. Mellanby J, Green J. How does tetanus toxin act? *Neuroscience* 1981; 6: 281–300.
11. O. A. Ogunrin. Tetanus- A review of current concepts in management. *Journal of Postgraduate Medicine*. 2009;Vol. 11:46-61.
12. M Lemstra, C Neudorf, J Opondo, et al. Disparity in childhood immunizations. *Paediatr Child Health* 2007;12(10):847-852.
13. Briss PA, Rodewald LE, Hinman AR, et al. Reviews of evidence regarding interventions to improve vaccination coverage in children, adolescents, and adults. The Task Force on Community Preventive Services. *Am J Prev Med* 2000;18:97-140.
14. Gupta R, Mandliya JC, Sabde YD. Tetanus Booster -A missed opportunity. *Ind J Comm Health*. 2014;26 (2); 200-201.