

## Original Research Article

# Onychomycosis Caused by *Rhodotorula glutinis*: A Case Report

Vinod Maurya\*, P. K. Khatri, Saroj Meena, Archana Bora,  
K. L. Seervi, Laxmi Rathore and Shivani Khullar

Department of Microbiology, Dr. S. N. Medical College, Jodhpur, Rajasthan, India

\*Corresponding author

## ABSTRACT

### Keywords

Onycho-  
mycosis,  
*Rhodotorula  
glutinis*,  
Disc diffusion  
method

*Rhodotorula* species is generally not considered pathogenic in immunocompetent individuals, though cases with *Rhodotorula* infections have been reported in immunocompromised patients and patients on central venous catheter. The current study reports a case of onychomycosis in an immunocompetent 63 years old male. The causative agent was identified as *R. glutinis* by pinkish-orange color, mucoid-appearing yeast colonies on Sabouraud Dextrose Agar, oval budding yeast cells with no pseudohyphae on corn-meal agar tween-80, urease test positive and sugar assimilation tests. Positive nitrate assimilation differentiates it from *R. mucilaginosa*. Antifungal susceptibility testing by using CLSI M44 A-2 disc diffusion method showed the isolate is sensitive to voriconazole, ketoconazole, nystatin, and amphotericin-B and resistant for fluconazole, itraconazole, miconazole and clotrimazole.

## Introduction

Onychomycosis is a general term used for fungal nail infections caused by Dermatophytes, non-dermatophyte filamentous molds and also by yeasts (Gupta, 2001). Onychomycosis affects approximately 5% of population worldwide and represents 20–40% of onychopathies and about 30% of mycotic cutaneous infections. Various workers have reported the incidence to vary from 0.5 to 5% in the general population in India (Kaur *et al.*, 2008). Old age, nail deformities, onychodystrophy, repeated trauma, diabetes mellitus, psoriasis, cellular immunity disorders, genetic predisposition, peripheral

arterial circulatory disorder, hyperhidrosis pedum, long term use of immunosuppressant and HIV/AIDS are considered as risk factors for onychomycosis (Nenoff *et al.*, 2014; Zisova *et al.*, 2012).

Superficial fungal infections by *Rhodotorula* species are not seen in immunocompetent individuals, but cases have been reported in critically ill or immunocompromised hosts (Vartivarian *et al.*, 1993; Menon *et al.*, 2014). *Rhodotorula* are uncommon agents in etiology of onychomycosis. To date very few cases of onychomycosis caused by *Rhodotorula* species have been reported (Uludag Altun *et al.*, 2014; da Cunha *et al.*,

2009; Zhou *et al.*, 2014). Only one case of onychomycosis by *Rhodotorula glutinis* has been reported (Uludag Altun *et al.*, 2014).

### Case report

A 63 year old male patient farmer by occupation reported at department of dermatology for complaints of nail deformity and thickness of toe nails of both feet for more than 3 years duration. In the dermatological examinations there was bilateral discoloration and subungual hyperkeratosis of toe nails and onychomycosis was observed clinically (Figure 1). Finger nails were normal. Patient gave history of tinea cruris infection few months back, which was cured by topical antifungal (clotrimazole) application. Patient did not have any chronic disease, malignancy or familial genetic disorder. There was no history of long term broad spectrum antibiotic or systemic steroids intake. Other immunosuppressive states like AIDS were absent. Patient was sent to our Department of Microbiology for fungus culture and sensitivity for infected toe nails.

Nail clippings from affected toes were collected aseptically after cleaning with 70% alcohol and were subjected to 40% KOH mount and Culture on Sabouraud dextrose agar media at 25°C. Culture showed pink-orange colored creamy colony (Figure 2) and identified as Yeast cells forming blastospores on grams staining (Figure 3).

The yeast was identified as *Rhodotorula glutinis* by Vitek 2 automated identification system using Yeast Biochemical Card 2 (YCB). The morphological identification after 72 hour incubation at 25°C on corn meal agar tween-80 showed oval budding yeast cells, no pseudohyphae (Figure 4). Assimilation features using Vitek 2 automated system along with conventional methods identified the yeast as *Rhodotorula*

*glutinis* (Larone, 2002). On subculture pinkish-orange color yeast colony was grown again (Figure 5).

In vitro Antifungal sensitivity testing was done as per CLSI M44-A2 guidelines using disc diffusion method on Mueller-Hinton Agar with 2% Glucose and 0.5µg/ml methylene blue. Quality control was performed using *Candida parapsilosis* ATCC 22019. Zone of inhibition was measured and the yeast was found to be sensitive for ketoconazole, voriconazole, amphotericin-B and nystatin, and resistant to clotrimazole, itraconazole, fluconazole and miconazole (Figure 6).

### Discussion

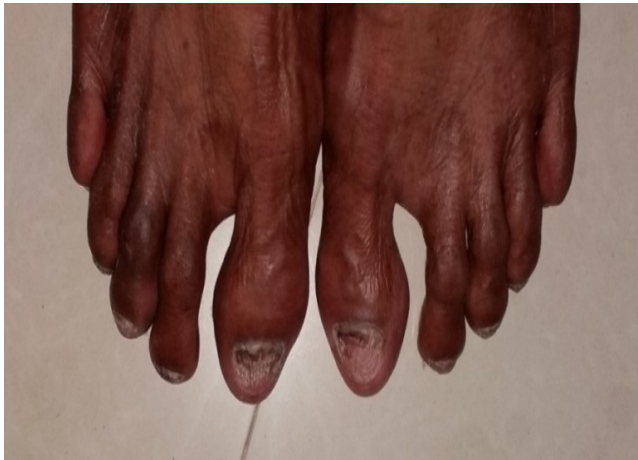*Rhodotorula* species are prevalent in nature found in soil and lakes. They are also found as resident flora on human skin. *Rhodotorula* infections are more frequently isolated in Asia-pacific region (Miceli *et al.*, 2011). Infections caused by *Rhodotorula* are rare though in recent years cases by *Rhodotorula* infections are being reported in patients on central venous catheter (García-Suárez *et al.*, 2011; Braun and Kauffman, 1992) *Rhodotorula* spp. were found to be the fourth most frequently observed species among non-*Candida* yeasts isolated from clinical specimens (Pfaller *et al.*, 2009). In recent years, infection by fungi which were previously thought to be non-pathogenic are being reported in clinical samples. Infections by medically insignificant fungi are also emerging (Walsh *et al.*, 2004).

According to recent studies *Rhodotorula* species could also cause onychomycosis (da Cunha *et al.*, 2009). To date only one case of onychomycosis caused by *Rhodotorula glutinis* has been reported (Uludag Altun *et al.*, 2014). As onychomycosis by *Rhodotorula* species is rare we did re-

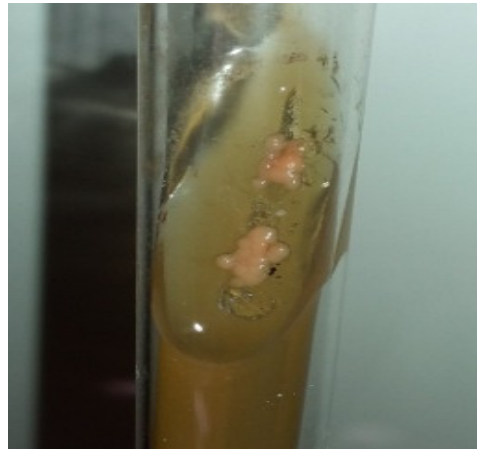sampling and culture of nail specimen. The same species with same biochemical and sensitivity pattern was grown again. Therefore we assumed that the *Rhodotorula glutinis* is the causative agent of onychomycosis in our patient. As this yeast

is normally found in soil and our patient is also a farmer by occupation, there could be a possibility that the patient contracted the infection by repeated microtrauma during working in his fields.

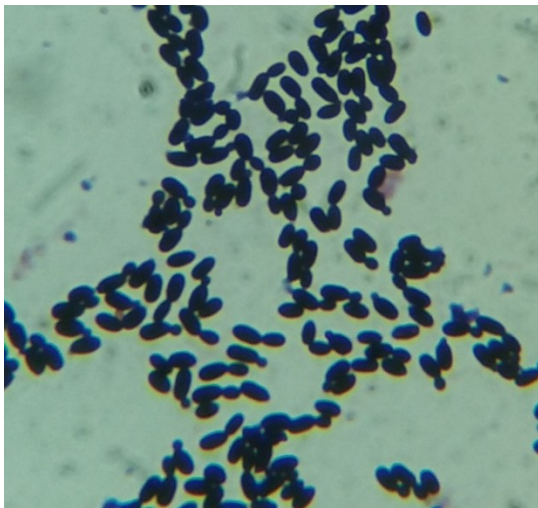
**Figure.1** Discoloration and onycholysis in toenails



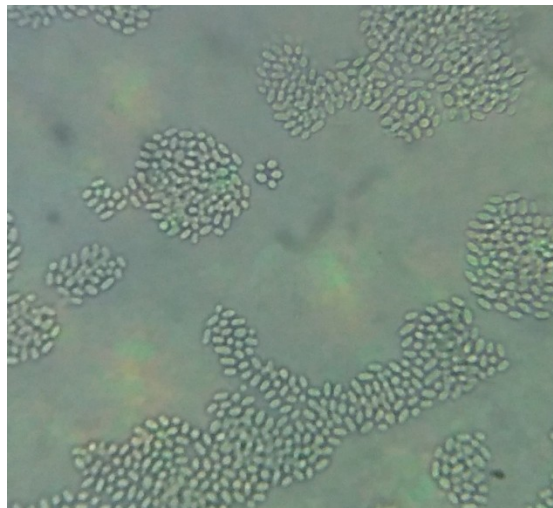
**Figure.2** Yeast colony on SDA after culture



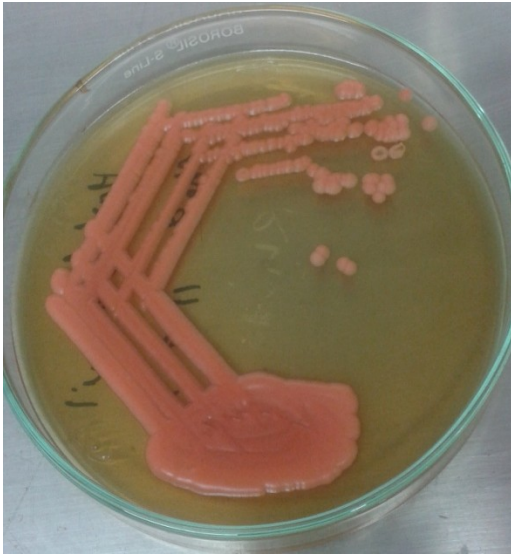
**Figure.3** Oval budding yeast cells on Gram's staining



**Figure.4** Morphology of yeast on Corn meal agar tween-80



**Figure.5** subculture of isolate on SDA

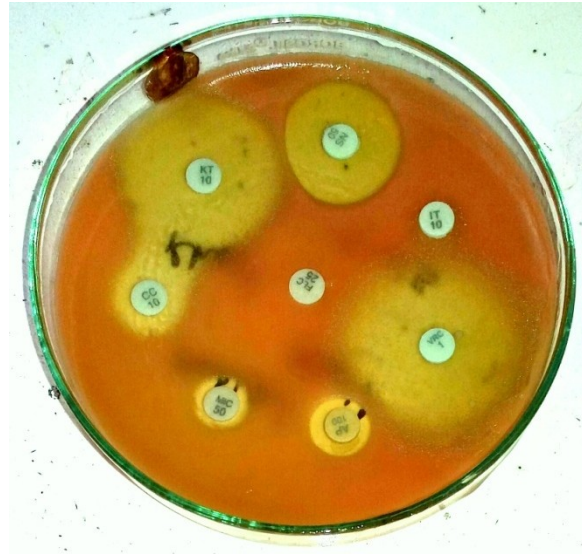

*Rhodotorula* species are similar to the *Cryptococcus* species and it also forms capsule but the capsule is very thin compared to *Cryptococcus*. Production of carotenoid pigment and inability to assimilate inositol differentiate it from *Cryptococcus*.

*Sporobolomyces salmonicolor* also produces *Rhodotorula* like pigment but formation of satellite colonies and production of ballistoconidia differentiates it from *Rhodotorula*. Positive nitrate assimilation differentiates *Rhodotorula glutinis* from *Rhodotorula mucilaginosa* (Larone, 2002).

In vitro susceptibility for *Rhodotorula glutinis* isolated in case of onychomycosis by Uludag Altun *et al.* (2014) were similar for fluconazole, voriconazole and amphotericin-B, but itraconazole to which our isolate was resistant. Some studies have reported resistance to Itraconazole in *Rhodotorula glutinis* similar to our case (Preney *et al.*, 2003; Serena *et al.*, 2004). Resistance to Fluconazole in *Rhodotorula glutinis* has been found universal in several studies (Preney *et al.*, 2003; Serena *et al.*,

**Figure.6** Antifungal sensitivity using CLSI M44 A-2 guidelines



2004; Garcia-Martos *et al.*, 2001; Zaas *et al.*, 2003). Our isolate was also tested sensitive to ketoconazole and nystatin also which were not tested in other studies. Our disc diffusion testing also showed drug synergism between ketoconazole & clotrimazole, and antagonism between ketoconazole & nystatin and voriconazole & amphotericin-B.

### Conclusion

Although *Rhodotorula* species rarely cause onychomycosis, our case supports that *Rhodotorula glutinis* can cause onychomycosis in immunocompetent individuals. Susceptibility test results show that resistance to commonly used oral antifungal agents like fluconazole and itraconazole are of great concern.

### Reference

Braun, D.K., Kauffman, C.A. 1992. *Rhodotorula* fungaemia: a life-threatening complication of indwelling

- central venous catheters. *Mycoses*, 35: 305–8.
- da Cunha, M.M.L., dos Santos, L.P.B., Dornelas-Ribeiro, M., Vermelho, A.B., Rozental, S. 2009. Identification, antifungal susceptibility and scanning electron microscopy of a keratinolytic strain of *Rhodotorula mucilaginosa*: a primary causative agent of onychomycosis. *FEMS Immunol. Med. Microbiol.*, 55(3): 396–403.
- García-Suárez, J., Gómez-Herruz, P., Cuadros, J.A., Burgaleta, C. 2011. Epidemiology and outcome of *Rhodotorula* infection in haematological patients. *Mycoses*, 54(4): 318–324.
- García-Martos, P., Dominguez, I., Marin, P. *et al.* 2001. Antifungal susceptibility of emerging yeast pathogens. *Enfermedades Infecciosas y Microbiología Clínica*, 19: 249–56.
- Gupta, A.K. 2001. Types of onychomycosis. *Cutis*, 68: 4–7
- Kaur, R., Kashyap, B., Bhalla, P. 2008. Onychomycosis-epidemiology, diagnosis and management. *Indian J. Med. Microbiol.*, 26(2): 108.
- Larone, D.H. 2002. Medically important fungi: a guide to identification, 4th edn. American Society for Microbiology Press, Washington, DC, USA. Pp. 131–132
- Menon, S., Gupta, H.R., Sequeira, R. *et al.* 2014. *Rhodotorula glutinis* meningitis: a case report and review of literature. *Mycoses*, 57(7): 447–451.
- Miceli, M.H., Díaz, J.A., Lee, S.A. 2011. Emerging opportunistic yeast infections. *Lancet Infect. Dis.*, 11(2): 142–151.
- Nenoff, P., Krüger, C., Ginter-Hanselmayer, G., Tietz, H.J. 2014. Mycology—an update. Part 1: dermatomycoses: causative agents, epidemiology and pathogenesis. *J. der Deutschen Dermatologischen Gesellschaft*, 12(3): 188–210.
- Pfaller, M.A., Diekema, D.J., Gibbs, D.L. *et al.* 2009. Results from the ARTEMIS DISK global antifungal surveillance study, 1997 to 2007: 10.5-year analysis of susceptibilities of noncandidal yeast species to fluconazole and voriconazole determined by CLSI standardized disk diffusion testing. *J. Clin. Microbiol.*, 47(1): 117–123.
- Preney, L., Theraud, M., Guiguen, C. *et al.* 2003. Experimental evaluation of antifungal and antiseptic agents against *Rhodotorula* spp. *Mycoses*, 46: 492–5
- Serena, C., Pastor, F. J., Ortoneda, M. *et al.* 2004. In vitro antifungal susceptibilities of uncommon basidiomycetous yeasts. *Antimicrob. Agents Chemother.*, 48: 2724–6.
- Uludag Altun, H., Meral, T., Turk Aribas, E., Gorpelioglu, C., Karabicak, N. 2014. A case of Onychomycosis caused by *Rhodotorula glutinis*. *Case Rep. Dermatol. Med.*, 2014: 563261.
- Vartivarian, S.E., Anaissie, E.J., Bodey, G.P. 1993. Emerging fungal pathogens in immunocompromised patients: classification, diagnosis, and management. *Clin. Infect. Dis.*, 17: S487–91.
- Walsh, T.J., Groll, A., Hiemenz, J. *et al.* 2004. Infections due to emerging and uncommon medically important fungal pathogens. *Clin. Microbiol. Infect.*, 10(Suppl. 1): 48–66.
- Zaas, A.K., Boyce, M., Schell, W. *et al.* 2003. Risk of fungemia due to *Rhodotorula* and antifungal susceptibility testing of *Rhodotorula* isolates. *J. Clin. Microbiol.*, 41: 5233–5.
- Zhou, J., Chen, M., Chen, H., Pan, W., Liao, W. 2014. *Rhodotorula minuta* as onychomycosis agent in a Chinese patient: first report and literature review. *Mycoses*, 57(3): 191–195.
- Zisova, L., Valtchev, V., Sotiriou, E., Gospodinov, D., Mateev, G. 2012. Onychomycosis in patients with psoriasis—a multicentre study. *Mycoses*, 55(2): 143–147.