



Case Study

Cardiac Temponade in the Patient of Pulmonary TB [Already on ATT (MDR)]

S.Shriwastav Ashish*, Vinay Pandey, Nabeel M.Ahmed and Neha Srivastava

C6 Gulzaar Residency Behind Andhra Bank Medical Road Aligarh, India

*Corresponding author

ABSTRACT

India is a country that shares a greatest disease burden for TB worldwide approx 40% of Indian population got infection with tubercle bacilli most of them never develop any active disease (Global Tuberculosis Control, 2014). Tuberculosis when present as active disease can involve any part of the body most commonly pulmonary followed by other extrapulmonary sites (e.g. pleura, spine meninges, brain, uterus, peritoneum & rarely pericardium leading to pericardial effusion (mostly hemorrhagic, loculated and exudative) and very rarely this pericardial effusion leads to an emergency condition called as cardiac temponade leading to a very grave prognosis. The confirmation of tuberculous aetiology currently depends on histopathological study of the pericardium, the demonstration of tubercle bacilli in the pericardial tissue or pericardial fluid, the presence of proved tuberculosis elsewhere in the body, or the response to specific treatment. Histopathological examination, however, can at times give non-specific findings even when tubercle bacilli have been cultured from the pericardial fluid (Fowler, 1991). Only treatment is pericardiocentesis to relieve the acute stress on heart followed by the long term treatment on ATT with additional therapy of oral corticosteroids (Strang *et al.*, 1988).

Keywords

Cardiac
Temponade,
Pulmonary
TB

Introduction

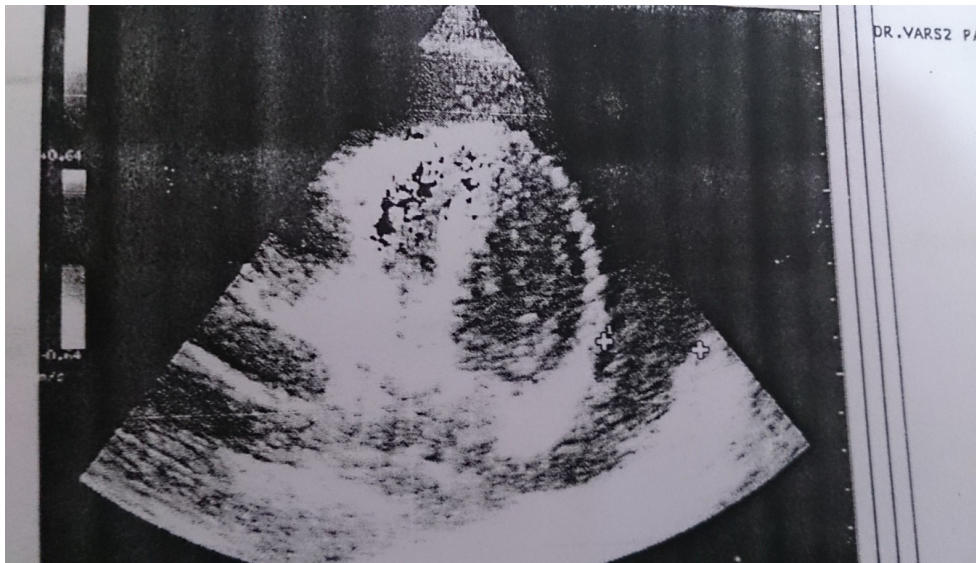
Case summary: A 14 yrs old female a known case of pulmonary kochs on second line ATT since last five months presented to OPD with complaints of progressive dyspnea of NYHA class 4 at presentation since last 4 months. Patient was a regular follow up and her ATT regime was shifted from normal CAT 1 to MDR two months back but still no improvement was there. There was also an associated history of cough with minimal expectoration since last one month.

No history of poor drug compliance, high grade fever, blood loss, cachexia, joint deformity, nausea and vomiting. On examination patient BP was on lower side with narrowed pulse pressure, tachycardia, tachypnea and febrile with temp of 101 'F. Pallor was present, engorged neck vein, JVP was raised with prominent y descent. SYSTEMIC examination of CVS didn't reveal any murmur but heart sounds were muffled. Respiratory & other systems were normal.

On investigating the patient her CBC revealed a microcytic hypochromic anemia with leucopenia, and mild thrombocytopenia, her urine revealed RBC casts and nephrotic range proteinuria, LFT with mildly raised bilirubin, normal KFT. RETI count of 10% GBP suggests marked anisocytosis with hypochromia with reduced platelets and reduced lymphocytes in differentials. CXR PA suggested increased size of cardiac shadow ECG

suggests tachycardia. ECHO was done, revealed 500 ml of fluid with flecks, and evidence of cardiac tamponade RA collapse (Jung, 2012; Appleton *et al.*, 1988) as shown in Figure 1. Pericardiocentesis was done and fluid was sent for evaluation biochemistry of fluid revealed an exudative fluid with TLC of 60/cumm DLC of P55L45. with NEG for AFB stain, gram stain and ADA value of 11.2 (negative) (Trautner and Darouiche, 2001).

Fig.1 Suggestive of pericardial effusion with RA collapse



Until now we were sure that the etiology of this pericardial effusion was non tubercular (also patient was not responsive to MDR regimen).

The disease which is causing this pericardial effusion is having multi system aetiology. with features of haemolytic anemia, lymphopenia, thrombocytopenia, RBC cast in urine, serositis in form of pleural effusion (earlier) and pericardial effusion (present), remission & flares pattern. Regarding this patient was evaluated and Coombs test was done and patient's direct Coombs test was positive. C3 & C4 complement levels were reduced (53.10 &

<8 mg/dl) and patient came positive for ANA(3.2). But to make a confirm diagnosis of SLE anti dsDNA (SLICC SLE criteria, 2014) was ordered and came out to be highly positive (695 IU/ml) suggestive of high disease activity.

Immediately patient was given pulse therapy with high dose IV methyl prednisolone followed by oral corticosteroids with bisphosphonates & oral calcium+vit D.

Patient improved and discharged in satisfactory condition and decision regarding renal biopsy and immunomodulator treatment regimen to be taken in follow up.

Discussion

As already discussed India is facing a great burden regarding patients and treatment cost. In this phase it is mandatory that we as a practitioner only initiate ATT treatment when we have proof not only for TB infection but also active disease. If patient is already on ATT and his condition is not improving, we should not change the treatment regime until confirm the resistant strain on PCR. Being a clinician we should always consider an alternate diagnosis in cases where expected response is not apparent.

Reference

- Appleton, C.P., Hatle, L.K., Popp, R.L. 1988. Cardiac tamponade and pericardial effusion: respiratory variation in transvalvular flow velocities studied by Doppler echocardiography. *J. Am. Coll. Cardiol.*, 1988 May.
- Fowler, N.O. 1991. Tuberculous pericarditis. *JAMA*, 266: 99–103.
- Global Tuberculosis Control 2014, WHO, Geneva, 2014 www.who.int/tb/publications/global_report/:
- Jung, H.O. 2012. Pericardial effusion and pericardiocentesis: role of echocardiography. *Korean Circ. J.*, 42(11): 725–34.
- SLICC SLE criteria, 2014.
- Strang, J.I.G., Kakaza, H.H.S., Gibson, D.G., *et al.* 1988. Controlled clinical trial of complete open surgical drainage and of prednisolone treatment of tuberculous pericardial effusion in the Transkei. *Lancet*, 2(8614): 759–64.
- Trautner, B.W., Darouiche, R.O. 2001. Tuberculous pericarditis: optimal diagnosis and management. *Clin. Infect. Dis.*, 33(7): 954.