



## Review Article

# Deforming Bone Disease: Monostotic Fibrous Dysplasia of Maxilla

C.Shubha\*, G.P.Sujatha and L.Ashok

Department of Oral Medicine and Radiology, Bapuji Dental College and Hospital,  
Davangere, Karnataka, India

\*Corresponding author

## ABSTRACT

### Keywords

Fibro osseous lesion,  
Fibrous Dysplasia,  
Monostotic Fibrous Dysplasia,

Fibro osseous lesion is a commonly used term that includes bone dysplasias, as well as neoplasms and other lesions of bone. Fibrous dysplasia is a skeletal developmental anomaly of the bone –forming mesenchyme that manifest as defect in osteoblastic differentiation and maturation. Fibrous dysplasia is a benign, relatively common disease distinct from other fibro-osseous lesions. In most cases, the disease affects only one bone i.e. monostotic type, however, multiple bones can be involved i.e. polyostotic type. Monostotic fibrous dysplasia, though less serious than polyostotic type is of greater concern to the dentist because of the frequency in which the jaws are affected With this background, this is under taken to review the available literature regarding the historical review, etiopathogenesis, Clinical features, Diagnosis and management of monostotic fibrous dysplasia of maxilla.

## Introduction

Bone is a dense calcified tissue, which is specifically affected by a variety of diseases that often cause it to react in a dynamic fashion. The maxilla and mandible, like other bones, suffer from both the generalized and the localized forms of skeletal diseases. Fibro osseous lesion is a commonly used term that includes bone dysplasias, as well as neoplasms and other lesions of bone. Fibrous dysplasia is a skeletal developmental anomaly of the bone –forming mesenchyme that manifest as defect in osteoblastic differentiation and maturation.<sup>1</sup> Skeletal involvement is the central feature in fibrous dysplasias but extra skeletal abnormalities may form the part of the total disease complex. It has been

described by various names in the literature as intraosseous calcifying fibroma, osteomatous cyst, osteitis fibrosa cystica and ossifying fibroma.<sup>2</sup>

### Historical review

In 1891, fibrous dysplasia of bone was first described by Von Recklinghausen. In 1938, Lichtenstein and Jaffe first introduced the term fibrous dysplasia.<sup>3</sup> In 1942, Lichtenstein and Jaffe, reported different clinical manifestation for that is solitary ( Monostotic) and multiple ( Polyostotic ) forms.<sup>4</sup> In 1946, Schlumberger extensively studied about Monostotic type of fibrous dysplasia.<sup>5</sup> In 1983, Shafer et al described

the radiographic lesion, which is extremely variable depending on the maturity, and 3 basic patterns were seen.<sup>6</sup>

### **Definition:**

- 1) Fibrous dysplasia is a slowly progressive, expansile, benign bony disorder of unknown etiology in which the normal bone is replaced by an abnormal fibrous-osseous tissue.<sup>7</sup>
- 2) Fibrous dysplasia is a genetically based sporadic disease of the bone, its mutation in the gene (GNAS-1) encoding for the alpha sub unit of a signal transducing G-Protein (Gs-alpha) lead to increased C-AMP production affecting proliferation and differentiation of preosteoblasts.<sup>8</sup>

### **Incidence and Prevalence:**

At National institute of health, Bethesda Maryland in 2002, 51 consecutive patients diagnosed with fibrous dysplasia enrolled and participated in an institutional review board- approved clinical protocol. It was observed that fibrous dysplasia occurred more often in Maxilla (38 Patients, 88.4%), than Mandible (33 patient, 76.7%), but 28 (65.1%) patient presented with fibrous dysplasia in both Maxilla and Mandible.<sup>9</sup>

The monostotic form affects only one bone and corresponds to 70-80% of Fibrous Dysplasia cases. The polyostotic form corresponds to 20-30% of cases. The craniofacial bones are more affected in the polyostotic (50-100%) than in the monostotic form (20%).<sup>10</sup>

### **Etiopathogenesis**

In 1942, Lichtenstein and Jaffe proposed abnormal differentiation of mesenchyme as a cause of the bony abnormalities. In 1957, Changus proposed osteoblastic hyperplasia

as the underlying pathologic process in fibrous dysplasia. The Monostotic variety may result from a developmental defect or hamartoma, possibly stimulated by trauma and by aberrant activity in the bone forming mesenchymal tissue.<sup>7</sup>

Fibrous dysplasia usually occurs with no family history, although craniofacial form of dysplasia has been shown to be inherited in an autosomal dominant fashion. Activating mutations within the guanine nucleotide binding protein gene (GNAS1) (MIM139320), located on chromosome 20q13.2-13.3, have been identified in Monostotic fibrous dysplasia.<sup>11</sup>

More recently, Marie et al and Riminucci et al have shown that the development of fibrous dysplasia reflects a complex derangement in the function of cells in the osteogenic lineage. Implicated in the development of the lesions are activating mutations of the alpha subunit of G signaling protein (Gs alpha) in osteoblastic cells. A substitution of either cys or his for arg at position 201 in Gs alpha leads to loss of guanosine triphosphatases activity of Gs alpha. This allows for activation of adenylyl cyclase, overproduction of 3'-5' cyclic adenosine monophosphate (cAMP) (Shenkar et al in 1994) and increased cell proliferation and inappropriate cell differentiation. This missense mutation results in a disorganized fibrotic bone matrix, which has been demonstrated in patients with Monostotic form of fibrous dysplasia.<sup>12</sup>

Fibrous dysplasia stimulates release of several cytokines (mainly Interleukin -6) which cause normal osteoclasts to congregate and increase bone resorption (Mandrioli et al 1998). It has been confirmed that fibrous dysplasia is caused by a somatic activating mutation of the alpha sub unit of

the stimulatory guanine nucleotide binding protein. This mutation activates adenylate cyclase and consequently increases intracellular concentrations of cAMP resulting in abnormal osteoblasts in differentiation and production of dysplastic bone (Vasikaran et al 2001).<sup>13</sup>

### **Clinical Features:**

Phemister and Grimson in 1937 said that the Monostotic variety is a slow growing, and it occurs mainly in children and in young adults. Fibrous dysplasia appears in late childhood. The average age of onset is 10 years.

Fibrous dysplasia grows slowly, causing expansion of the jaw and producing a non-tender facial asymmetry. As a rule, the lesion stops growing when skeletal growth ceases, but cases have been reported in which the lesion continued to enlarge after that time. The expansion is smooth and covered with normal appearing mucosa or skin. Ulceration overlying the bony enlargement is uncommon, but may be seen when mass disrupts the occlusion or is traumatized during eating. Pain or paresthesia is unusual. Teeth in the area of involvement may show minimal migration or displacement. In children, teeth in the affected area may fail to erupt.<sup>14</sup>

In the facial region, contour enlargements of the bone may produce grotesque deformities. The paranasal sinuses are often collapsed and one or both eyes may be vertically displaced or exophthalmic due to compression against the globe from the expanding bone. Visual problems or dizziness is common when facial bones are involved and maxillary dysplasia will lead to epiphora. Growth into the maxillary sinus may produce symptoms due to blockage of drainage, and growth into the orbit may

cause visual disturbance from proptosis or general displacement of the orbital contents.<sup>15</sup>

### **Radiographic features:**

The radiographic appearance of fibrous dysplasia is a function of its histologic structure. If there is a predominance of osseous elements, the lesion is more opaque. A mixture of fibrous and bony elements produces a ground glass appearance, while predominance of fibrous elements produces a radiolucent cyst like picture. X-ray films may show mottled, irregular densities if the abnormal tissue contains spotty areas of calcification. The maxilla, particularly the maxillary sinuses, and the base of the skull tend to present a more sclerotic picture. Cortical bone becomes expanded and thinned with no evidence of periosteal reaction and in larger tumors the bone becomes completely eroded. In the younger age groups the lesion appears as a homogenous density with a somewhat stippled appearance, but in older tumors greater density is present due to increased bone content.<sup>16</sup>

Fries distinguished three types: (1) sclerotic fibrous lesions of the medulla; (2) soap-bubble osteolytic type; and (3) mixtures of types 1 and 2-pagetoid patterns. In the skull bones, fibrous dysplasia has its localization in the diploe.<sup>17</sup>

The radiographic appearance of the lesion may be seen in three basic patterns. It may appear as a small unilocular or large multilocular radiolucency with well-circumscribed border. In the second type, the pattern is similar except increased trabeculation renders the lesion more opaque and typically mottled in appearance. The third type is quite opaque with many delicate trabeculae giving a ground glass or

orange peel appearance (Shafer et al 1983).<sup>14</sup>

Other patterns were reported by Waldron and Giansanti as “Smoky” and “Cloudy” and by Obisesan and co workers as “Peau-de orange”, “Whorled”, or “Diffuse sclerosis”.<sup>18</sup>

### **Role of Computed Tomography and Magnetic Resonance Imaging:**

Expansion of involved bone with a heterogeneous pattern of CT densities, along with intact thin cortex, is a characteristic of fibrous dysplasia. CT attenuation levels have been reported to range from 34- 513 HU depending on the fibrous tissue and bone content. CT has also made possible to define the boundaries and connections of the lesion, to exclude a Polyostotic craniofacial form, to identify other possible associated disorders and to monitor evolution of the disease.<sup>19</sup>

Fibrous dysplasia has an intermediate signal on T1- weighted and heterogeneous hypotense signal on T2- weighted MR images. There may be areas of T2 hyperintensity, in early stages of disease. Following a intravenous administration of Gd-DTPA, there is often moderate to marked contrast enhancement. The degree of contrast enhancement on T1 weighted images depends on amount and degree of bone trabeculae and collagen present. Both CT and MRI are excellent imaging modalities in defining craniofacial fibrous dysplasia.<sup>7</sup>

### **Histological Feature:**

Gross inspection of bone lesion reveal a variable appearance depending upon the degree of ossification, vascularity and hemorrhage. The color ranged from white to

gray to pale yellow. The bone cortex often reduced to a thin expanded shell and the central defect filled with fibrous tissue, which varied in consistency from soft and edematous to tough, firm and rubbery. Some lesions may shell out as if encapsulated where as others are infiltrative with diffuse indefinite margins.<sup>17</sup>

Histologically, the fibrous tissue component is non-descript without pattern and is of variable cellularity. The osseous component includes irregularly shape trabeculae of osteoid and immature (Woven) bone arising metaplastically from the fibrous stroma; is poorly oriented with misshapen bony trabeculae, increased cellularity, and irregular margins; and forms odd geometric patterns including “C” or “S” shaped configurations, curvi linear shape, V or W shape (so called Chinese characters), “jigsaw puzzle”. The trabeculae typically lack osteoblastic rimming. Multinucleated giant cells, macrophages, increased vascularity, and calcification may be seen. Under polarized light bone appears woven rather than lamellar; however, lamellar bone can be seen in fibrous dysplasia and its presence does not exclude the diagnosis.<sup>12</sup>

Riminucci et al have suggested site-specific patterns of histopathology in fibrous dysplasia. They identified 3 patterns: Chinese writing type, associated with the axial and appendicular skeleton; sclerotic/ pagetoid type, associated with the cranial bones; and sclerotic / hypercellular type, associated with the maxilla and mandible.<sup>20</sup>

### **Laboratory Investigations:**

Laboratory investigations help to differentiate from other diseases, although Fibrous dysplasia may be associated with hormonal changes as well as defects in calcium phosphorous metabolism. As per

the literature, specifically serum calcium, phosphorus, and alkaline phosphatase, are usually within normal ranges in patients with Monostotic fibrous dysplasia.<sup>21</sup>

### **Management:**

There are no uniformly accepted guidelines for treatment of this disease, but the three general approaches involve monitoring, medical management, or surgery.

#### **1) Monitor-**

Certain cases may be monitored for disease activity and progression. Depending of the location of the lesions, age of the patient, and the patients' views towards surgery, serial clinical examinations may be the best option. These should place particular emphasis on the cranial nerves and a thorough ophthalmologic assessment. CT scanning and bone scintigraphy may be obtained to monitor disease progression. Rapid development of diplopia, pain, or visual loss should alert the clinician to a co-existing mucocele or hemorrhage.<sup>12</sup>

#### **2) Medical-**

No medical treatment is available to cure or definitively halt the progression of the disease. Cortisone has been reported to produce some relief in the pain of bone lesions. This is not consistent. Aluminum acetate has been used, at times, to help precipitate phosphate in the bowel and thus reduce the danger of hyperphosphataemia i. e. associated with severe forms of fibrous dysplasia. Hormone therapy has little effect on the course of the disease.<sup>22</sup> Evidence of increased osteoclastic activity and increased fasting urinary hydroxyl proline, has led to investigations with ante-resorptive drugs. Calcitonin, mithramycin, and

etidronate have also been tried in a few cases with little success.<sup>12</sup>

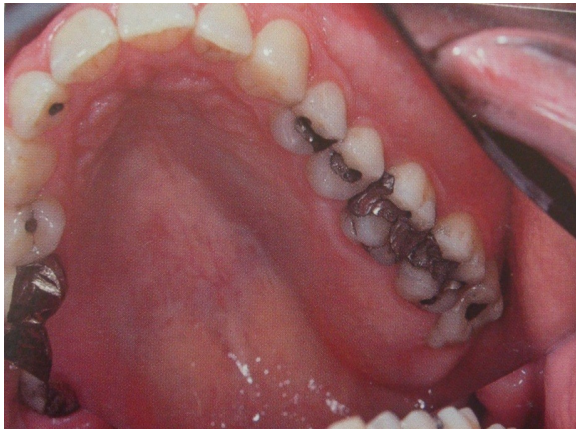Osteoclasts resorbing the area of bone covered by the drug incorporate the agent into the cytoplasm where it inhibits acid phosphatase secretion there by arresting bone resorption, prevention of secretion of osteoclasts stimulating factors and inhibition of resorptive action of osteoclasts. Palmidronate containing a basic nitrogen atom in its alkyl side chain represents a second-generation drug, characterized by increased potency of inhibition of bone resorption and good tolerance. Palmidronate appears to be an effective and well-tolerated therapeutic option for patients with fibrous dysplasia. In the future, the combination of the metabolic blockage of the dysplasia by palmidronate and limited non- mutilating interventions are possible.<sup>23</sup>

#### **3) Surgery-**

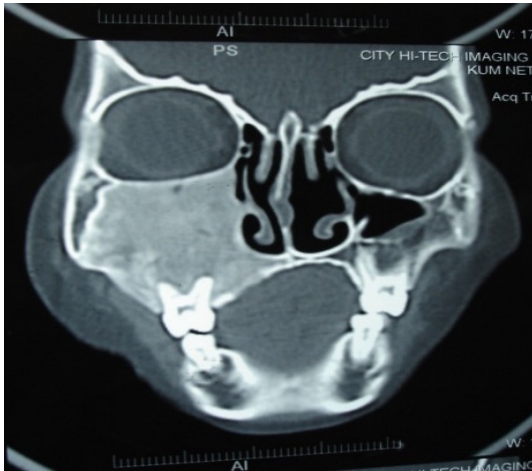
The treatment of facial fibrous dysplasia is surgical, involving excision and or curettage. In children, the surgical procedure should be delayed, if possible, until after puberty when the lesion tends to become static. According to Zimmerman and colleague approximately 20% of the lesions continue to grow after treatment, except those treated by radical excision. Radiotherapy is contraindicated because of the possibility of subsequent development of radiation-induced sarcomas.<sup>24</sup>

Early radical surgery has been advocated both as a means for prophylaxis and for reversing compressive forces.<sup>12</sup>

**Fig 1:** Expansile lesion of left maxilla



**Fig 2:** CT shows a radiodense area in the right maxillary antrum and the ground glass appearance of the maxillary antrum with obstruction of the maxillary ostium, and the orbital floor is pushed upwards



### **Malignant transformation:**

Malignant transformation to osteogenic sarcoma is rare, although rapid, expansile growth and surrounding destruction may frequently give a false impression of malignancy. However, there seems to be a relationship between irradiation and malignant degeneration according to

several reports, an overall risk of malignant change of 0.5% (or 1 in 200 cases), if left untreated.<sup>25</sup>

To conclude, fibrous dysplasia has the potential to cause significant cosmetic and functional disturbance, especially visual impairment. Substantial progress has been made over the past decade to understand the disease and accurately point out the gene causing it. Although surgical management is required in Fibrous dysplasia, the role of genetic manipulation in the management of the disease has to be explored in the near future.

### **References**

1. Shafers, Hine, Levy. Text Book of Oral Pathology. 5<sup>th</sup> ed. New Delhi: Elsevier, 2006.
2. Gupta DS, Gupta MK. Monostotic Fibrous Dysplasia- A Case Report. Journal Indian Dent. Asso. Nov 1982; 54: 425-427
3. Pontual MLDA, Tuji FM, Yoo HJ, Boscolo FN, Almeida SM. Epidemiological study of fibrous dysplasia of the jaws in a sample of Brazilian population. Odontologia. Clin.Cientif., Recife, Jan 2004; 3(1): 25-29
4. Mahajan S, Kamboj M, Baoz K. Maxillofacial fibrous dysplasia- A case report. IJDR, 2005; 16 (4): 151-152.
5. Schrire T. Fibrous dysplasia of the maxilla with a method for preventing contractures after maxillectomy. S.A. Medical Journal, Dec 1956; 8: 1185-1187.
6. Muralidhar M, Sohoni S, Raghavan MRV. Monostotic Fibrous dysplasia of Maxilla. J Indian M A, sept 1987; 85 (9): 273-277.

7. Aniece C, Raj BD, Singh BS, Parvez K, Anayat L. Monostotic fibrous dysplasia of the Temporal bone. *Indian Journal of Otolaryngology*, Dec 2008; 14: 16-21.
8. Jankowski DSM, Li TK. Fibrous dysplasia in a Hong Kong community: The clinical and radiological features and outcomes of treatment. *DMFR*, 2009; 38: 63-72.
9. Akintoye et al. Analyses of variable panoramic radiographic characteristics of maxillo-mandibular fibrous dysplasia in McCune Albright syndrome. *Oral Diseases* 2004; 10: 36-43.
10. Jyothi Mahadesh, Charan Gowda, Laxmi Devi, Kokila G. Fibrous Dysplasia of the Jaw Bones: Clinical, Radiographical and Histopathological Features. Report of Two Cases. *Journal of Dental Sciences & Research*, 2011; 2(1):18-25.
11. Jankowski DM. Fibrous dysplasia: A systemic review. *DMFR* 2009; 38: 196-215
12. Ricalde P, Horswell BB. Craniofacial fibrous dysplasia of the fronto-orbital region: A case series and literature review. *J Oral Maxillofac Surg* 2001; 59: 157-168.
13. Kos M, Luczak K, Godzinski J, Klempous J. Treatment of Monostotic fibrous dysplasia with Pamidronate. *Journal of Cranio-Maxillofacial Surgery*, 2004; 32: 10-15.
14. O'Connell KJ. Bony enlargement of the left maxilla. *JADA*, March 1981; 102: 340-342
15. Chen YR, Noordhoff MS. Treatment of Craniomaxillofacial fibrous dysplasia: How early and how extensive? *Plastic and Reconstructive Surgery*, November 1990; 86(5): 835-842.
16. Williams AQ, Browne RM, Akinosi JO. *Journal of National Medical Association* May 1974; 66(3): 185-191.
17. Lustig LR, Holliday MJ, McCarthy EF, Nager GT. Fibrous dysplasia involving the skull base and temporal bone. *Arch Otolaryngol Head Neck Surg*. 2001; 127: 1239-1247.
18. Jankowski DM. Fibrous dysplasia in the jaw of a Hong Kong population: radiographic presentation and systemic review. *DMFR* 1999; 28: 195-202.
19. Neyaz Z, Gadodia A, Gamanagatti S, Mukhopadhyay S. Radiographical approach to jaw lesions. *Singapore Med Journal*, 2008; 49(2): 165-176.
20. Akintoye et al. Dental characteristics of fibrous dysplasia and McCune-Albright syndrome. *Oral Surg Oral Med Oral Pathol Oral Radiol Endod*, 2003; 96: 275-282.
21. Regezzi JA, Sciubba JJ, Jordan RCK. *Oral Pathology- Clinical Pathologic Correlations*. 4th ed, St Louis: Saunders, 2003.
22. Edgerton MT, Persing JA, Jane JA. The surgical treatment of fibrous dysplasia. *Annals of Surgery*, October 1985; 202(4): 459-478.
23. Kuhli C, Luchtenberg M, Weidauer S, Ohrloff C. Unilateral exophthalmos Associated with severe Fibrous Dysplasia. *Ophthalmologica*, 2005; 219: 181-184.
24. Ruksujarit T, Kitsahawong S, Thongdee P. Multidisciplinary approach to the management of fibrous dysplasia of the maxilla: A case report. *KDJ*, Jan-June 2004; 17(1): 49-60.
25. Waldron CA. Fibro-osseous lesions of the Jaws. *J Oral Maxillofac Surg* 1993; 51: 828-835.