

Original Research Article

Biochemical and Histochemical studies on white ginseng roots for ameliorating aflatoxicosis in rats

Abdel- Fattah, Sh. M¹, Safaa M A², Sanad M I², Helal A D³,
Sarfinaz S Abd ElGhany³ and Ragaa F. F.Ghanem²

¹Department of Food Toxins and Contaminants, National Research Centre, Dokki, Cairo, Egypt

²Department of Biochemistry, Faculty of Agriculture, Mansoura University, Mansoura, Egypt

³Pathology Department, Animal Health Research Institute, Cairo, Egypt

*Corresponding author

ABSTRACT

This study was carried out to evaluate the toxic actions of aflatoxins and the rule of ginseng roots through the histochemical and biochemical studies. Thirty of apparently healthy adult female albino rats were divided into five equal groups, the 1st and the 2nd groups served as negative and positive control. The other three groups fed aflatoxins-contaminated diets. But the proposed additive (ginseng roots) was only added to the 4th and 5th groups at levels 1 and 2 gm / 100 gm ration, respectively. The treatment period was extended for four weeks. Ginseng treatment significantly reduced the elevated levels of ALT and AST enzyme activities and the elevated concentrations of serum urea and creatinine. From the semi quantitative histochemical study, it could be concluded that ginseng roots could improve the disturbance in the mitochondrial oxidative phosphorylation in rat hepatocytes. In the light of these results, the proposed additive ginseng was found to induce the potent protective action in rats may play a role in the prevention of hepatic cellular injury produced by aflatoxins. The exact mode of antitoxic action may need further clarification and there is an urgent need to conduct further in vivo studies with white ginseng roots, which may provide a useful tool to improve efficiency of nutrient utilization in the rumen and could be recommended to small farm animal's diet with possibility of aflatoxin contamination.

Keywords

Ginseng –
aflatoxins –
histochemistry
–aflatoxicosis –
food additives

Introduction

Human and animal health has been dramatically affected in outbreaks of acute mycotoxicosis, but these tragic events may be only a part of the cost to society in terms of impaired health and productivity from the ingestion of sub-clinical levels of aflatoxins

(WHO, 1981; Saad, 1993; Moos, 2002; Abdel-Fattah *et al.*, 2006, 2010). Aflatoxin B1 (AFB1) is the most abundant and toxic form of all naturally occurring aflatoxins. AFB1 represents 75% of all aflatoxins found in contaminated food and feeds. Many reports stated the harmful effects of

aflatoxins on wide variety of animals and human; depression of growth and production (Saad, 1993; Abdel-Fattah *et al.*, 2010), immunosuppressant (Yeong–Hsiang, 2001), liver disorders (Anong and Suparats, 2006), abnormalities of enzyme picture (Patrick *et al.*, 2002; Tulayakul *et al.*, 2005; Ozer *et al.*, 2008). However, such harmful effects seem to be difficult to overcome since aflatoxicosis gave no reaction response for any available treatment of drugs and / or antibiotics (Saad, 1993).

Currently, there is a strong debate about the safety aspects of chemical preservatives, since they are responsible for many carcinogenic and teratogenic attributes as well as toxicity. So there is an increasing interest to phytochemicals as new sources of natural antioxidants and antimicrobial agents (Moreira, 2005).

Natural substances that can prevent AFB1 toxicity would be helpful to human and animal health with minimal cost in foods and feed. Traditional medicinal plants were used by some authors for their antifungal, anti-aflatoxigenic and antioxidant activity (Joseph *et al.*, 2005; Kumar *et al.*, 2007).

Ginseng has been used for over 2000 years in oriental countries to enhance stamina and immune function, where it has been suggested to have pharmacological activities in the cardiovascular, endocrine, immune and central nervous systems (Li *et al.*, 1999; Attele *et al.*, 1999; Moreira, 2005). The full pharmaceutical activity of ginseng is due to a range of compounds, the triterpene saponins, known as ginsenosides, are widely considered to be the most important components contributing to the multiple medicinal properties of both Asian and American ginseng. The two major groups of ginsenosides are the Rb and Rg groups, which have 20 (S) protopanaxadiol and 20

(S) protopanaxatriol, respectively, as the sapogenines. Rb group includes the ginsenosides Rb1, Rb2, Rc and Rd, while Rg group includes the Re, Rf and Rg1 ones as the main compounds. Among all these ginsenosides, Rb1 and Rg1 are the most effective compounds (Tanaka and Kasai, 1984). Ginseng roots and ginsenosides are effective in stimulating learning, memory and physical capabilities, in supporting radioprotection and provide resistance to infection (Necerino *et al.*, 2000; Rudakewich *et al.*, 2001).

In animals feed diets contaminated with toxicants, the AST and ALT levels increased after liver damage due to the increased membrane permeability or liver cell necrosis and cytosol leakage into the serum (Ozer *et al.*, 2008).

The aim of the current study is to investigate the mode of toxicants of aflatoxicosis and the mode antitoxic action of white ginseng roots against toxicity in rats through the present histochemical and serum biochemical studies in laboratory animal (rats), in order to appreciate the potential protective effects of this medicinal plant.

Materials and Methods

Experimental animals

One-month old female white Albino rats weighting 100–110 gm in average (purchased from animal house of National Research Centre, Cairo, Egypt) were maintained on standard lab diet (protein: 160.4; fat: 36.3; fibre: 41 gm/kg and metabolizable energy 12.08 MJ), and housed in a room free from any source of chemical contamination, artificially illuminated and thermally controlled, at the Animal House Lab., National Research Centre, Dokki, Cairo, Egypt. All animals were received human care in compliance with the

guidelines of the Animal Care and Use Committee of the National Research Centre, Dokki, Cairo, Egypt.

Experimental design

Depending on our previous results (Abdel-Fattah 2002, Abdel-Fattah *et al.*, 2006; Abu-Seif, *et al.*, 2009), concerning the antitoxic effects of herbs and medicinal plants, this study was achieved. Thirty apparently healthy female adult albino rats were divided into five equal groups, all groups were exposed to the main two stages of the experiment period as follows; the first 2 weeks were the pre-treatment period, followed by 4 weeks of treatment. During pre-treatment period all animal groups fed on sound rations free from either the studied additive material (white ginseng roots, WG) or aflatoxin contamination. At the treatment period, both the 1st and 2nd groups were fed on sound rations, free from aflatoxins. But the 1st one had no additive acting as “negative control”, while the 2nd group fed on the same sound ration plus the studied additive at concentration equivalent to 2 % (w/w), considered as positive control. The other three groups ingested aflatoxin(s) contaminated diets containing 225 mg B1, 30 mg B2, 70 mg G1 and 10 mg G2 /kg . The 3rd group exposed to contaminated diets only without any addition, but the 4th and 5th groups fed on aflatoxin(s) contaminated diets, plus the proposed additive material (WG) at 1 and 2 gm / 100 gm ration. At the 29 th of the treatment period, all animals were fasted for 12 h, and then blood samples were collected from the retroorbital venous plexus under diethyl ether anesthesia. Sera were separated using cooling centrifugation and stored at -20 °C until analysis for biochemical studies. After the collection of blood samples, animals were sacrificed for obtaining fresh unfixed liver samples for the following histochemical study.

Organisms

Aspergillus parasiticus (*A.parasiticus*) NRRL 2999 was obtained as lyophilized preparation from the Mycotoxin lab. , National Research Center, Dokki, Giza, Egypt.

Plant material

American white ginseng material was purchased from an Egyptian local market (Harraz Co., Cairo, Egypt).

Aflatoxins standards and chemicals

All standards of Aflatoxins (B1, B1, G1, and G2) were purchased from sigma company, USA. All Chemicals and solvents used were of ACS grade. Thin layer TLC aluminum plates recoated with 0.25 mm silica gel 60 (Merk).

Preparation of aflatoxin(s) - artificially contaminated ingredient

A balanced ration of growing rats with 14 % crude protein and 3100 kg calorie were purchased and artificially infected (in vitro) with a certain strain of *Aspergillus parasiticus* (NRRL-2999) which identified as an aflatoxin(s) producing strain inoculated substrates were incubated at 28 °C for 18 days (Shotwell *et al.*, 1966). Aflatoxins (AFs) within the contaminated material consisted of 225 mg B1, 30 mg B2, 70 mg G1 and 10 mg G2 /kg. The contaminated material was incorporated into the basal diet in the ratio 15.55. % of the daily ration, to provide the desired level of 1.042 mg of total AFs or 0.7 mg AFB1/Kg diet.

Histochemical study

The fresh liver unfixed tissue samples of rats of the five group were taken and the cryostat freezer plate method (Sheehan and

Hrapchak, 1980) and the histochemical techniques were carried out for semiquantitative estimation of mitochondrial adenosine-tri-phosphatase (ATP-ase) (Wachstein and Meisel, 1957), succinic dehydrogenase (SDH-ase) (Nachlas *et al.*, 1957), Glucose-6-phosphatase (G6PD-ase) (Cohen and Way, 1966) and reduced Nicotinamide adenine dinucleotide Diaphorase(NADH-ase) enzyme (Nachlas *et al.*, 1958). The enzyme activities were semiquantitatively estimated from traces (\pm) to intense (+++++) reactions according to (Pearse, 1972).

Serum Biochemical constituents

The serum of rats of the five studied groups were used for estimation of serum Alanine amino transferase (ALT) and serum Aspartic amino transferase (AST) enzymes activities (Reitman and Frankel 1957) and the concentrations of serum urea and creatinine (Patton and Crouch 1977).

Aflatoxins analysis

Qualitative and quantitative assay for the presence of aflatoxins in the contaminated substrate has been carried out using HPLC (Agilent Technologies, Waldbronn, Germany) as recommended by AOAC (2000).

Determination of active components in investigated white ginseng roots

To determine the ginsenosides in white ginseng roots, five gm of white ginseng roots were extracted in soxhlet apparatus using ethanol 70% (v/v). The extract was evaporated to dryness and dissolved in 30 ml distilled water. The aqueous solution was first extracted two times with 25 ml of ether each time; the aqueous layer was then extracted three times with 20 ml of water-saturated with n-butanol each time. The n-

butanol fraction was evaporated and the residue (2.52%, w/w) was dissolved in 10 ml of methanol. The sample solution was filtered and the ginsenosides contents were analyzed by high performance liquid chromatography according to the method of (Ko *et al.*, 1989).

Statistical Analysis

The obtained data were statistically analysed using Analysis of Variance (ANOVA), one way classification according to (Snedecor and Cochran 1966) and the significances between treatments and periods were determined using Duncan's Multiple Range test (Duncan, 1955).

Results and Discussion

Determination of active components in investigated white ginseng roots

Table 1 revealed that seven ginsenoside compounds were recognized in white ginseng roots, namely Rb1, Rb2, Rc, Rd, Re, Rg1 and Rg2 which their concentrations are 9.45, 0.07, 1.77, 3.02, 3.14, 0.26 and 0.13 mg/gm ginseng, respectively. In addition, two unknown compounds which their concentrations are 3.4 and 3.96 mg/gm ginseng were determined. Our results were in accordance with those obtained by wang *et al.*, 2008

Biochemical study

The liver functions were examined through the determination of alanine amino transferase (ALT) and aspartate amino transferase (AST) activities which known as cytosolic marker enzymes reflecting hepatocellular necrosis as they are released into the blood after cell membrane damage, therefore both enzymes are used as indicator for hepatic damage (Andallu and

Vardacharyulu, 2001). Whereas increased levels of urea and creatinine may indicate protein catabolism and/or renal dysfunction (Abdel-Fattah *et al.*, 2010).

Data for selected serum constituents are presented, from the beginning and the end of the treatment period, in Tables 2 and 3. There is no a consistent pattern shown in the metabolic indicators as influenced by the AFs and / or the WG food additive. The average(s) of the transaminases (ALT and AST) level and both urea and creatinine concentrations showed the normal picture during the pre-treatment stage with no differences between groups (Table 2). During the treatment stage, the groups 1 and 2 showed constant level of both ALT and AST enzymes activities, while serum activities of ALT and AST of animals fed dietary AFs only (group 3) had elevated ($p \leq 0.05$) compared with those fed sound rations with or without WG additive. Similarly, urea and creatinine concentrations were higher ($p \leq 0.05$) at the end of the treatment period for group which fed AF-contaminated diet only (Table 3). On the other hand, the level(s) of both ALT and AST activities were not significantly affected during treatment in the 4th and the 5th groups, leading to suggest the positive effect of studied additive on the liver function when the animals exposed to high level of aflatoxin(s) contamination.

Tracing the level(s) of transaminase ALT and AST in both animals of the 2nd group which received the additive only without any level of contamination, it could be easily noted that no changes were obtained during the two successive stages of the study.

The obtained data were in accordance with those reported by Yeong-Hsiang *et al.* (2001), working on ducklings, Biing-Hui *et al.* (2002) on swine and Anong and Suparats (2006) on broilers. High serum levels of

AST and ALT are usually indicative of liver damage in animals (Lind *et al.*, 1989) and humans (Gil *et al.*, 1988; Hassal *et al.*, 1990; Rati *et al.*, 1991).

Several studies on the mechanisms of aflatoxins induced liver injury have demonstrated that in animals fed diets contaminated with toxicants, the serum levels of these enzymes increased after liver damage because of increased membrane permeability or because of liver cell necrosis and cytosol leakage into the serum (Teppema *et al.*, 2002; Saad and Abdel-Fattah, 2008; Ozer *et al.*, 2008; Sherif *et al.*, 2009). Damage of cellular components may play an important role in death of liver cells (Lind *et al.*, 1989; Teppema *et al.*, 2002), hence, ALT and AST may be released to serum levels of these enzymes would increase.

Adding of WG during aflatoxin treatment succeeded to improve ALT, AST, activities and a significant improvement was also found in urea and creatinine concentrations. In the same regards, Kim *et al.* (1997) reported that ginseng has a potent protective action against CCL4-induced toxicity and it showed inhibitory effect on cytochrome P450-associated monooxygenase activities. Therefore, it is suggested that the protective effect of WG is attributed to its free radical scavenging activity (Abdel-Wahhab and Ahmed, 2004; Mannaa *et al.*, 2006 Abdel-Fattah *et al.*, 2010).

Treatment of the intoxicated rats with WG resulted in significant improvement in kidney function as indicated by the marked decrease in serum urea and creatinine levels. These results were in conformity with those reported by Yokozawa *et al.*, (1994) who demonstrated that WG and its active component, saponin, could significantly reduce the blood urea nitrogen and

creatinine levels in the blood of nephrectomized rats. Other studies asserted the nephroprotective effect of Korean ginseng saponin against cisplatin-nephrotoxicity (Liu and Zhou 2000; Abdel-Wahhab and Ahmed, 2004).

These authors suggested that Korean ginseng saponin reduced cisplatin-induced cytosolic free (Ca²⁺) ions overload and formation of DNA interstrand cross-link and DNA-protein cross-link. Furthermore, Yokozawa and Liu (2000) demonstrated that ginsenoside could decrease the severity of renal injury induced by cisplatin. These authors suggested that decreased level of urea in serum in rats given WG reflected the protective action of ginsenoside against the renal dysfunction.

Generally, these results indicated that WG have protective effects against liver injury induced by aflatoxins and it plays a role in increasing the antioxidant status as well as lowering the oxidative damage of nucleic acids in the body (Abdel-Wahhab and Ahmed, 2004; Mannaa *et al.*, 2006).

Our results may lead us to suggest that there is a significant liver and kidney dysfunction in the AF-treated groups, 1.0421mg of AFs / kg diet was sufficient to impair performance and cause liver and kidney damage in female Albino rats, adding of WG during the mycotxins treatment (groups 4 and 5) resulted in a significant improvement in ALT and AST activity as well as urea and creatinine concentrations.

It was suggested that WG displays a pronounced hepatoprotective effect, assessed through the transaminases (ALT, AST) activities following hepatotoxicity in rats treated with AF-contaminated diets.

Histochemical study

The current study demonstrated that Glucose-6-phosphate dehydrogenase enzyme (G6PD-ase) was increased more prominently by AFs intoxication in rat's liver (Table 4 and Figures 1, 2, 3, 4, 5); such increase could be reduced by ginseng treatment especially by the dose 2% concentration. G6PD-ase is the metabolic enzyme involved in the pentose phosphate pathway and especially important in red blood cells of human to prevent the non-immune haemolytic anemia (Frank, 2005).

The G6PD-ase and the non-specific esterase enzymes were increased in the keratinocytes and mitochondria rich cells of frog in response to increase the oxidation process and the toxic stress that may induced by mercury, cadmium and lead pollutants (Fenoglio *et al.*, 2006). On the other hand, the increase of enzymes such as G6PD-ase activity may due to both synthetic and detoxification processes as an adaptive response against toxins such as methyl parathion, organophosphorus insecticide sub-lethal toxicity in *Tilabiamossambica* fish (Rao and Rao, 1987).

The present work indicated that there was intense increase of succinic dehydrogenase (SDH-ase) enzyme activity in the mitochondria of rat's liver (Table 4 and Figures 6, 7, 8, 9) by AFs toxicity, such enzyme reaction could be reduced by white ginseng administration parallel to the aflatoxicosis. The rapid conversion of succinate to fumarate (through the tricarboxylic acid cycle) by activation of the SDH-ase may reduce the haemoglobin synthesis with consequent occurrence of anemia (Stroev, 1986).

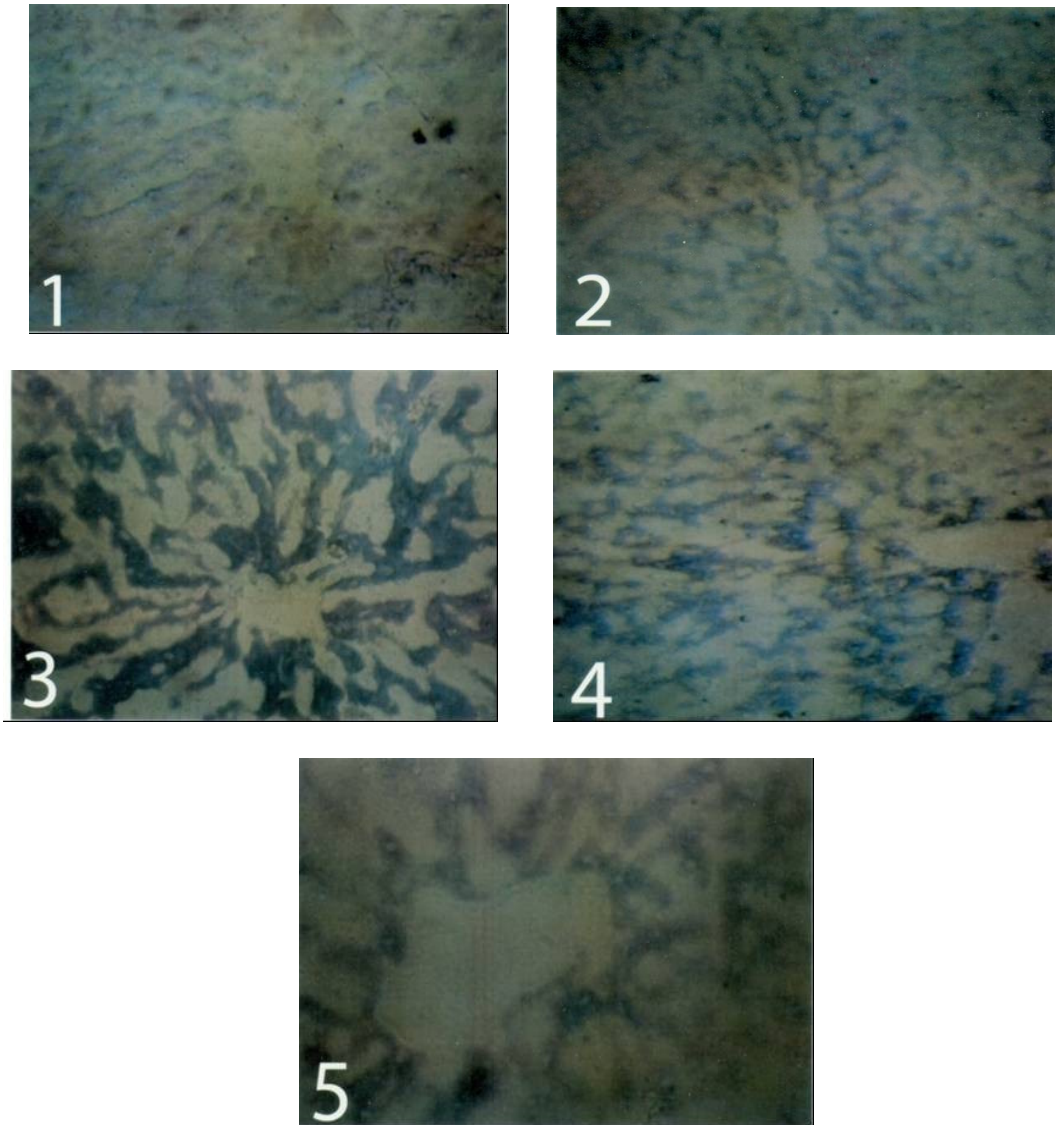


Fig.1 Cryostat section of liver of control rat (group 1) showing ++± (G6PD-ase) enzyme activity as bluish violet diformazan pigment in the hepatocytes(X200).

Fig.2 Cryostat section of liver of (group 2) which was administered with ginseng (2%) after 4 weeks showing +++± (G6PD-ase) enzyme activity as bluish violet diformazan pigment in the hepatocytes of centrilobularly region (X200).

Fig.3 Cryostat section of liver of (group 3) which was administered with Afs after 4 weeks showing +++++ (G6PD-ase) enzyme activity as dark bluish violet diformazan pigment in the hepatocytes (X400).

Fig.4 Cryostat section of liver of (group 4) which was administered with AFs and ginseng (1%) after 4 weeks showing ++++ (G6PD-ase) enzyme activity as dark bluish violet diformazan pigment in the hepatocytes of centrilobularly region (X400).

Fig.5 Cryostat section of liver of (group 5) which was administered with AFS and ginseng (2%) after 4 weeks showing ++± (G6PD-ase) enzyme activity as bluish violet diformazan pigment that centrilobularly located (X400).

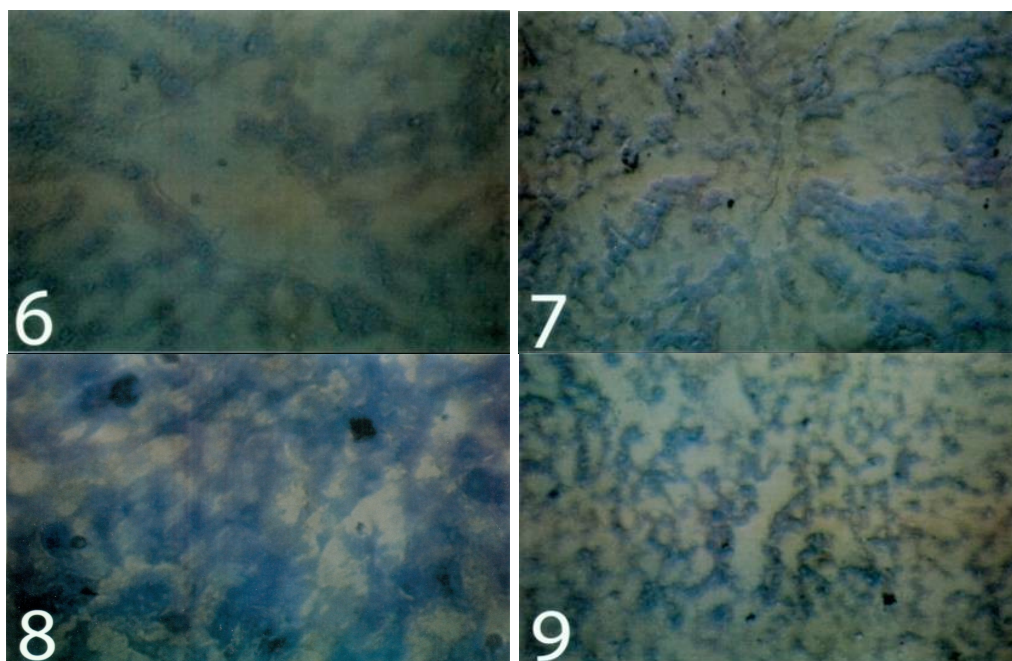


Fig.6 Cryostat section of liver of control rat (group 1) showing ++ (SDH-ase) enzyme activity as violet diformazan pigment in the hepatocytes(X400).

Fig.7 Cryostat section of liver of (group 2) which was administered with ginseng (2%) after 4 weeks showing +++ (SDH-ase) enzyme activity as violet diformazan pigment in the hepatocytes (X400).

Fig.8 Cryostat section of liver of (group 3) showing +++++ (SDH-ase) enzyme activity as dark bluish violet diformazan pigment in the hepatocytes (X400).

Fig.9 Cryostat section of liver of (group 5) which was administered with AFS and ginseng (2%) after 4 weeks showing +++ (SDH-ase) enzyme activity as dark bluish violet diformazan pigment in the hepatocytes of centrilobularly region (X200).

Table.1 Determination of ginsenosides in white ginseng roots using HPLC

Components of ginsenosides	Concentrations, mg/gm ginseng
Rb1	9.45
Rb2	0.07
Rc	1.77
Rd	3.02
Re	3.14
Rg1	0.26
Rg2	0.13
Unknown	3.4
Unknown	3.96

Data in Table 1 showed that Rb1 compound was the predominant identified ginsenoside (9.45 mg/gm) followed by Re (3.14 mg/gm) and Rd (3.02 mg/gm). While Rb2 and Rg2 had the lowest value of 0.07 and 0.13 mg/gm ginseng respectively.

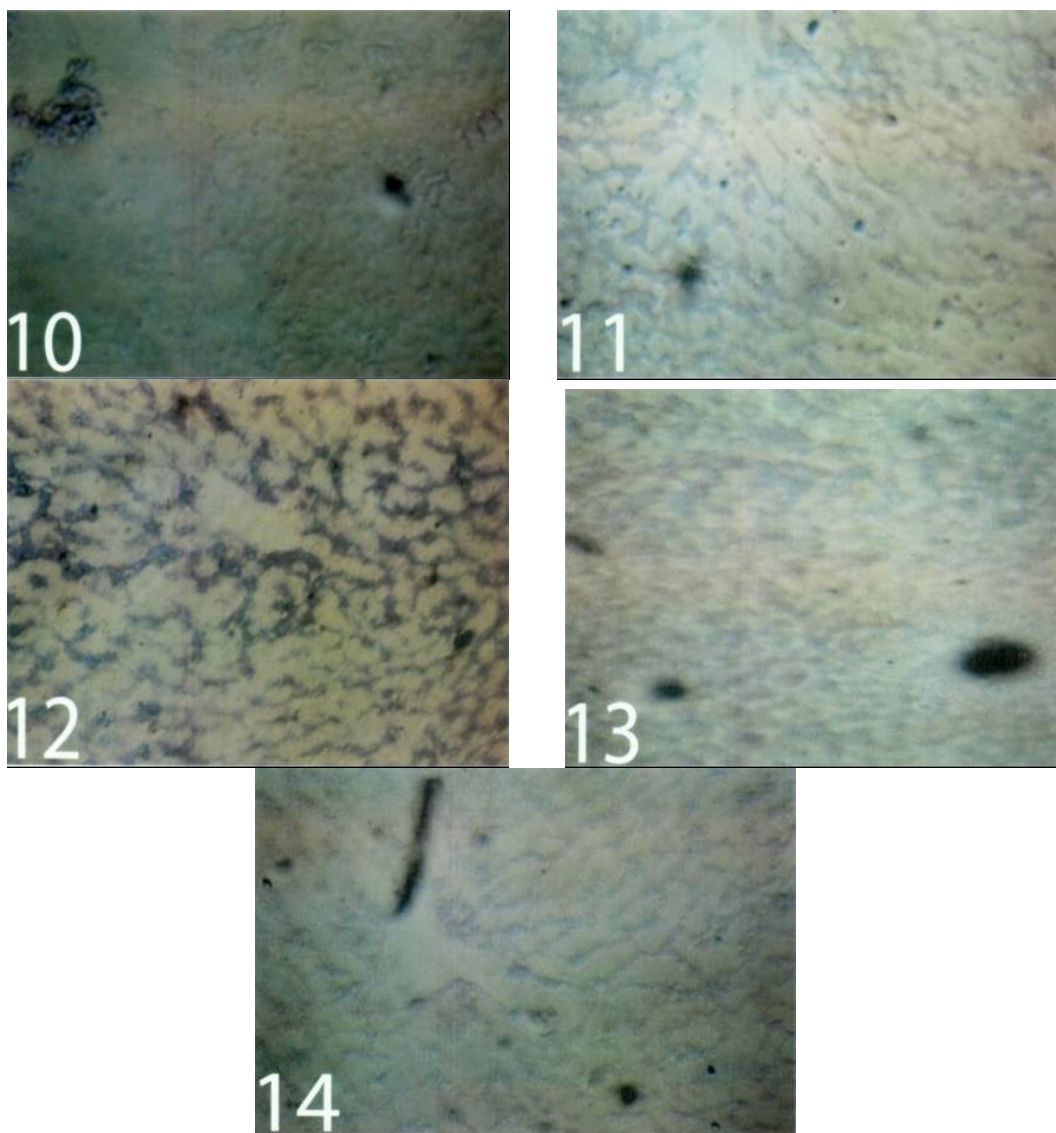


Fig.10 Cryostat section of liver of control rat (group 1) showing ++ (NADH-TR) or (NADH-Diaphorase) enzyme activity as violet diformazan pigment in the hepatocytes(X200).

Fig.11 Cryostat section of liver of (group 2) which was administered with ginseng (2%) after 4 weeks showing +++ (NADH-Diaphorase) enzyme activity as violet diformazan pigment in the hepatocytes (X200).

Fig.12 Cryostat section of liver of (group 3) which was administered with AFS after 4 weeks showing +++++ (NADH-Diaphorase) enzyme activity as dark violet diformazan pigment all over the hepatocytes and centrilobularly concentrated (X200).

Fig.13 Cryostat section of liver of (group 4) which was administered with AFS and ginseng (1%) after 4 weeks showing +++(NADH-Diaphorase) enzyme activity as violet diformazan pigment in the hepatocytes (X200).

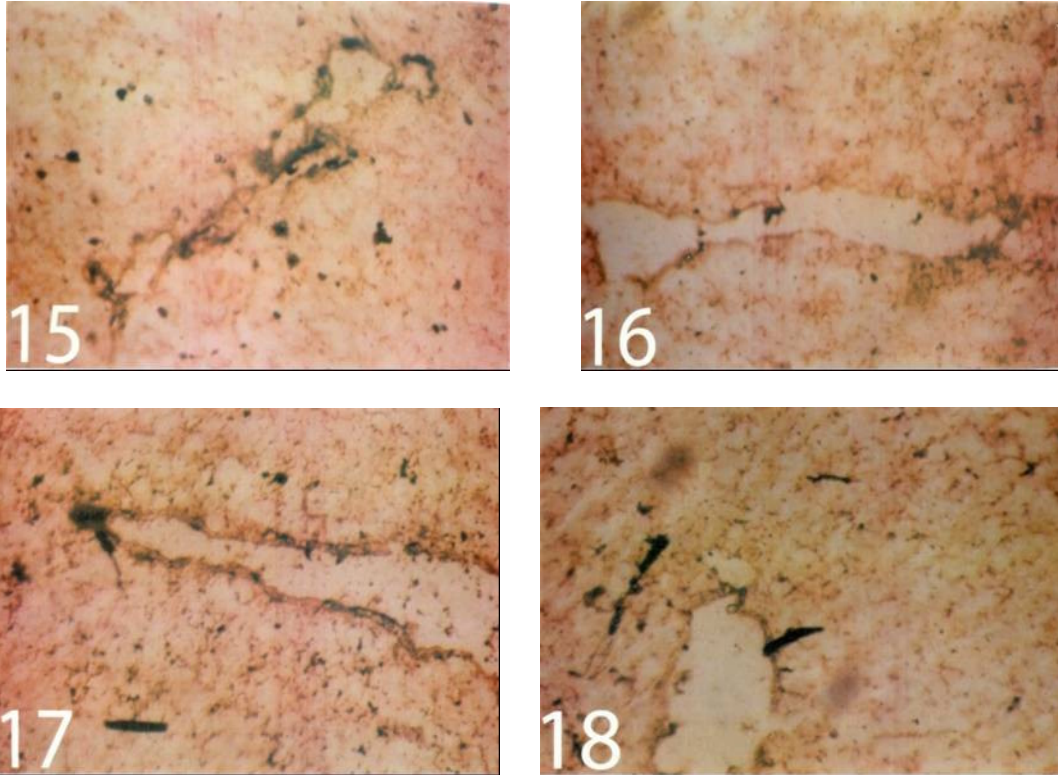


Fig.15 Cryostat section of liver of control rat (group 1) showing ++± (ATP-ase) enzyme activity (Mg^{+2} -activated, lead method) as brown to black-brown ppt of lead sulphide all over the hepatocytes and concentrated centrilobularly (X400).

Fig.16 Cryostat section of liver of (group 2) which was administered with ginseng after 4 weeks showing +++ (ATP-ase) enzyme activity as dark brown to blackish-brown ppt of lead sulphide all over the hepatocytic cells (X400).

Fig.17 Cryostat section of liver of (group 3) which was administered with AFS after 4 weeks showing ++++ (ATP-ase) enzyme activity as coarse granules of lead sulphide ppt all over the hepatic tissue (X400).

Fig.18 Cryostat section of liver of (group 5) which was administered with AFS and ginseng (2%) after 4 weeks showing ++± (ATP-ase) enzyme activity as fine to coarse dark brown ppt of lead sulphide in the hepatocytes (X400).

Table.2 Effect of dietary aflatoxin and white ginseng roots on liver functions (AST and ALT)

Items	Means±SE			
	AST(IU/L)		ALT(IU/L)	
Groups	Zero time	After 28 days	Zero time	After 28 days
Group 1	20.7±0.73 ^{Aa}	22.8±1.12 ^{Aa}	13.3±0.58 ^{Aa}	14.3±0.80 ^{Aa}
Group 2	21.01±1.08 ^{Aa}	27.07±0.69 ^{Aa}	12.9±0.48 ^{Aa}	17.02±1.05 ^{Aa}
Group 3	20.0±0.68 ^{Aa}	85.4±2.98 ^{Cb}	13.3±0.42 ^{Aa}	49.01±1.90 ^{Cb}
Group 4	20.03±1.07 ^{Aa}	76.27±2.85 ^{Cb}	13.3±0.29 ^{Aa}	32.4±1.136 ^{Bb}
Group 5	19.6±0.76 ^{Aa}	40.8±1.46 ^{Bb}	13.1±0.36 ^{Aa}	25.5±1.21 ^{Bb}
LSD≤ 0.05	10.03		7.5	

Notes:

The same capital letters in columns denotes no significant difference between treatments in the same period at (p≤0.05) and vice versa. But the difference in small letters in rows denotes significant difference between periods in the same treatment and the same parameter, at (p ≤ 0.05) and vice versa.

Table.3 Effect of dietary aflatoxin and white ginseng roots on kidney functions (Urea and Creatinine)

Items	Means±SE			
	Urea(mg/dl)		Creatinine (mg/dl)	
Groups	Zero time	After 28 days	Zero time	After 28 days
Group 1	42.06±2.43 ^{Aa}	48.8±2.33 ^{Aa}	37.7±2.45 ^{Aa}	39.8±3.37 ^{Aa}
Group 2	44.07±2.83 ^{Aa}	45.6±2.85 ^{Aa}	38.7±2.94 ^{Aa}	43.6±3.01 ^{Aa}
Group 3	44.2±1.649 ^{Aa}	96.4±5.43 ^{Cb}	40.2±3.16 ^{Aa}	109.9±5.19 ^{Cb}
Group 4	43.3±2.28 ^{Aa}	77.00±3.16 ^{Bb}	37.12±2.22 ^{Aa}	91.1±4.21 ^{Bb}
Group 5	46.96±2.08 ^{Aa}	56.5±3.03 ^{Bb}	40.9±1.49 ^{Aa}	60.30±3.31 ^{Bb}
LSD≤ 0.05	9.67		11.53	

Notes: The same capital letters in columns denotes no significant difference between treatments in the same period at (p≤0.05) and vice versa. But the difference in small letters in rows denote significant difference between periods in the same treatment and the same parameter, at (P≤ 0.05) and vice versa.

Table.4 The histochemical demonstration of some liver mitochondrial enzymes semi quantitatively estimated

Enzymes	G6PD-ase enzyme	SDH-ase enzyme	NADH-ase Diaphorase enzyme	ATP-ase Mitochondrial enzyme
Groups				
Group 1	++±	++	+±	++±
Group 2	+++±	+++	++±	+++
Group 3	+++++	+++++	+++++	++++
Group 4	++++	+++±	+++	+++
Group 5	++±	+++	++±	++±

Notes:

± = traces of enzyme activity, + = weak of enzyme activity, ++ = weak to submoderate of enzyme activity, +++ = submoderate to moderate of enzyme activity, ++++ = moderate of enzyme activity, +++ ± = moderate to strong of enzyme activity, ++++ = strong of enzyme activity, ++++± = strong to intense of enzyme activity and ++++ = intense.

The NADH-diaphorase enzyme mostly activated by AFs –intoxicated rats, but white ginseng could reduce such enzyme activation through its antioxidant activity especially with 2% concentration (Table 4 and Figures 10, 11, 12, 13, 14). Two enzymes: superoxide dismutase and NADH-diaphorase are known respectively for inhibiting the auto-oxidation of haemoglobin to met-haemoglobin and for reducing the met-haemoglobin to the functional haemoglobin (Manwell, 1977). The plasma membrane NADH-diaphorase affect cell growth and its differentiation and is modulated at various phases of cell cycle (Zurbriggen and Dreyer 1996).

Figure 14 Cryostat section of liver of (group 5) which was administered with AFS and ginseng (2%) after 4 weeks showing ++± (NADH-Diaphorase) enzyme activity as violet diformazan pigment in the hepatocytes (X200).

The current work demonstrated that the aflatoxicosis strongly activate the

mitochondrial ATP-ase (Table 4 and Figures 15, 16, 17, 18) and such toxic effect in rat’s liver could partially reduced by parallel treatment of rats with white ginseng (especially with 2gm / kg contaminated ration concentration), on the other side, such aflatoxicosis reduced the body weight of rats and such side effect could be treated by administration of white ginseng. The decrease in body weight may related to the loss of high energy compound (ATP) through its hydrolysis by ATP-ase activation by the uncoupling of oxidative phosphorylation by the uncoupler’s compounds such as dinitrophenol and glyphosate herbicide (Olorunsogo *et al.*, 1979). So that the AFs should be considered as one of the uncoupler’s compounds to the oxidative phosphorylation as one of the mode toxic actions.

Acknowledgements

The authors would like to acknowledge all members of mycotoxin Lab., Prof.Dr. Yahia H. Abu Sree, Dr.Mohamed Bedier,

Dr. Gommaa Nour El-Dein and Mr. Esam Mahmoud; National Research Centre, Cairo, Egypt; for their sincere help and hard efforts to finish this work.

References

- Abdel-Fattah, Sh. M., Sanad, M.I., Safaa, M.A., Ragaa, F.F., Ghanem. 2010. The Protective Effect of White Ginseng against Biochemical and Pathological Changes Induced by Aflatoxins in Rats. *J. Am. Sci.*, 6 (12): 461–472.
- Abdel-Fattah Sh. M., 2002. The efficacy of liccorice roots on both mould growth and aflalatoxin production. *J Agric., Sci., Mansoura Univ.*, 27(12): 2855–2868.
- Abdel-Fattah, Sh. M., Abu Sree, Y.H., El-Deeb, M.K., El-Bealawy, A.M., Helal, A.D. 2006. Toxicological studies on leucaena meal with two different dietary supplementation, on growth pwerformance and appreciable residues of its toxic constituents (Mimosine and 3, 4-DHP) in milk of Egyptian goats. *J. Egypt. Vet. Med. Assoc.*, 66(2): 83–99.
- Abdel-Wahhab, M.A., Ahmed, H.H. 2004. Protective effects of Korean Panax ginseng against chromium VI toxicity and free radical generation in rats. *J. Ginseng Res.*, 28:11–17.
- Abu-Seif Feryala, A., Abdel-Fattah, Sh. M., Abo Sree, Y.H., Shaaban, H.A., Ramadan, M. Manal. 2009. Antifungal properties of some medicinal plants against undesirable and mycotoxin-producing fungi. *J. Agric. Mansuora Univ.*, 34(3): 1745–1756.
- Andallu, B., Vardacharyulu, N., 2001. Effect of mulberry leaves on diabetes. *Int. J. Diab. Dev. Countries*, 21: 147–151.
- Anong, B., Suparat, K. 2006. Effect of dietary calcium propionate on performance, hepatic enzyme activities and aflatoxin residues in broilers fed a diet containing low level of aflatoxin B1. *J. Toxican*, 47: 41–46.
- AOAC, 2000. Official Method of Analysis. Natural Toxins, 17th edn., vol. 2., No. 990.33: Association of Official Analytical Chemist, Gaithersburg, MD, USA, Pp. 20–22..
- Attele, A.S., Wu, J., Yuan, C.S., 1999. Ginseng pharmacology: multiple constituents and multiple actions. *Biochem. Pharmacol.*, 58: 1685–1693.
- Biing-Hui, L., Feng-Yih, Y., Ming-Huan, C., Yi-Ling, Y. 2002. The effects of mycotoxins, fumonisin B and aflatoxin B1 on primary swine alveolar macrophages. *J. Toxicol Appl. Pharm.*, 180: 197–204.
- Cohen, S., Way S. 1966. Histochemical determinations of pentose shunt activity in smears from the uterine cervix. *Br. Med. J.*, 1: 88–89.
- Ducan, D.B. 1955. Multiple ranges and multiple F. test. *Biometrics*, 11:10.
- Fenoglio, C., Grosso, A., Boncompagni, E., Milanese, G., Gandini, C., Barni, S. 2006. Morpho-functional evidence of changes in principal and mitochondrial rich cells in epidermis of the frog (*Rana kl. Esculenta*) living in a polluted habitat. *Arch. Environ. Contam. Toxicol.*, 51(4): 690–702.
- Frank, J.E., 2005. Diagnosis and management of Gulcose -6-phosphate dehydrogenase deficiency. *Am. Fam. Physician.*, 12(7): 1277–82.

- Gil, F., Fiserova-Bergerova, V., Altman, N.H. 1988. Hepatic protection from chemical injury by isofluorane. *Anesth. Analg.*, 67: 860–867.
- Hassal, E., Israel, D.M., Gunesakaran, T.M. 1990. Halothane hepatitis in children. *J. Pediatr. Gastroenterol. Nutr.*, 11: 553–557
- Joseph, G.S., Jayaprakasha, G.K., Selvi, A.T., Jena, B.S., Sakariah, K.K. 2005. Antiaflatoxic and antioxidant activities of Garcinia extract. *Int. J. Food Microbiol.*, 101: 153–160.
- Kim, H.J., Chun, Y.J., Park, J.D., Kim, S.I., Roh, J.K., Jeong, T.C. 1997. Protection of rat liver microsomes against carbon tetrachloride-induced lipid peroxidation by red ginseng saponin through cytochrome p450 inhibition. *Planta. Med.*, 63: 415–418.
- Ko, S.R., Choi, K.J., Kim, S.C., Kim, M. W. 1989. Contents of crude saponin and ginsenosides in white ginsengs. *Korean J Pharmacol.*, 20: 170–174.
- Kumar, R., Mishra, A.K., Dubey, N.K., Tripathi, Y.B. 2007. Evaluation of *Chenopodium ambrosioides* oil as a potential source of antifungal, antiaflatoxic and antioxidant activity. *Int. J. Food Microbiol.*, 115: 159.
- Li, S.D., Lu, Q., Fu, L. 1999. Investigation of natural ether roots constituents of *Panax ginseng* C.A.Meyer. *J. Chin. Med. Mater.*, 4: 31–33.
- Lind, R.C., Gandolfi, A.J., Hall, P.M. 1989. The role of oxidative biotransformation of halothane in the guinea pig model of halothane-associated hepatotoxicity. *Anesthesiol.*, 70: 649–653.
- Liu, S.J., Zhou, S.W. 2000. *Panax notoginseng* saponins attenuated cisplatin-induced nephrotoxicity. *Acta Pharmacol. Sin.*, 21(3): 257–265.
- Mannaa, F., Abdel-Wahhab, M.A., Ahmed, H.H., Park, M.H. 2006. Protective role of *Panax ginseng* extract standardized with ginsenoside Rg3 against acrylamide-induced neurotoxicity in rats. *J. Appl. Toxicol.*, 26: 198–206.
- Manwell, C., 1977. Superoxide dismutase and NADH-diaphorase in haemerythrocytes of spinulans. *Comp. Biochem. Physiol. B.*, 58(4): 331–338.
- Moos, O.M. 2002. Risk assessment for Aflatoxins in foodstuffs. *J. Int. Biodet. Biodeg.*, 50: 137–142.
- Moreira, M.R. 2005. Inhibitory parameters of essential oils to reduce a food borne pathogen. *LWT-Food Sci. Technol.*, 38: 565–570.
- Nachlas, M.M., Tsou, K.C., de Souza, E., Chang, C.S. 1957. Histochemical determination of succinic dehydrogenase by one of a new p-nitro phenyl substituted ditetrazole. *J. Histochem. Cytochem.*, 5: 420–436.
- Nachlas, M.M., Walker, D.G., Seligman, A.M.A. 1958. Histochemical method for the determination of diphosphopyridine nucleotide Diaphorase. *J. Biophys. Biochem.*, 4: 29–38.
- Necerino, E., Amato, M., Izzo, A.A. 2000. The aphrodisiac and adaptogenic properties of ginseng. *Fitoterapia*, 71(1 Suppl): 51–5.
- Olorunsogo, O.O., Bababunme, E.A., Bassir O. 1979. Effect of glyphosate on rat liver mitochondria. In vivo. *Bull. Environ. Contamin. Toxicol.*, 22: 357–364.
- Ozer, J., Ratner, M., Shaw, M., Bailey, W., Schomaker, S. 2008. The current state of serum biomarkers of

- hepatotoxicity. *Toxicol.*, 245: 194–205.
- Patrick, J., Terry, R., Van Vleet, J., Hall, R., Colombe, Jr. 2002. Biochemical factors underlying the age related sensitivity of turkeys to aflatoxins B₁. *J. Comp. Biochem. and Phys. Part C*, 132: 193–201.
- Patton, C.J., Crouch, S.R. 1977. Enzymatic determination of urea. *Anal. Chem.*, 49: 464–469.
- Pearse, A.G.E. 1972. *Histochemistry (Theoretical and Applied)*, Vol. 2, London: Churchill Livingstone.
- Rao, K.S.P., Rao, K.V.R., 1987. The possible role of glucose-6-phosphate dehydrogenase in detoxification of methyl parathion. *Toxicol. Lett.*, 39(2-3): 211–214.
- Rati, E.R., Shantha, T., Ramesh, H.P. 1991. Effect of long term feeding and withdrawal of AFB₁ and ochratoxin A on kidney cell transformation in Albino rats. *Indian J. Exp. Biol.*, 29: 813–817.
- Reitman, S., Frankel, S. 1957. Colorimetric methods for determining GOT and GPT. *Amer. J. Clin. Path.*, 28: 56–63.
- Rudakewich, M., Ba, F., Benishin, C.G. 2001. Neurotrophic and neuroprotective actions of ginsenosides Rb₁ and Rg₁. *Planta Medica.*, 67: 533–537.
- Saad, M.M. 1993. Preliminary study on formulation and application of aflatoxins(s) – antidote. *J. Vet. Med., Giza*, 41(1): 33–37.
- Saad, M.M., Abdel-Fattah, Sh. M. 2008. Food additive formula to minimize the negative effects due to ingesting aflatoxins contaminated food. *J. Saudi Soc. Food Nutr.*, 3(1): 17–31.
- Sheehan, D., Harapcbak, B. 1980. *Theory and practice of histotechnology*, 2nd Edn. Mosby Co., London, USA.
- Sherif, S.O., Salama, E.E., Abdel-Wahhab, M.A. 2009. Mycotoxins and child health: the need for health risk assessment. (Review) *Int. J. Hyg. Environ. Health*, 212: 347–368.
- Shotwell, O.L., Hesseltine, C.W., Stubblefield, R.D., Sorenson, W.G., 1966. Production of aflatoxin on rice. *Appl. Microbiol.*, 14: 425–428.
- Snedecor, G.W., Cochran, W.G. 1966. *Statistical Methods*, 6th Edn. IOWA State University Press, Ames., IOWA.
- Stroev, R.L. *Biochemistry*, English translation, Mir Publisher, Moscow.
- Teppema, L.J., Nieuwenhuijs, D., Sarton, E., Romberg, R., Olievier, N.C., Ward, D.S., Dahan, A. 2002. Antioxidants prevent depression of the acute hypoxic ventilatory response by subanaesthetic halothane in men. *J. Physiol. (London)*, 1986, 544: 931–938.
- Tanaka, O., Kasai, R. 1984. Saponins of ginseng and related plants. In: Herz, W., Grisebach, H., Kirby, G.W., Tamm, Ch. (Eds.), *Progress in the Chemistry of Organic Natural Products*, Vol. 46. Springer- Verlag, Berlin, Pp. 1–76.
- Teppema, L.J., Nieuwenhuijs, D., Sarton, E., Romberg, R., Olievier, N.C., Ward, D.S., Dahan, A. 2002. Antioxidants prevent depression of the acute hypoxic ventilatory response by subanaesthetic halothane in men. *J. Physiol. (London)*, 544: 931–938.
- Tulayakul, P., Sakuda, S., Dong, K., Kumagai, S. 2005. Comparative activities of glutathione-s-transferase and dialdehyde reductase towards aflatoxin B₁ in livers of experimental and farm animals. *J. Toxic.*, 46: 204–209.

- Wachstein, M., Meisel, E. 1957. Histochemistry of hepatic phosphatases at a physiologic pH with special reference to the demonstration of bile canaliculi. *Am. J. Clin. Pathol.*, 27:13–23
- Wang, Y., You, J., Yu, Y., Chenling, Q., Zhang, H., Ding, L., Zhang, H., Li,,X. 2008. Analysis of ginsenosides in *Panax ginseng* in high pressure microwave – assisted extraction. *Food Chemi.*, 110: 161–167.
- WHO, 1981. Environmental health criteria for mycotoxins, World Health Organization, Vol. 11. WHO, Geneva.
- Yeong-Hsiang, C., Tian-Fuh, S., Victor, F., Bao-Ji, C. 2001. Effects of aflatoxin and carotenoids on growth performance and immune response in ducklings. *J. Comp. Biochem. Phys., Part C*, 128: 19–26.
- Yokozawa, T., Liu, Z.W. 2000. The role of ginsenoside-Rd in cisplatin-induced acute renal failure. *Ren. Fail.*, 22 (2): 115–127.
- Yokozawa, T., Zhou, J.J., Hattori, M., Inaba, S., Okada, T., Oura, H. 1994. Effects of ginseng in nephrectomized rats. *Biol. Pharm. Bull.*, 17(11): 1485–1489.
- Zurbriggen, R., Dreyer, J.L. 1996. The plasma membrane NADH-diaphorase is active during selective phases of the cell cycle in mouse neuroblastoma cell line NB41A3: its relation to cell growth and differentiation. *Biochem. Biophys. Acta*, 1312(3): 215–222.