

## Original Research Article

# Effect of Ascorbic Acid on Histopathology during Cryopreservation of Buffalo Bull Epididymis

Saurabh<sup>1</sup>, Sushant Srivastava<sup>1</sup>, Rajesh Kumar Verma<sup>2</sup>,  
Shailendra Verma<sup>1</sup>, Anand Kumar<sup>1</sup> and Vikas Chaudhary<sup>1</sup>

<sup>1</sup>Department of Veterinary Gynaecology and Obstetrics, <sup>2</sup>Teaching Veterinary Clinical Complex, College of Veterinary Science and Animal Husbandry, Narendra Deva University of Agriculture and Technology, Kumarganj Faizabad, India

\*Corresponding author

## ABSTRACT

Cryopreservation of epididymal spermatozoa from accidentally dead animal and use of this germplasm by artificial insemination are the good options for the propagation of this breed of animal. Successful cryopreservation of the epididymal spermatozoa of murrh bull needs suitable cryo-diluent capable of protecting sperm from cryo-damage. During cryopreservation buffalo bull spermatozoa are more susceptible to oxidative damage as compared to cattle bull spermatozoa. Antioxidants have an important role in maintaining the motility and the genetic integrity of sperm cells against oxidative damage. Ascorbic acid (vitamin C) may act as an oxidant at low concentrations and as an antioxidant at high concentrations. Ascorbic acid increases the percentage of live, an acrosome intact spermatozoa during storage at 5°C. Ascorbic acid is a very efficient antioxidant and a scavenger of oxygen free radicals which are toxic products of many metabolic processes that observation also shows that addition of antioxidants such as ascorbate and alfa-tocopherol to dilutors improves sperm quality by exerting protective effect on both metabolic activity and cellular viability of frozen bovine semen. The role of ascorbic acid was studied by histopathological examination of epididymal cells which prevents architectural and internal losses of cells during cryopreservation.

### Keywords

cryopreservation,  
Ascorbic acid,  
Epididymal cells,  
Spermatozoa

## Introduction

Epididymis consists of caput, corpus and cauda. Caput and corpus plays a role in maturation of spermatozoa while caudal epididymis has function to preserve spermatozoa (Ashdown and Hancock, 1980). After the death of animal, spermatozoa in male and oocyte in female remain alive for a period of time. The fertility of the spermatozoa taken from cauda epididymis is more or less the same as spermatozoa from the ejaculate (Hafez and Hafez, 2000). If those gametes are recovered

and used to produce embryos by assisted reproductive technique is possible to have progeny even after animal are dead (Songsasen *et al.*, 1998). The recovery and freezing of viable sperm from epididymis of dead animal (post-mortem recovery) is an interesting option for preserving male gamete and thus for maintaining germplasm banks. This process has been reported in dog (Marks *et al.*, 1994), rabbit (Pauffler and Foote, 1968), and buffalo bull (Chaudhari, 2015).

Yu and Leibo (2002) in canine, James *et al.* (2002) in equine, have successfully recovered motile and membrane intact spermatozoa from epididymis stored for 8 days at 4°C. James *et al.* (2002) had successfully recovered motile and membrane intact spermatozoa from epididymis stored at 4°C for 24, 48, 72, and 96 hours in equine. Cryopreservation of epididymal spermatozoa from accidentally dead animal and use of this germplasm by artificial insemination are the good options for the propagation of this breed of animal. Successful cryopreservation of the epididymal spermatozoa of murrah bull needs suitable cryo-diluent capable of protecting sperm from cryo-damage. During cryo-preservation buffalo bull spermatozoa are more susceptible to oxidative damage as compared to cattle bull spermatozoa (Nair *et al.*, 2006; Kumaresan *et al.*, 2005, 2006). It is believed that this difference is due to higher contents of polyunsaturated phospholipids present in plasma membrane of buffalo bull spermatozoa (Sansone *et al.*, 2000). Freezing process accelerate the production of ROS molecules which may decrease the viability of buffalo bull spermatozoa during storage (Kumaresan *et al.*, 2005; 2006; Garg *et al.*, 2008).

When non enzymatic antioxidants like ascorbic acid (vitamin C) and vitamin E are added in semen diluters or in livestock feed which inhibit the production of ROS. Some reports indicated that the addition of ascorbic acid and vitamin E to animal feeds could reduce the production of ROS and raise the quality of sperm (Fraga *et al.*, 1991; Akiyama, 1999; Li *et al.*, 2010). Ascorbic acid (vitamin C) may act as an oxidant at low concentrations and as an antioxidant at high concentrations (Affranchino *et al.*, 1991; Breininger *et al.*, 2005).

Ascorbic acid increases the percentage of live, an acrosome intact spermatozoa during storage at 5°C. Ascorbic acid is a very efficient antioxidant and a scavenger of oxygen free radicals which are toxic products of many metabolic processes (Dawson *et al.*, 1992) that observation also shows that addition of antioxidants such as ascorbate and alfa-tocopherol to dilutors improves sperm quality by exerting protective effect on both metabolic activity and cellular viability of frozen bovine semen (Beconi *et al.*, 1993 and O'Flaherty *et al.*, 1997). Singh and Bharadwaj (1980) in one humped camel and Bacha and Bacha (2000) in sheep & goat reported that testis consists of seminiferous tubules, interstitial cell, connective tissue whereas seminiferous tubule containing different stages of spermatogenic cell, sertoli cell and iniferous lumen. Interstitial cell secrete androgen which help in sperm maturation and development of sexual character in male animal. Sertoli cell are larger cells that rest on the basal lamina and extend upward through the full thickness of epithelium to the free surface at the lumen. The epididymal duct is lined by a pseudostratified ciliated columnar epithelium and surrounded by circular smooth muscles layer. The height of the epithelium varies between the different segments of the epididymal duct; the highest epithelium is seen in the initial segment and decreases gradually towards terminal segment. The histometric measures of epididymis showed that diameter of ductile lumina tail epididymis tubules decreased in hot months, in August, July and December, this decrease in diameter of ductile lumina tubules a companied by a decrease in thickness of seminiferous tubules in the same months in August. (Arrighi *et al.*, 2010 and Al- Sahaf and Ibrahim. 2012). Ibrahim *et al.*, (2014) observed that the increased in diameter of ductile lumina tail of epididymis

is a result of filling the tubules with semen these demonstrated in moderate temperature and sun shine months which have high activity of the testes and good semen physical characteristics. He also reported that during the mating season the lumina might possibly enlarge under the pressure of sperm accumulation, and the epithelium increased its functional role. For the same reason, the organ may be possibly augmented in weight during the mating season.

### **Materials and Methods**

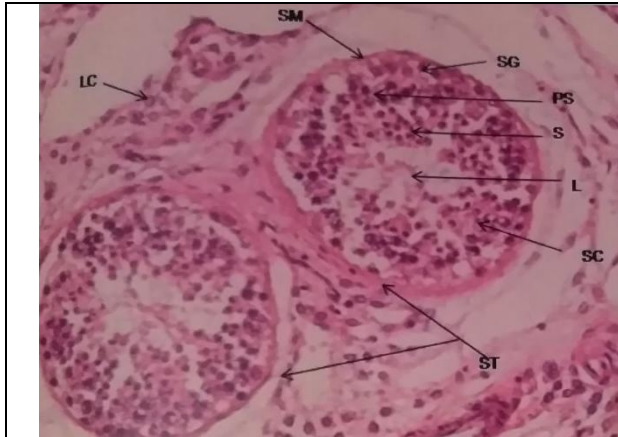Forty (40) pairs of buffalo bull testis were collected from Arora (AOV Ltd.) and Mass agro food Pvt. Ltd. located at Unnao, Uttar Pradesh. The testicles were immediately brought to the laboratory of Department of Veterinary Gynaecology and obstetrics, College of Veterinary Science and Animal Husbandry, Narendra Deva University of Agriculture and Technology, Kumarganj Faizabad and covered in airtight sterile cryobox (40C) and were processed within 6 hrs after collection. Forty pairs (40) of testis were divided into five groups (T<sub>0</sub>, T<sub>1</sub>, T<sub>2</sub>, T<sub>3</sub> & T<sub>4</sub>) and each group contain eight pairs testis. Cyto-morphological characteristics of epididymal semen of 8 pairs (T<sub>0</sub>) of testis were estimated within 6 hrs of collection from abattoir, remaining 32 pairs (n=8, 4 groups) were cleaned, separated epididymal part and further, ligated the cauda part of epididymis. Infused tris buffer saline in 16 pair of epididymis and 8 pair were stored at 40C (T<sub>1</sub>) and remaining were placed at -196 0C (T<sub>3</sub>). Similarly, tris dilutor with ascorbic acid was infused inside the remaining ligated epididymal part cauda and stored at 40C (T<sub>2</sub>) and -196 0C (T<sub>4</sub>). Epididymis of each groups were wrap separately with aluminum foil and stored at their respective temperature 40C group (T<sub>1</sub> & T<sub>2</sub>), and -196 0C group (T<sub>3</sub> & T<sub>4</sub>).

Testis were flushed with cold normal saline and then fixed by complete immersion in 10% neutral buffered formalin, labeled and kept for two days, followed by preservation in 70% ethyl alcohol. They were dehydrated ascending grade of ethanol (50%, 70%, 95% and absolute alcohol), cleared in xylene and embedded in paraffin wax. Blocks were prepared and 4µm were sections cut by sledge microtome. The paraffin embedded section were deparaffinised, washed and stained with haematoxylin and eosin (H& E) the stained slides were examined under light microscope.

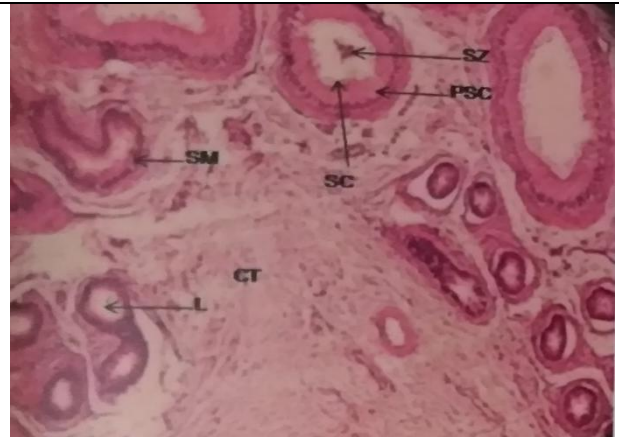
### **Results and Discussion**

Histology of testis was consists of seminiferous tubules and interstitial cell. Seminiferous tubule containing different stages of spermatogonic cell, sertoli cell and seminiferous lumen. Our histologicals picture was similar to finding of Singh and Bharadwaj (1980) in one humped camel and Bacha and Bacha (2000) in sheep & goat (Fig-4.9).

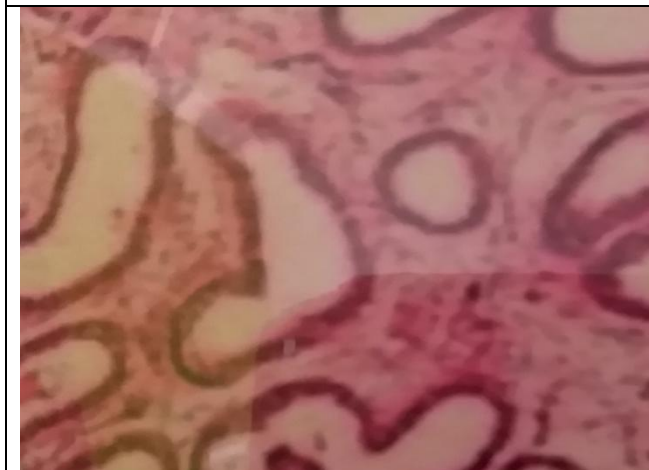The epididymis group of T<sub>0</sub>, T<sub>1</sub>, T<sub>2</sub>, T<sub>3</sub> and T<sub>4</sub> is covered by two layered pseudo stratified epithelium in caput, corpus and cauda. The sperm are showed in the lumen of cauda epididymis group T<sub>0</sub>, T<sub>1</sub>, T<sub>2</sub>, T<sub>3</sub> and T<sub>4</sub>. The epithelium is separated by basement membrane from the connective tissue wall which has smooth muscles cell. Main cell of epithelium was columnar cell that was extended from basal lamina towards the lumen of tubules. They have stereocillia which are long at head region (caput) and shorter at tail region (cauda). In group T<sub>0</sub> tubules were relatively more round, compacted, more thickness of interstitial tissues, columnar cell was tall, stereocillation number was more and expressed less degenerative changes as compared to group T<sub>1</sub>, T<sub>2</sub>, T<sub>3</sub> and T<sub>4</sub>.



**Fig.1** Histology of testis (T.S.) showing- Seminiferous Tubules(ST), Smooth Muscle (SM), Spermatogonia (SG), Primary Spermatocyte (PS), Spermatid (s), Sertoli Cell(SC), Leydig Cell (LC)



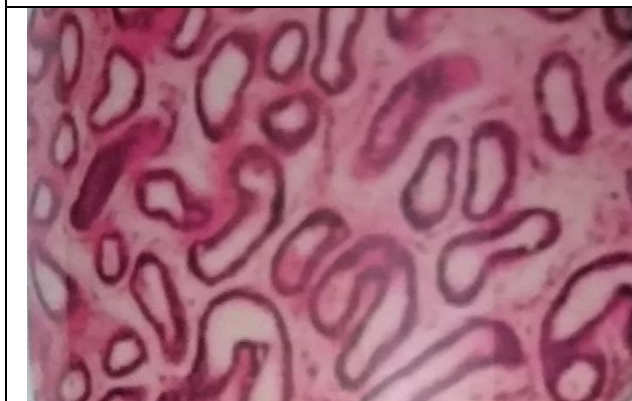**Fig.2** Histology of Caput Epididymis within 6 hrs of slaughter (group TO) showing- Smooth Muscle (SM), Pseudo stratified Columnar Epithelium (PSC), Stereocillia (SC), Lumen (L), Spermatozoa (SZ), Connective Tissue (CT)



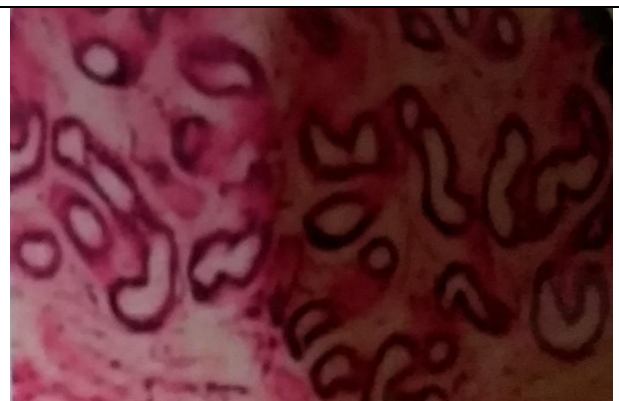**Fig.3** Histology of Caput Epididymis of group T1 stored at 4°C



**Fig.4** Histology of Caput Epididymis of group T2 stored at 4°C

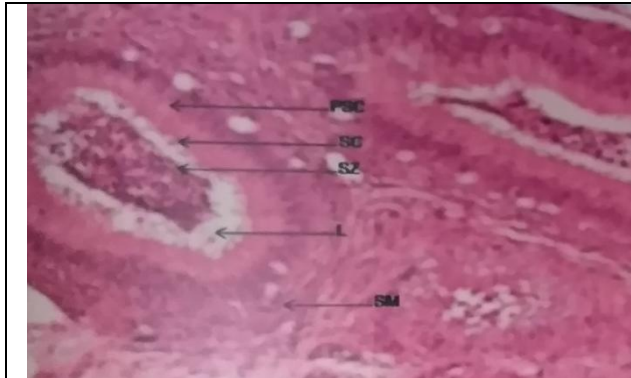


**Fig.5** Histology of Caput Epididymis of group T3 stored at -196°C.

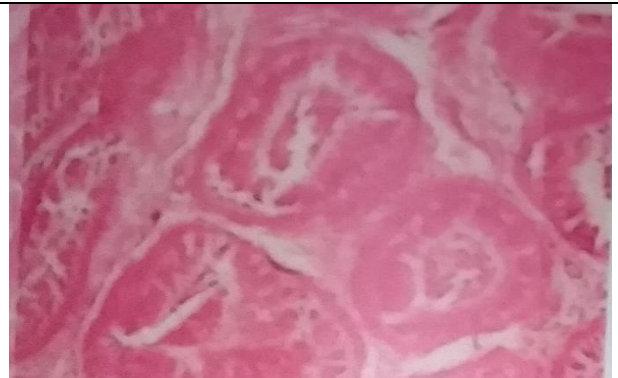

**Fig.6** Histology of Caput Epididymis of group T4 stored at -196°C

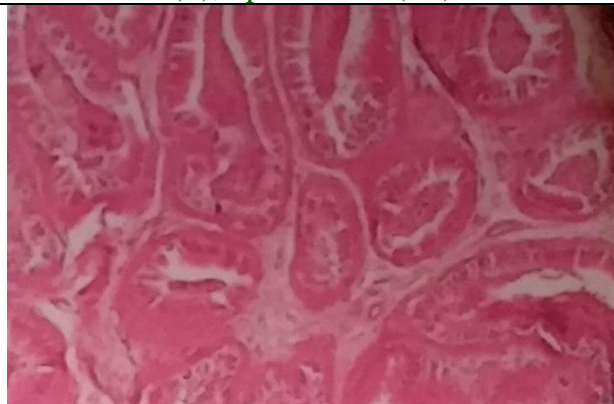



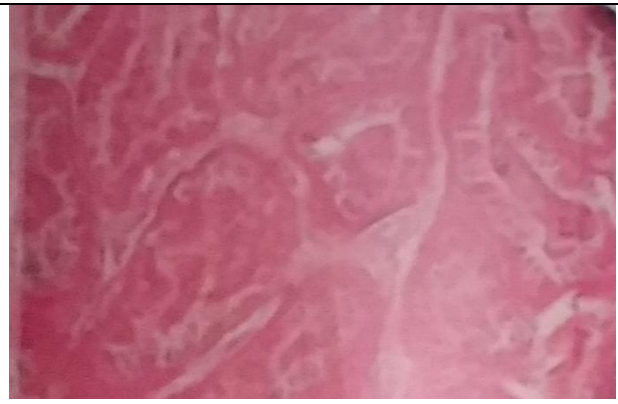
**Fig.7** Histology of Corpus Epididymis within 6 hrs of slaughter (group TO) showing- Smooth Muscle (SM), Pseudostartified Columnar Epithelium (PSC), Stereocillia (SC), Lumen (L), Spermatozoa(SZ)



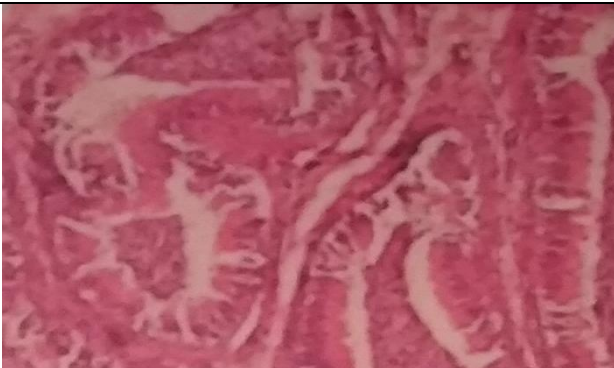**Fig.8** Histology of Corpus Epididymis of group T1 stored at 4°C



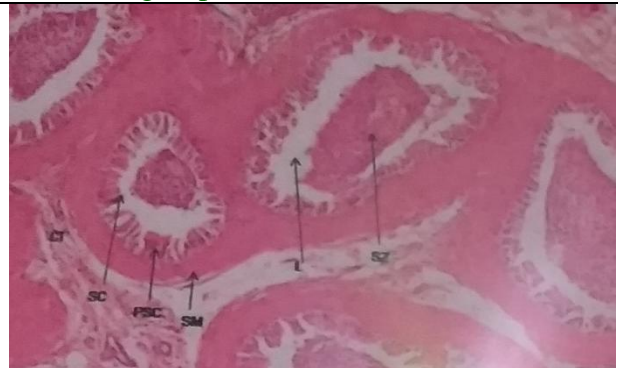**Fig.9** Histology of Corpus Epididymis of group T2 stored at 4°C



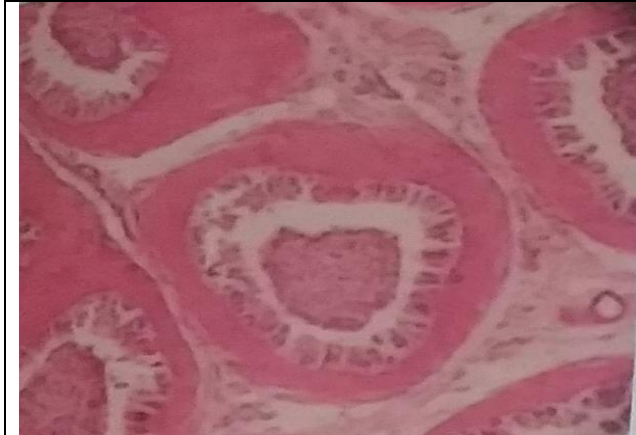**Fig.10** Histology of Corpus Epididymis of group T3 stored at -196°C



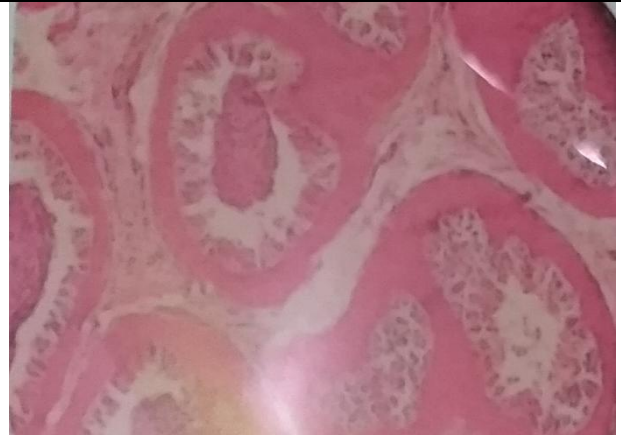**Fig.11** Histology of Corpus Epididymis of group T4 stored at -196°C



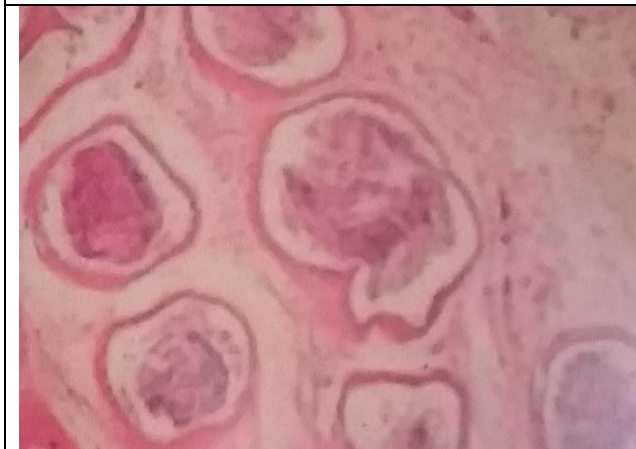**Fig.12** Histology of Cauda Epididymis within 6 hrs of slaughter (group TO) showing- Smooth Muscle (SM), Pseudostartified Columnar Epithelium (PSC), Stereocillia (SC), Lumen (L), Spermatozoa (SZ), Connective tissue(CT)



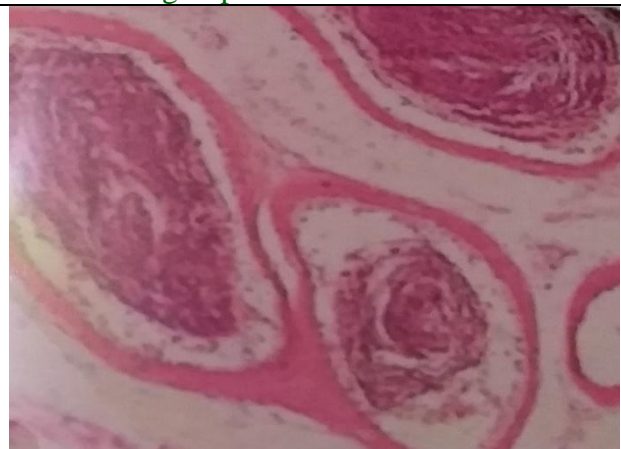
**Fig.13** Histology of Cauda Epididymis of group T1 stored at 4°C



**Fig.14** Histology of Cauda Epididymis of group T2 stored at 4°C



**Fig.15** Histology of Cauda Epididymis of group T3 stored at -196°C



**Fig.16** Histology of Cauda Epididymis of group T4 stored at -196°C

The tall columnar cells were become flattened and reduction in stereocillation number was observed in T<sub>3</sub> and T<sub>4</sub> group. Cryo-injury was more noticed in the epididymal stored at -196°C without any treatment in group T<sub>3</sub> as compared to T<sub>4</sub> group. Ascorbic acid had showed their potential antioxidant by normalizing such structure during storage of epididymis at 4°C and -196°C. Non-enzymatic antioxidant ascorbic acid (vitamin C) has been proposed as electron donor for some transplasma membrane redox systems and protect cell from ROS damages. No such type of research cited in available literature. Higher cryodamages was recorded in treatment T<sub>3</sub> and T<sub>4</sub> as compared to group T<sub>1</sub> and T<sub>2</sub> these

damages might be due to formation of ice crystal in extra and intracellular environment, increasing solute concentration (Mazur, 1984).(Fig- 4.10.1 to 4.12.5).

In conclusion, histopathological examination of epididymal cells which prevents architectural and internal losses of cells during cryopreservation.

#### **Acknowledgments**

The authors are thankful to Dean, College of Veterinary Science and Animal Husbandry, NDUAT, Kumarganj, Faizabad for providing the funding and facilities to carry out the work.

## References

- Affranchino, M., Trincherro, G., Schang, L. M. and Beconi, M. (1991). Bovine spermatozoa as lipoperoxidation inhibitor. *Corn. Biol.*, 9: 261-274.
- Akiyama, M. (1999). In vivo scavenging effect of ethylcysteine on reactive oxygen species in human semen. *Nihon Hinyokika Gakkai Zasshi*, 90: 421-428.
- Al- Sahaf, M.M.H. and Ibrahim, N.S. (2012). The effect of months on physical of sperms and morphological alterations in the testis and epididymis of Iraqi buffalo. MSc. Thesis. Vet. College University of Baghdad., Pp: 48-60.
- Arrighi, S., Bosi, G., Gropeptti, D. and Cremonesi, F. (2010). Morpho-and histometric evaluation on the testis and epididymis in buffalo bulls during different reproductive seasons .*The Open Anatomy J.*, 2: 29-33.
- Ashdown, R.R. and Hancock, J.L. (1980). Functional Anatomy of Male Reproduction. In: *Reproduction in Farm Animals*, E.S.E. Hafez (editor), 4th ed., Lea and Feb.
- Bacha, W.J. and Bacha, L.M. (2000). *Colour Atlas of Veterinary Histology*. (2nd edition). Philadelphia: Lippincott Williams and Wilkins.
- Beconi, M.T., Francia, C.R., Mora, N.G. and Affranchino, M.A. (1993) Effect of Natural Antioxidants on SOD Activity in Bovine Sperm. *Biochemistry International*, 23: 545-553.
- Breininger, E., Beorlegui, N.B., O'flaherty, C.M. and Beconi, M.T. (2005). Alpha-tocopherol improve biochemical and dynamic parameters in cryopreserved boar semen. *Theriogenology*, 63: 2126-2135.
- Chaudhary, A.K. (2015). Effect of different storage temperature on freezability of buffalo bull epididymal spermatozoa. M.V.Sc. thesis, N. D. U. A. & T. Kumarganj, Faizabad (U.P.) India.
- Dawson, E.B., Harris, W.A., Teter, M.C. and Powell, L.C. (1992). Effect of ascorbic acid supplementation on the sperm quality of smokers. *Fertil. Steril.*, 58: 1034-1039.
- Fraga, C.G., Motchnik, P.A., Shigenaga, M.K. and Helbock, H.J. (1991). Ascorbic acid protects against endogenous oxidative DNA damage inhuman sperm. *Proc. Natl. Acad. Sci. U. S. A.*, 88: 11003-11006.
- Hafez, E.S.E. and Hafez, B. (2000). *Reproduction in farm animal*. 7th Ed.
- Ibrrhem, N.S., Al-Sahaf, M.M.H. and Alwan, A.F. (2014). Reproductive activity of mature Iraqi bull buffaloes epididymis sperm quality and histological picture. *IOSR Journal of Agricultural and Veterinary Science*, 7(4): 56-62.
- James, A.H., Green, H., Hoffman, S., Landry, A.M., Paccamonti, D. and Godke, R.A. (2002). Preservation of equine sperm stored in epididymisat 4°C for 24, 48, 72 and 96 hours *Theriogenology*, 58: 401-408.
- Kumaresan, A., Ansari, M.R. and Garg, A. (2005). Modulation of post thaw sperm functions with oviductal proteins in buffaloes. *Anim. Reprod. Sci.*, 90: 73-84.
- Li, Z., Lin, Q., Liu, R., Xiao, W. and Liu, W. (2010). Protective effects of ascorbate and catalase on human spermatozoa during cryopreservation. *J. Androl.*, 31: 437-444.
- Marks, S.L., Dupuis, J., Mickelsen, W.D., Memon, M.A. and Platz, C.C.(1994). Conception by use of post-mortem epididymal semen extractionin a dog. *J.Amer.Vet. Med.Assoc.*, 204(10):1639-1640.
- Mazur, P. (1984). Freezing of living cell: mechanism and implications. *Am.*

- J.Physiol., 247: C125-C142.
- Nair, S.J., Brar, A.S., Ahuja, C.S., Sangha, S.P. and Chaudhary, K.C. (2006). A comparative study on lipid peroxidation, activities of antioxidant enzymes and viability of cattle and buffalo bull spermatozoa during storage at refrigeration temperature. *Anim. Reprod. Sci.*, 96: 21-29.
- O'Flaherty, C., Becani, M. and Berlegni, N. (1997). Effect of Natural Antioxidants, Super Oxide Demitasse and Hyper Oxide on Cap Citation of Frozen Thawed Bull Sperm. *Andrologia*, 29: 269-275.
- Pauffler, S.K. and Foote, R.H. (1968). Morphology, motility and fertility of spermatozoa recovered from different area of ligated rabbit epididymis. *J. Reproduction Fertil.*, 17: 125-137.
- Sansone, G., Nastri, M.J.F. and Fabbrocini, A. (2000). Storage of buffalo (*Bubalus bubalis*) semen. *Anim. Reprod. Sci.*, 62: 55-76.
- Singh, U.B. and Bharadwaj, M.B. (1980). Histological studies on the testicular seminal pathway and changes in the epididymis of the camel (*Camelus dromedaries*). *Acta. Anat.*, 108: 481-489.
- Songsasen, N., Tong, J. and Leibo, S.P., (1998). Birth of live mice derived by in vitro fertilization with spermatozoa retrieved up to twenty- four hours after death. *J. Exp.Zool.*, 280: 189-196.
- Yu, I. and Leibo, S.P. (2002). Recovery of motile, membrane intact spermatozoa from canine epididymis stored for 8 days at 4°C. *Theriogenology*, 57: 1179-1190.