

Original Research Article

<https://doi.org/10.20546/ijcmas.2020.907.020>

## Effects of General Anaesthesia with Xylazine Hydrochloride and Ketamine Hydrochloride on Resistive and Pulsatility Indices of Dogs

Sunita Meher<sup>1</sup>, Biswadeep Jena<sup>1\*</sup>, Indramani Nath<sup>1</sup>, Kautuk Kumar Sardar<sup>2</sup>,  
Sidhartha Sankar Behera<sup>1</sup>, Prasana Kumar Rath<sup>3</sup> and Sagar Sahoo<sup>1</sup>

<sup>1</sup>Department of Veterinary Surgery & Radiology, <sup>2</sup> Department of Veterinary Pharmacology and Toxicology, <sup>3</sup> Department of Veterinary Pathology, College of Veterinary Science and Animal Husbandry, Odisha University of Agriculture and Technology, Bhubaneswar, Odisha, India

\*Corresponding author

### ABSTRACT

#### Keywords

Canine, general anaesthesia, xylazine hydrochloride, ketamine hydrochloride, and pulsed wave index

#### Article Info

Accepted:  
05 June 2020  
Available Online:  
10 July 2020

The aim of the study was to clinically compare physiological, haemodynamic, haematobiochemical and ultrasonographic Pulsed Wave indices like Peak Systolic Velocity (PSV), End Diastolic Velocity (EDV), Resistive Index (RI) and Pulsatility Index (PI) of abdominal aorta and renal arteries before and after induction of general anaesthesia with Xylazine hydrochloride and Ketamine hydrochloride in 23 adult healthy canine patients (13 male, 10 female) with a age ranging from 1.2 to 8 years of age and bodyweight ranging from 9 to 34 Kg body weight, presented for elective surgeries. Our study showed significant decrease in PSV in renal arteries, EDV and PI of abdominal aorta. There was also significant increase in PI of renal arteries. This concluded above combination for general anaesthesia preserved cardiovascular compensatory mechanism but it might exacerbate renal functionality.

### Introduction

Duplex doppler ultrasonography provides real time anatomic and dynamic vascular flow information, including information about peripheral vascular resistance. The presence, direction and type of blood flow can be determined during duplex examinations. Information about vascular impedance cannot

be obtained from absolute velocity, thus, indices have been developed to evaluate and compare Doppler wave forms. These indices are velocity ratios obtained by pulsed wave Doppler ultrasonography.

The resistive index (RI) and the pulsatility index (PI) provide information on expression of the resistance to blood flow within an

artery (Novellas *et al.*, 2007a & 2007b). The analysis of the Doppler spectra and calculating resistivity and pulsatility indices, provides unique physiological information related to peripheral resistance, vascular compliance, conductance and transmural pressure. The higher the interstitial pressure, arterial wall stiffness and resistance of capillary bed, the lower the flow velocity at the end of the diastole, eventually resulting in high resistivity index (Ostrowska *et al.*, 2016).

Blood flow is determined without sedation in human medicine. However, prior to imagining, sedation may be required for restraining in veterinary medicine because poor patient cooperation, high respiratory and heart rates and voluntary movement could interfere with the outcome, especially in cases that require detailed investigations such as abdominal vascular ultrasonography (Lee *et al.*, 2002a; Lee *et al.*, 2002b; Riesen *et al.*, 2002; Lee *et al.*, 2004 and Kaya *et al.*, 2011).

Altered RI and PI have been reported in dogs and cats with renal disease. Increased renal RI and PI due to urinary obstruction have been described. Increased renal RI in dogs and cats with acute and chronic renal failure and congenital dysplasia has also been reported (Novellas *et al.*, 2007a & 2007b). Some sedatives and anesthetics may modify the RI and PI. A combination of atropine, diazepam, acepromazine, and ketamine reduced the renal RI in healthy dogs. However, in cats sedated with a combination of atropine, acepromazine, and ketamine, a renal RI value similar to that obtained in unsedated cats or dogs was observed. Increased renal RI and PI in cats anaesthetized with isoflurane has also been reported (Rivers *et al.*, 1996; Mitchell *et al.*, 1998; Petersen *et al.*, 1997; Novellas *et al.*, 2007a & 2007b). Anaesthetic agents may also alter systemic and renal haemodynamics through affecting

vascular resistance (Rivers *et al.*, 1997; Lee *et al.*, 1990; Kaya *et al.*, 2011)

The combination of Xylazine HCL and Ketamine HCL is commonly used to anaesthetize ill or critical animals in our institution if chemical restraint is required. Cardiac output, heart rate, stroke volume and cardiac index were significantly decreased. Systolic, diastolic and mean arterial blood pressure was also significantly decreased. Systemic vascular resistance and central venous pressure were significantly increased (Jena *et al.*, 2014).

The purpose of this study is to present values for pulsed wave indices in clinically normal dogs anaesthetized with Xylazine HCL and Ketamine HCL and to evaluate if there are any changes with respect to non-anaesthetized dogs.

## **Materials and Methods**

The Research work was conducted in the Department of Veterinary Surgery and Radiology and Teaching Veterinary Clinical Complex (TVCC), College of Veterinary Science & Animal Husbandry, Odisha University of Agriculture & Technology, Bhubaneswar, Odisha.

## **Subject of the study**

Adult healthy dogs (*Canine lupus familiaris*) of either sex presented to the Department of Veterinary Surgery and Radiology and Teaching Veterinary Clinical Complex (TVCC), CVSc & AH, OUAT, Bhubaneswar for elective surgeries (ovariohysterectomy or orchietomy) were made the subject of the study. The animals were kept off fed for 12 hours and off water for 4-6 hours before diagnostic imaging and surgical interventions to minimize the chances of retching and vomiting.

## Design of work

Acclimatization time for all the dogs was allowed before beginning of all observations. Hair over the entire abdomen was clipped from the xiphoid along the costal arch to the areas of the right & left lateral mid-flank regions, respectively and to the cranial aspect of the pubic bone and liberal amount of acoustic gel was applied to the skin. Triplex Doppler ultrasonography was performed with Make – Wipro GE, Model -Logiq F8 Expert ultrasound machine.

The animals were kept in dorsal recumbency to scan the intrarenal vasculature and abdominal aorta (Szatmari *et al.*, 2001a & 2001b, D'Anjou, 2008 Mantis, 2008 and Priyanka *et al.*, 2015). Different transducers and frequencies (8C Micro Convex Multifrequency Probe of 6.0 – 10.0 MHz, L6-12 Linear Multifrequency Probe 6.0 – 12.0 MHz) were used depending on animal weight and abdominal depth. B-Mode followed with Continuous Wave (CW) Doppler was used to visualize the abdominal aorta and intrarenal (interlobar or arcuate arteries) vasculature.

Subsequent Pulse Wave (PW) Doppler interrogation from above arteries was obtained with a sample width of 0.1-33 mm and a frequency of 1.7-10 MHz which was dependent upon type of probe and size of the animal. The Peak Systolic Velocity (PSV), End Diastolic Velocity (EDV), Resistive index (RI) and Pulsatility Index (PI) were calculated automatically by the in-built software of the ultrasound machine (Szatmari *et al.*, 2001, Miño *et al.*, 2008; Gamal and Daoud, 2013).

Adult, healthy animals were subjected to triplex doppler ultrasonography to observe various ultrasonographic parameters under B-mode (Brightness or, 2-D mode) and spectral doppler modes like CW- mode (continuous wave) and PW- mode (Pulse wave) in normal

awake condition before administration of any pre-anaesthetics or, anaesthesia.

After above examination, a routine combination of Atropine Sulphate (Tropine® 0.6 mg/ml, Neon Laboratories) at the dose rate of 0.04 mg/KgBW subcutaneously, Xylazine hydrochloride (Xylaxin® 23.32 mg/ml, Indian Immunologicals Limited) at the dose rate of 1 mg/KgBW and Ketamine hydrochloride (Aneket® 50 mg/ml, Neon Laboratories, Palghar, Thane) was administered at the dose rate of 5mg/KgBW intramuscularly. 15 minutes after achievement of general anaesthesia, animal was again being subjected to aforementioned ultrasonographic observations.

## Statistical analysis

The quantitative data were presented as Mean  $\pm$  Standard Error (SE). Correlation, mean comparison tests (paired t-tests) and One-Way ANOVA was estimated using IBM SPSS (Statistical Package for Social Science) statistical analysis package version - 20. Determinants of correlation (Pearson's for normal distribution or Spearman's for non-normal distribution) were used to determine for a relationship between RI, PI and systolic pressures. For hypothesis testing  $P < 0.01$  and  $P < 0.05$  were considered and the level of significance (Snedecor and Cochran, 1994).

## Results and Discussion

The present study was conducted on 23 adult healthy (13 male, 10 female) pet dogs presented for elective surgeries for a period of six months from January 2019 to June 2019. The Mean  $\pm$  SE value of age for above animals was  $3.76 \pm 0.46$  years of age, ranging from 1.2 to 8 years of age. The Mean  $\pm$  SE value of body weight for above animals was  $20.04 \pm 1.60$  Kg body weight, ranging from 9 to 34 Kg body weight.

### **Triplex Doppler ultrasonographic observations**

The renal cortex was finely granular, uniform in echogenicity, hyperechoic to the renal medulla, hypoechoic to the spleen. The renal medulla was hypoechoic to almost anechoic to the cortex, was interrupted by the diverticuli. Centrally, the renal pelvis was seen as anechogenic disc of tissue because of its surrounding fat. The pelvic diverticulae, interlobar and arcuate vessels were seen as linear echogenicities and colour coded radiating to the cortex from the central pelvic region. Similar findings have been reported by Mantis (2008), Moarabi *et al.*, 2011) and Hart *et al.*, 2013) (Fig. 1). After comparing figure 1 and 2; there had been significantly visible decrease in blood flow through interlobar and arcuate renal vasculature after general anaesthesia.

PW Doppler indices viz. resistive index (RI) and pulsatility index (PI) were recorded from intrarenal vessels of kidneys showed a typical low resistance parabolic flow velocity profile (i.e. systolic peaks with broad velocity distribution and closed spectral window). After the systolic peak, the velocity dropped a little, then got higher again (diastolic peak velocity), and in the rest of diastole gradually decreased (Szatmari *et al.*, 2001a & 2001b; Kaya *et al.*, 2011) (Fig. 3 & 4).

Abdominal aorta (AA) walls were parallel, hyperechoic and appeared as thin smooth lines. In addition, aortic pulses were also observed which was absent in caudal vena cava. Aorta was less compressible than the caudal vena cava and had a thicker wall. On color flow doppler, aorta showed the blood flow towards the transducer i.e. red color and caudal vena cava was having the flow away from the transducer i.e. blue color (Fig 5). This observation was in agreement with Spaulding (1997) and Priyanka *et al.*, (2015),

who stated that flow within the vena cava would be towards the heart (away from transducer) and flow within the aorta towards the limbs (towards the transducer).

Abdominal aorta is a central elastic-type artery and is heavily involved with cardiac contractility in the transmission of the pulse wave (Koenig *et al.*, 1999; Baumgartner *et al.*, 2010). Abdominal aorta had a typical high-resistance triphasic plug type velocity profile. The velocity distribution or pattern was narrow. The waveform has a high, sharp systolic peak with a large, clear spectral window (Fig. 6 & 7) (Ochoa *et al.*, 2011; Mattoon, 2013 and Priyanka *et al.*, 2015).

Continuous forward flow was observed in the AA. The AA had a high resistance plug flow velocity profile and its waveform was a high-resistance flow pattern. It had a sharp systolic peak with a large and clear spectral window. The velocity distribution was narrow. The systolic peak was followed by a retrograde flow wave, followed by a forward flow wave (three-phasic flow wave) (Szatmari *et al.*, 2001a; Szatmari *et al.*, 2001b and Kaya *et al.*, 2011).

Quantitative changes in Pulsed wave indices of abdominal aorta and renal arteries were delineated in table 1. According to our observation, there were significant decrease in PSV in renal arteries; EDV and PI of abdominal aorta. There was also significant increase in PI of renal arteries.

Anaesthetic agents may change systemic and renal haemodynamics and subsequently affect vascular resistance. When vascular resistance increases, the resultant blood flow decreases in case of normal cardiac function and hydration status (Nelson and Pretorius, 1988). Decrease in PSV after general anaesthesia with Xylazine and ketamine in adult, healthy canine animals, may be attributed to increased

peripheral resistance (Morrow *et al.*, 1996; Biricik *et al.*, 2010) due to activation of peripheral  $\alpha_1$ - and  $\alpha_2$ -adrenoceptors and central  $\alpha_2$ -adrenoceptors. Biricik *et al.*, (2010) observed a significant decrease in PSV in canine femoral artery after administration of Xylazine, which is a central elastic-type larger artery similar to abdominal aorta characterized by high-resistance triphasic plug type velocity profile (Szatmari *et al.*, 2001a; Szatmari *et al.*, 2001b; Kaya *et al.*, 2011; Ochoa *et al.*, 2011; Mattoon, 2013; Terkawi *et al.*, 2013 and Priyanka *et al.*, 2015). Significant decrease in PSV is also been reported in dog by Mino *et al.*, (2008), after administration of Medetomidine (an  $\alpha_2$ -adrenoreceptor agonist like Xylazine) due to increase in peripheral vascular resistance.

Lee *et al.*, (2004) reported that PSV of AA is about  $121 \pm 24$  (Rane 86-145) cm/sec which was much higher to the value, we observed in our study. This might be due to the foreign environmental, psychological and procedural (though a non-invasive method) stress born by the animal, albeit sufficient acclimatization period had been provided. These stresses might have a cumulative effect to increase mean arterial pressures and peripheral vascular resistance, which might have diminished the PSV values in our study.

Decrease in EDV after general anaesthesia with Xylazine and ketamine in adult, healthy canine animals, may also be attributed to increased peripheral resistance (Morrow *et al.*, 1996; Biricik *et al.*, 2010). An increase in vascular resistance is the most likely cause of decreased blood flow when cardiac function and hydration status are normal. Similar observations have also been made by Kaya *et al.*, (2011). Significant decrease in EDV is also been reported in dog by Mino *et al.*, (2008), after administration of Medetomidine (an  $\alpha_2$ -adrenoreceptor agonist like Xylazine)

due to increase in peripheral vascular resistance.

Resistance in the tubular structure depends on the radius and length of the vessels. Small decrease in the diameter results in large increase in resistance as vessel resistance is indirectly proportional to 4<sup>th</sup> power of vessel diameter. Because, forward flow in diastole is less forceful, increase in stream resistance results in a greater reduction in diastolic flow as compared to systolic flow (Kremkau, 1990; Baghel *et al.*, 2018). Therefore, we were observing a significant decrease in EDV of AA, whereas a non-significant decrease was observed in PSV of AA.

Lee *et al.*, (2004) reported that EDV of AA is about  $37 \pm 7$  (Rane 27-45) cm/sec which was much higher to the value, we observed in our study. This might be due to the foreign environmental, psychological and procedural (though a non-invasive method) stress born by the animal, albeit sufficient acclimatization period had been provided.

These stresses might have a cumulative effect to increase mean arterial pressures and peripheral vascular resistance, which might have diminished the EDV values in our study. In the present study, RI and PI changes were recorded during the measurements which could be useful indicators of peripheral resistance (Lin & Spratt 1997; Mueck-Weymann *et al.*, 1999; Ban *et al.*, 2005; Baumgartner *et al.*, 2010).

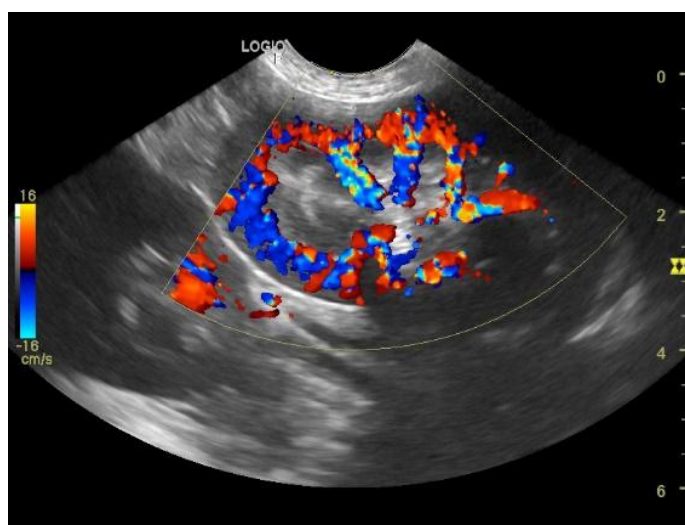But there were insignificant changes among values of RI in abdominal aorta and renal arteries. Insignificant change in values for the renal RI before sedation were similar to previous studies in normal nonsedated dogs (Nyland *et al.*, 1993; Morrow *et al.*, 1996; Rivers *et al.*, 1997; Novellas *et al.*, 2007a and Novellas *et al.*, 2007b).



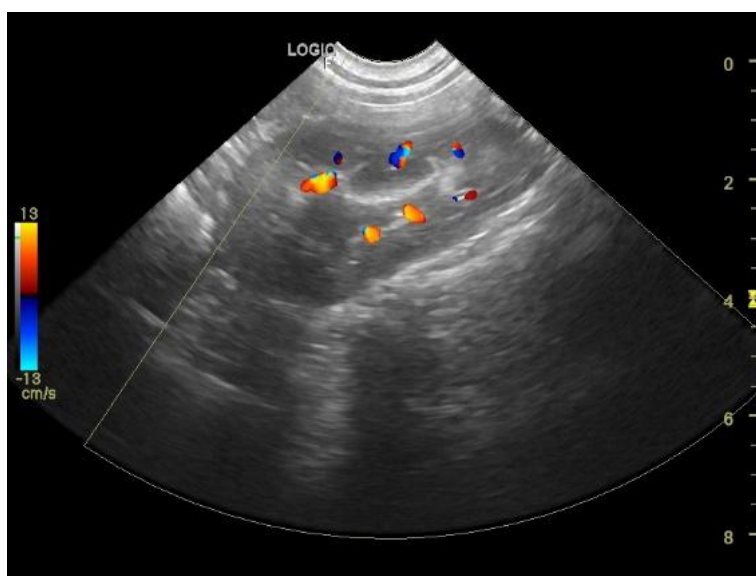
**Table.1** Mean±SE values of pulsed wave indices before and after general anaesthesia in dogs

Pulse index	wave	Abdominal Aorta (AA)		Renal arteries (RA)	
		Before general anaesthesia	After general anaesthesia	Before general anaesthesia	After general anaesthesia
PSV(cm/sec)		53.90 ± 10.03	31.32 ± 7.46	26.33 ± 5.19	17.68 ± 5.63**
EDV(cm/sec)		17.67 ± 6.71	4.20 ± 1.39**	9.60 ± 2.19	7.38 ± 1.65
RI		0.73 ± 0.06	0.81 ± 0.09	0.75 ± 0.13	0.54 ± 0.08
PI		3.56 ± 0.83	2.64 ± 0.34*	2.22 ± 0.57	2.82 ± 1.78*

\*Significantly different from the base value (P<0.05); \*\* (P<0.01)



**Figure.1** Showing Colour Doppler observation of left kidney before induction of anaesthesia. Notice the interlobar and arcuate renal blood vessels of left kidney



**Figure.2** Showing Colour Doppler observation of left kidney after induction of anaesthesia; Notice visibly diminished blood supply through the interlobar and arcuate renal blood vessels of left kidney.

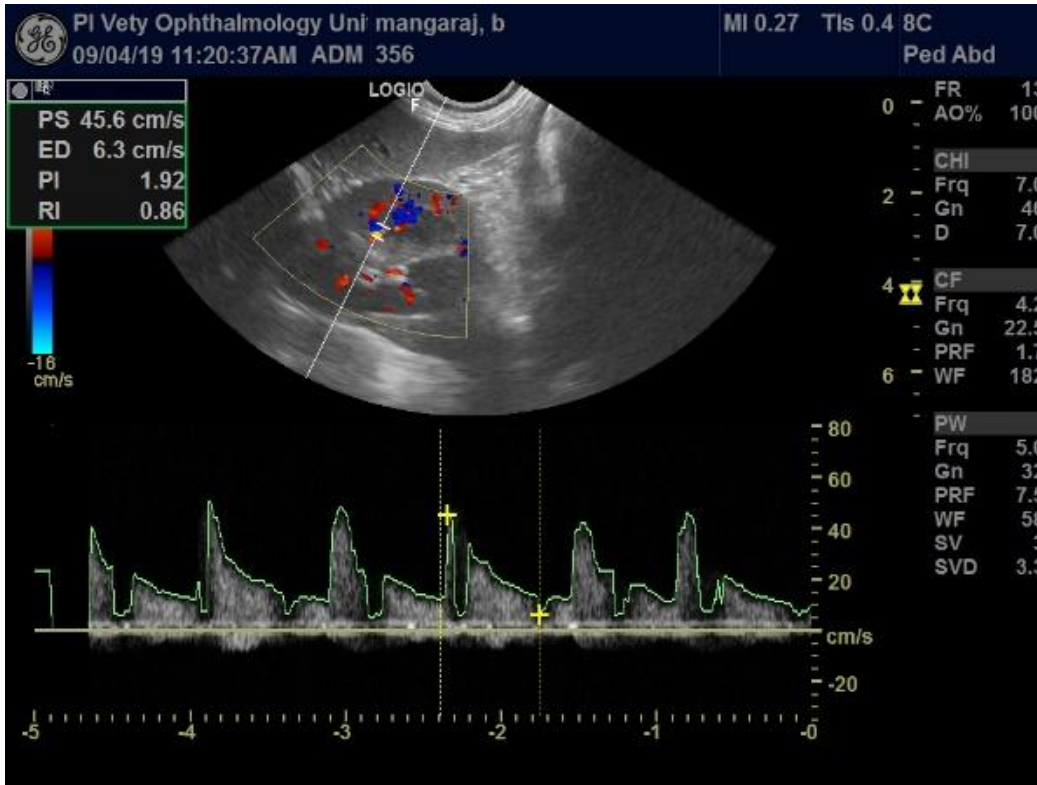


Figure.3 Showing the PW indices of left kidney in a healthy dog before general anaesthesia

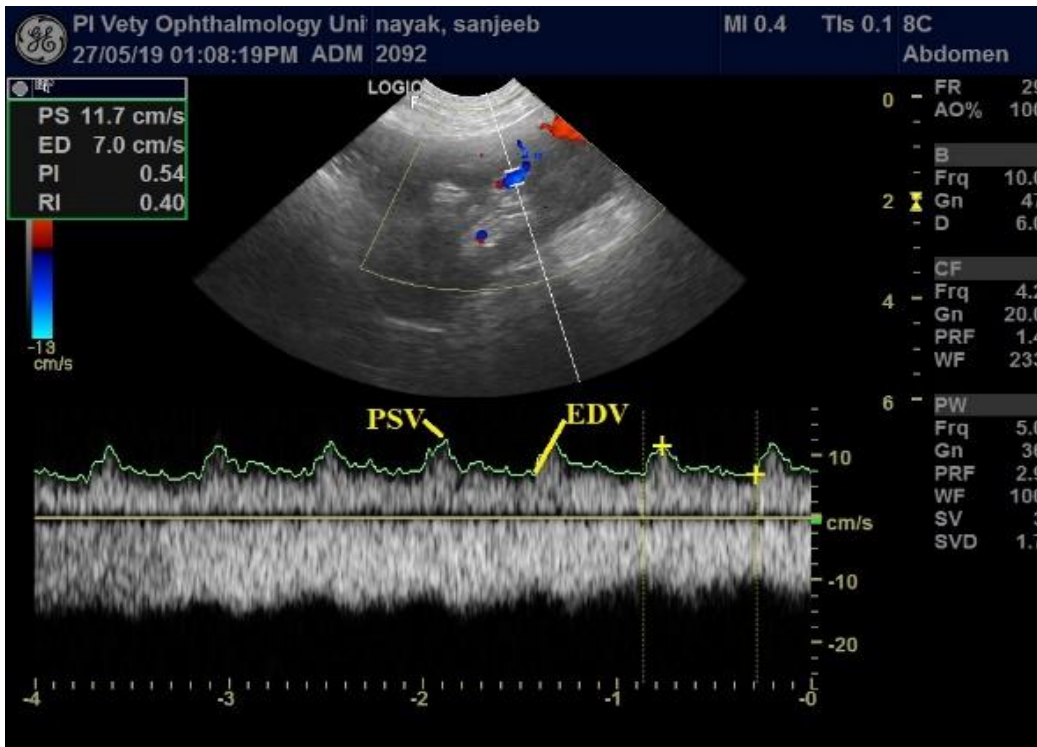
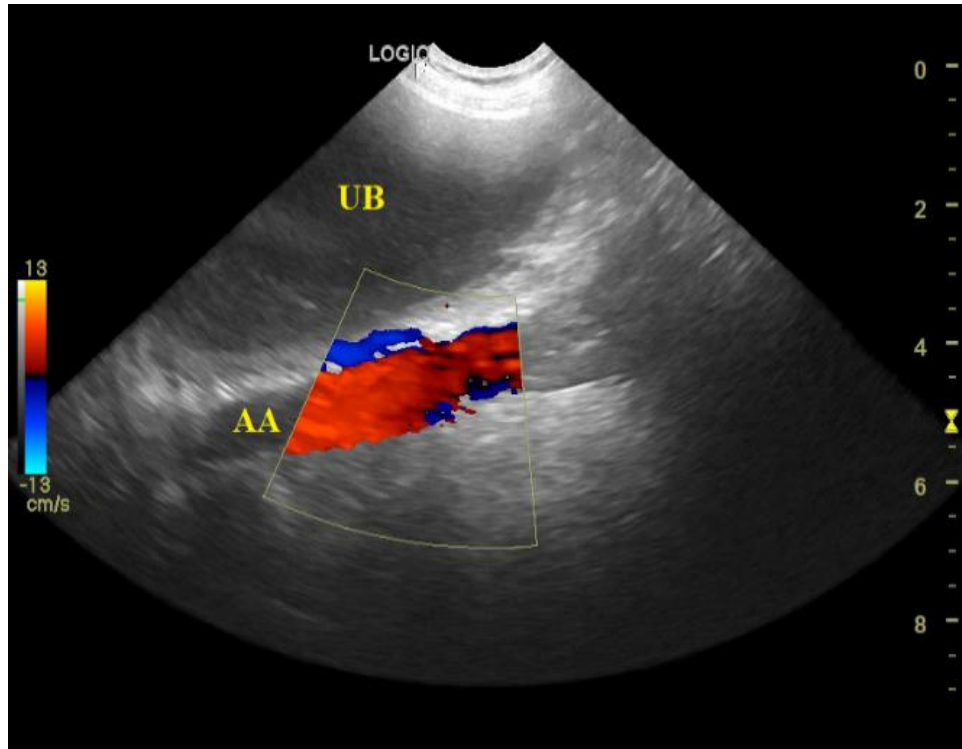
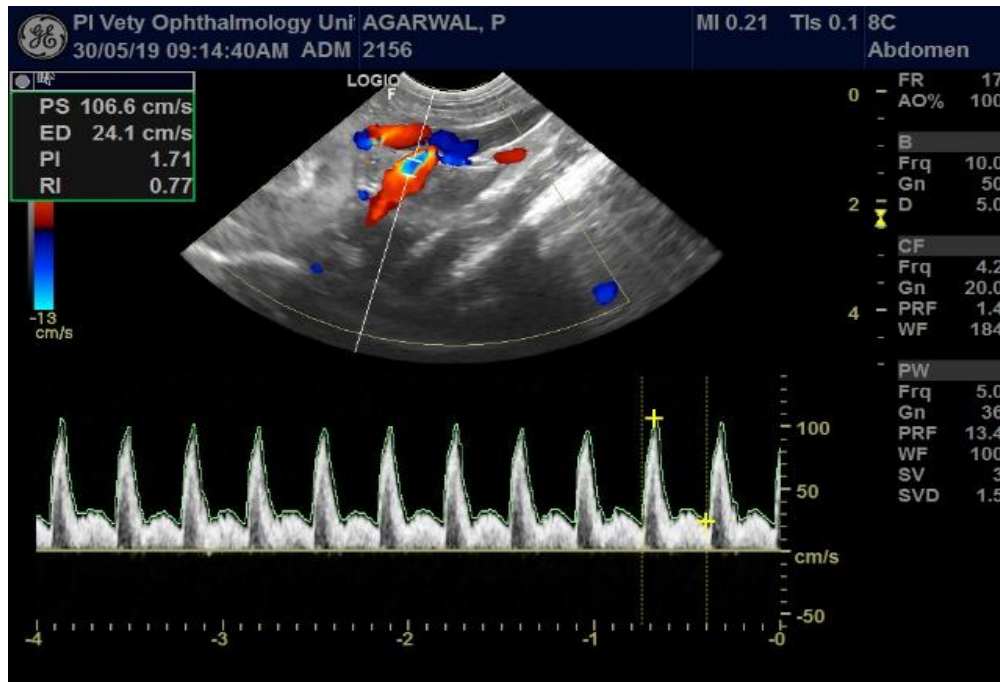


Figure.4 Showing the PW indices of left kidney in a healthy dog after general anaesthesia; Notice the typical low resistance parabolic flow velocity profile observed from intrarenal vessels of left kidney. PSV= Peak Systolic Velocity, EDV= End Diastolic Velocity

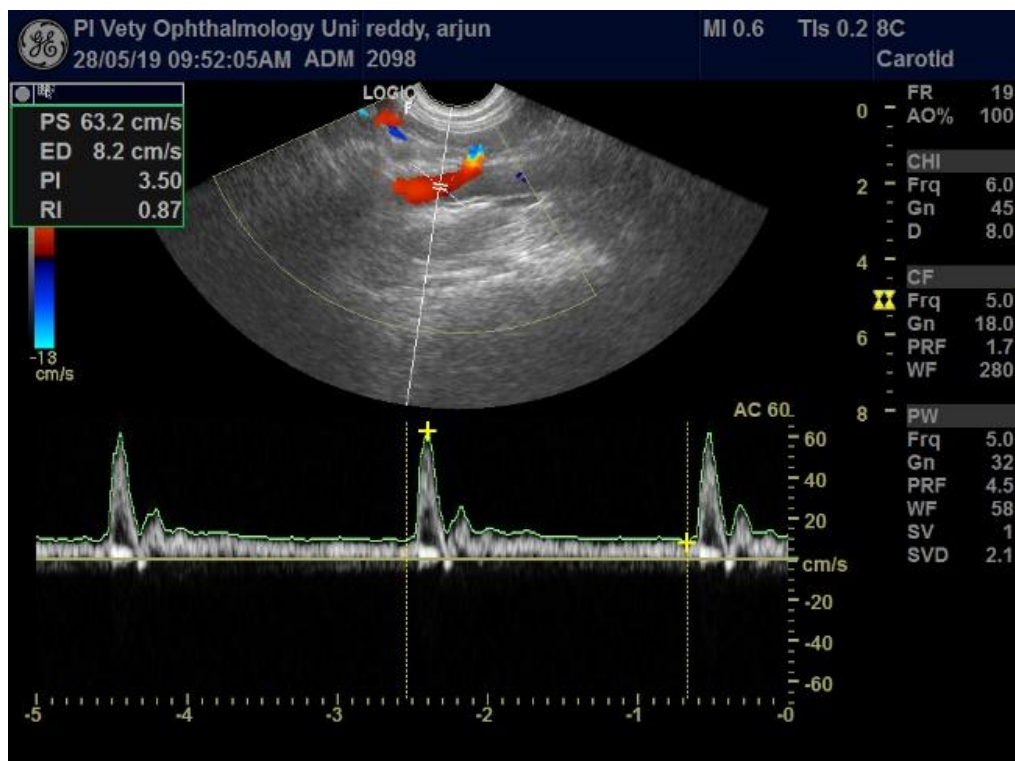


**Figure.5** Showing location and Colour Doppler image of Abdominal aorta (AA) dorsal to urinary bladder (UB) in longitudinal plane in a healthy dog before induction of general anaesthesia



**Figure.6** Showing PW indices of abdominal aorta in a healthy dog before general anaesthesia. Notice the typical high-resistance triphasic plug type velocity profile characterized by sharp peaks of systolic cardiac pump





**Figure.7** Showing PW indices of abdominal aorta in a healthy dog after general anaesthesia

The range for the normal RI is large in our study and also in human studies. This may be due to the effects of other physiological processes or to the many inherent factors that affect renal blood flow. These include cardiac output and rate, level of the kidney in relation to the heart, respiration which may be compromised due to dorsal recumbency, digestion, stress level, medications and sedatives. It has been shown that increased pressure on the kidney exerted by the ultrasound transducer can artificially elevate the RI in humans (Morrow *et al.*, 1996; Novellas *et al.*, 2007; Biricik *et al.*, 2010).

A decrease of EDV at the abdominal aorta and an increase of RI and a significantly decrease PI was observed in the current study immediately after the first KET-XYL injection which was in concomitant with Baumgartner *et al.*, (2010). Such observations might be due to increase in diameter in abdominal aorta as observed by Baumgartner *et al.*, (2010).

Renal vascular network has the largest surface area in the animal's body. Since pressure is a function of force per unit area, ( $P = F/A$ ), the larger the surface area, the lesser the pressure when an external force act on it. Though the radii of the renal capillaries are very small, the network of capillaries have the largest surface area in the vascular network. The larger the total cross-sectional area, the lower the mean velocity as well as the pressure. This might be the reason, there was significant increase in PI of renal arteries.

Hence, our study recorded significant decrease in PSV in renal arteries, EDV and PI of abdominal aorta. There was also significant increase in PI of renal arteries. This was of important significance that there was significant decrease in blood flow to renal vasculature courtesy of increase in vascular resistance. Hence, it was of opinion that xylazine-ketamine combination for general anaesthesia indicated a well-preserved cardiovascular compensatory mechanism

supported by minimalistic changes in Pulsed Wave Indices. But due to profound changes in Pulsed Wave Indices renal vasculature, it was advised not to use aforementioned combination in patients with renal affections.

### **Acknowledgement**

The authors would like to thank the Hon'ble Vice-Chancellor, Odisha University of Agriculture and Technology; Dean, College of Veterinary Science and Animal Husbandry and Director, Teaching Veterinary Clinical Complex, Odisha University of Agriculture and Technology, Bhubaneswar, Odisha, India for providing the necessary facilities for the research.

### **References**

- Baghel, M., Rafee, M. A., & Zama, M. M. S., 2018. Doppler haemodynamic effects of thiopentone /propofol /ketamine anaesthesia on renal artery in dogs. *SKUAST Journal of Research*, 20(1), 68-72.
- Ban, K., Kochi, K., Imai, K., Okada, K., Orihashi, K., & Sueda, T., 2005. Novel Doppler technique to assess systemic vascular resistance. *Circulation Journal*, 69(6), 688-694.
- Baumgartner, C., Bollerhey, M., Ebner, J., Laacke-Singer, L., Schuster, T., & Erhardt, W., 2010. Effects of ketamine-xylazine intravenous bolus injection on cardiovascular function in rabbits. *Canadian Journal of Veterinary Research*, 74(3), 200-208.
- D'Anjou M A., 2008. Kidneys and Ureters. In: Pennick D. (ed). *Atlas of Small Animal Ultrasonography*. 1st Edn. Blackwell Publishing, USA. pp 339.
- Gamal G H and Daoud M A., 2013. Renal Doppler Ultrasonography: A Non Invasive Predictor of Kidney Dysfunction. *Life Science Journal* 10(1): 1064-67.
- Hart D V, Winter M D, Conway J and Berry C D., 2013. Ultrasound appearance of the outer medulla in dogs without renal dysfunction. *Veterinary Radiology and Ultrasound* 54(6): 652-58.
- Jena, B., Das, J., Nath, I., Sardar, K. K., Sahoo, A., Beura, S. S., & Painuli, A., 2014. Clinical evaluation of total intravenous anaesthesia using xylazine or dexmedetomidine with propofol in surgical management of canine patients. *Veterinary World*, 7(9).
- Kaya, M., Pekcan, Z., Sen, Y., Boztok, B., Senel, O. O., & Bumin, A., 2011. Effects of short-acting anaesthetics on haemodynamic function as determined by Doppler ultrasonography in rabbits. *Kafkas Univ Vet Fak Derg*, 17, 713-719.
- Koenig S, Shafie M, Pearson A, Laureano, M.A., Cerrito, P., Ewert, D., Schroeder, M. and Dowling, R.D., 1999. Intraoperative assessment of acute hemodynamic changes after partial left ventriculectomy. *Journal of cardiac surgery*, 14 (2), 152-156.
- Kremkau, F.W., 1990. Diagnostic ultrasound principles, instruments and exercise. Harcourt brace jovanavish Philadelphia. *Clinical Radiology*, 41: 442.
- Lee, H., Chang, D., Lee, Y., Eom, K., Choi, H., Seo, K., Choi, M. and Yoon, J., 2002a. Use of color Doppler imaging for determining the resistive index of the medial long posterior ciliary artery in clinically normal conscious dogs. *American Journal of Veterinary Research*, 63: 211-214.
- Lee, K. C., Choi, M. C., & Yoon, J. H., 2002b. Influence of isoflurane anesthesia on pulsatility index and peak systolic velocity of basilar artery in dogs by Doppler ultrasonography. *Journal of veterinary science*, 3(3), 203-206.
- Lee, K., Choi, M., Yoon, J., & Jung, J., 2004.

- Spectral waveform analysis of major arteries in conscious dogs by Doppler ultrasonography. *Veterinary Radiology & Ultrasound*, 45(2), 166-171.
- Lee, S.W., Hankes, G.H., Purohit, R.C., Bartels, J.E., Cartee, R.E., Pablo, L. and Conti, J.C., 1990. Comparative study of ultrasonography and arteriography of the carotid artery of xylazine-sedated and halothane-anesthetized goats. *American journal of veterinary research*, 51(1), 109–113
- Lin GS and Spratt RS, 1997. Hemodynamic imaging with pulsatility index and resistive index color Doppler US. *Radiology*, 204, 870–873.
- Mantis P., 2008. Ultrasonography of the Urinary and Genital System of the Dog and Cat. *Iranian Journal of Veterinary Surgery* pp. 63-71.
- Mastorakou I, Robbins M and Bywaters T., 1992. Resistance and pulsatility doppler indices: how accurately do they reflect changes in renal vasculature resistance. *The British Journal of Radiology* 66: 577-80
- Mattoon, J.S., 2013. Use of Doppler Ultrasound in the Abdomen. Western Veterinary Conference, pp28-36.
- Miño, N., Espino, L., & Barreiro, A., 2008. Effects of medetomidine on Doppler variables of major abdominal arteries in normal dogs. *Veterinary research communications*, 32(2), 175-186.
- Mitchell, S. K., Toal, R. L., Daniel, G. B., & Rohrbach, B. W., 1998. Evaluation of renal hemodynamics in awake and isoflurane-anesthetized cats with pulsed-wave Doppler and quantitative renal scintigraphy. *Veterinary Radiology & Ultrasound*, 39 (5), 451-458.
- Moarabi A, Mosallanejad B, Ghadiri A R and Borujeni M P., 2011. Ultrasonographic Evaluation of the Urinary System in New Zealand White Rabbit and Tolai Hare. *Veterinary Research Forum* 2(2):113-20.
- Morrow, K. L., Salman, M. D., Lappin, M. R., & Wrigley, R., 1996. Comparison of the resistive index to clinical parameters in dogs with renal disease. *Veterinary Radiology & Ultrasound*, 37(3), 193-199.
- Mueck-Weymann M, Wupperman T, 1999. Physiologie und Pathophysiologie des Blutflusses. In: Sonographie der GefäÙe. Wupperman T (ed.). Urban & Fischer, München, Germany, pp. 21–27.
- Nelson, T.R. and Petorius, D.H., 1988. Introduction to Vascular Ultrasonography. Basic concept of doppler frequency analysis and ultrasound blood flow imaging ultrasound: Expert Consult - Online - Page 59. *books.google.co.in*.
- Novellas, R., Espada, Y., & De Gopegui, R. R., 2007a. Doppler ultrasonographic estimation of renal and ocular resistive and pulsatility indices in normal dogs and cats. *Veterinary Radiology & Ultrasound*, 48(1), 69-73.
- Novellas, R., Ruiz De Gopegui, R., & Espada, Y., 2007b. Effects of sedation with midazolam and butorphanol on resistive and pulsatility indices in healthy dogs. *Veterinary Radiology & Ultrasound*, 48(3), 276-280.
- Nyland, T. G., Fisher, P. E., Doverspike, M., Hornof, W. J., & Olander, H. J., 1993. Diagnosis of urinary tract obstruction in dogs using duplex Doppler ultrasonography. *Veterinary Radiology & Ultrasound*, 34(5), 348-352.
- Ochoa, P.G, Delia, L, Ivan, S, Manuel, G, Juan, J. R. and Luis, M. F., 2011. Fundamentals and Applications of Abdominal Doppler. *Ultrasound Imaging Medical Applications.*, 21: 267- 282.
- Ostrowska, J., Kiełbowicz, Z., Zaleska-

- Dorobisz, U., Atamaniuk, W., Pietsch-Fulbiszewska, A., & Kinda, W. 2016. Resistive index (RI) obtained in renal interlobar arteries of normal dogs and cats by means of Doppler ultrasonography. *Pakistan Veterinary Journal*, 36(1), 45-48.
- Petersen, L. J., Petersen, J. R., Talleruphuus, U., Ladefoged, S. D., Mehlsen, J., & Jensen, H. A., 1997. The pulsatility index and the resistive index in renal arteries. Associations with long-term progression in chronic renal failure. *Nephrology, dialysis, transplantation: official publication of the European Dialysis and Transplant Association-European Renal Association*, 12(7), 1376-1380.
- Priyanak, Jeyaraja, K. and Thirunavakkarasu, P.S., 2015. Doppler Ultrasonography of Abdominal Vasculature in Canines. *International Journal of Advanced Research*, 3(4), 1167-1171.
- Riesen, S., Schimid, V., Gaschen, L., Busato, A. and Lang, J., 2002. Doppler measurement of splanchnic blood flow during digestion in unsedated normal dogs. *Veterinary Radiology and Ultrasound*, 43: 554-560.
- Rivers, B. J., Walter, P. A., O'Brien, T. D., & Polzin, D. J., 1996. Duplex Doppler estimation of Pourcelot resistive index in arcuate arteries of sedated normal cats. *Journal of veterinary internal medicine*, 10(1), 28-33.
- Rivers, B.J., Walter, P.A., Letourneau, J.G., Finlay, D.E., Ritenour, E.R., King, V.L., O'Brien, T.D. and Polzin, D.J., (1997). Duplex Doppler estimation of resistive index in arcuate arteries of sedated, normal female dogs: implications for use in the diagnosis of renal failure. *Journal of the American Animal Hospital Association*, 33(1), 69-76.
- Snedecor, G.W. and Cochran, W.G., 1994. Statistical methods. 8th edn. Iowa State University Press, Ames, IA.
- Spaulding, K.A., 1997. A review of sonographic identification of abdominal blood vessels and juxtavascular organs. *Veterinary Radiology and Ultrasound*, 38: 4-23.
- Szatmari V, Sotonyi P and Voros K., 2001a. Normal Duplex Doppler waveforms of major abdominal blood vessels in dogs: a review. *Veterinary Radiology and Ultrasound* 42(2):93-107.
- Szatmári, V., Sótónyi, P. and Vörös. K., 2001b. "Normal duplex Doppler waveforms of major abdominal blood vessels in dogs: a review." *Veterinary Radiology & Ultrasound* 42.2: 93-107. *ternational*, 83(4), 378-382.
- Terkawi, A. S., Karakitsos, D., Elbarbary, M., Blaivas, M., & Durieux, M. E., 2013. Ultrasound for the anesthesiologists: present and future. *The scientific world journal*, 1-15.

#### How to cite this article:

Sunita Meher, Biswadeep Jena, Indramani Nath, Kautuk Kumar Sardar, Sidhartha Sankar Behera, Prasana Kumar Rath and Sagar Sahoo. 2020. Effects of General Anaesthesia with Xylazine Hydrochloride and Ketamine Hydrochloride on Resistive and Pulsatility Indices of Dogs. *Int.J.Curr.Microbiol.App.Sci*. 9(07): 161-172.  
doi: <https://doi.org/10.20546/ijcmas.2020.907.020>