

Original Research Article

<https://doi.org/10.20546/ijcmas.2020.907.232>

Histological Differences in the Three Epididymal Regions of Sheep (*Ovis aries*) in Relation to Spermatozoan Maturation

D. Sengupta, K. Ray, C. S. Azad and S.K. Sheetal*

Department of Veterinary Gynaecology and Obstetrics, Bihar Veterinary College, Bihar
Animal Sciences University, Patna, Bihar, India

*Corresponding author

ABSTRACT

The present work was performed to study the histology of caput, corpus and cauda epididymis of sheep and to explain the variations in terms of spermatozoan maturation that takes place in these regions. Epididymis was collected after dissection of testis by open method. After ligating the proximal end of ductus deferens and cauda and distal to the caput epididymis, the epididymis was excised separately and fixed in Buin's fixative. The tissue was prepared as per standard histological procedure and five micron thick sections were cut by microtome and stained by Haematoxyline and Van-Gieson's stain. The lining epithelium of the entire epididymal tubule was found to be pseudostratified with tall columnar cells of two types i.e. principal cells and basal cells. The basal cells, located near the basement membrane of epididymal tubule, were lesser in caput than cauda. Steriocilia were longest in the caput and were less prominent in the other two regions. Decrease in epithelial thickness and increase of tubular diameter was observed from caput to cauda epididymis. Thus, this study indicates that the caput with longest stereocilia having secretory, phagocytic and absorptive function plays a vital role in spermatozoan maturation, whereas the cauda having the thinnest pseudostratified epithelium with abundant surrounding smooth muscle cells and wider lumen serves well as a storehouse of spermatozoa.

Keywords

Histology, Caput, Corpus, Cauda, Epididymis, Sheep, Spermatozoan maturation

Article Info

Accepted:

17 June 2020

Available Online:

10 July 2020

Introduction

Histologically and functionally mammalian epididymis can be divided into an initial segment where sperm maturation takes place, a terminal segment where spermatozoa are stored and an intermediate segment where transit between the two regions is accomplished in most of the species (Nicander and Glover, 1973). The maturational changes of spermatozoa which

take place in the epididymis include the formation of increased numbers of disulfide bonds in the chromatin of the condensed nucleus, alteration in the lipid metabolism and surface properties of the sperm cell membrane including motility pattern (Bedford, 1975). Thus, the histological nature of this duct, which plays an essential role for maintaining the activities of spermatozoa have been conducted.

Materials and Methods

Ten adult and healthy sheep were selected from the University sheep-breeding farm. Average age and body weight of the animals was 3 to 3 ½ years and 10.5 to 12.5 kg respectively. All the animals were maintained on standard balanced feed and water was supplied ad libitum.

Epididymes were collected after dissection of the testis by open method (O' Conner, 1980). Immediately after surgical intervention, tunica albugenia was removed from both the testes. Ligatures were placed unilaterally at the proximal end of the ductus deferens and cauda, and distal to the caput epididymis. Ligated parts of the epididymis (caput, corpus, and cauda) were excised separately and fixed in Bouin's fixative. The tissues were prepared as per standard histological procedure (Humason, 1972). Five micron thick sections were cut by microtome and the sections were stained by Weigert's haematoxyline and Van-Gieson's stain (Cullin, 1974).

Results and Discussion

Duct of the epididymis had a cylindrical outline both inside and outside. Epididymis was attached to the testis with the caput on its dorsal aspect and the cauda on the ventral aspect. The body i. e. corpus was lying along the posterolateral part of the testis (fig. 1). A layer of circularly arranged smooth muscle fibers was found to be surrounding the epididymis which had irregular arrangement in caput but definite regular arrangement was present in the corpus and caudal regions. Loose connective tissue was found outside the muscular layer followed by presence of irregular dense tissue containing abundant blood vessels as reported in other mammals (Dinakar *et al.*, 1977; Korman and Reijonen, 1976). Thickness of the intertubular

connective tissue and muscular layer increased from caput to cauda epididymal regions.

The lining epithelium of the entire epididymal tubules was found to be pseudostratified with tall columnar cells of two types, i.e. principal cells and basal cells. Lipid droplets were present in the cytoplasm of both cell types. Tall columnar cells contained pigment granules and lysosomes. The basal cells, which were located near the basement membrane of epididymal tubule, were less in number in caput (Fig. 2) and more in corpus (Fig. 3). Stereocilia were longest in the caput and were less prominent in other two regions. Stereocilium performs the function of secretion, phagocytosis and absorption (Glover, 1973) which seems to be diminished in the terminal segment, where only small micropinocytotic vesicles and a few multivesicular bodies are seen, whereas basal cells mature into stereocilium.

In the middle segment (Corpus) stereocilia were not so straight and the lumen of the duct was long. Maximum number of basal cells was present in this region, the smooth muscle was less and the epithelium was thinner. The terminal segment (cauda) is a temperature and androgen sensitive organ and provides for the spermatozoal storage. This segment bears the comparatively thinnest pseudostratified epithelium, the surrounding smooth muscle was most abundant and the lumen was very wide. The stereocilia were found to be short in this region. The decrease in epithelial thickness and increase of tubular diameter from caput to cauda epididymis corroborated well with the findings of others (Dinakar *et al.*, 1977; Wrobel and Fallenbacher, 1974). Moreover, the variation in the height of the columnar cells at different levels of the duct in sheep may be due to differences in luminal pressure (Vitale-Calpe and Aoke, 1971).

Figure.1 The three epididymal regions of sheep in relation to testis

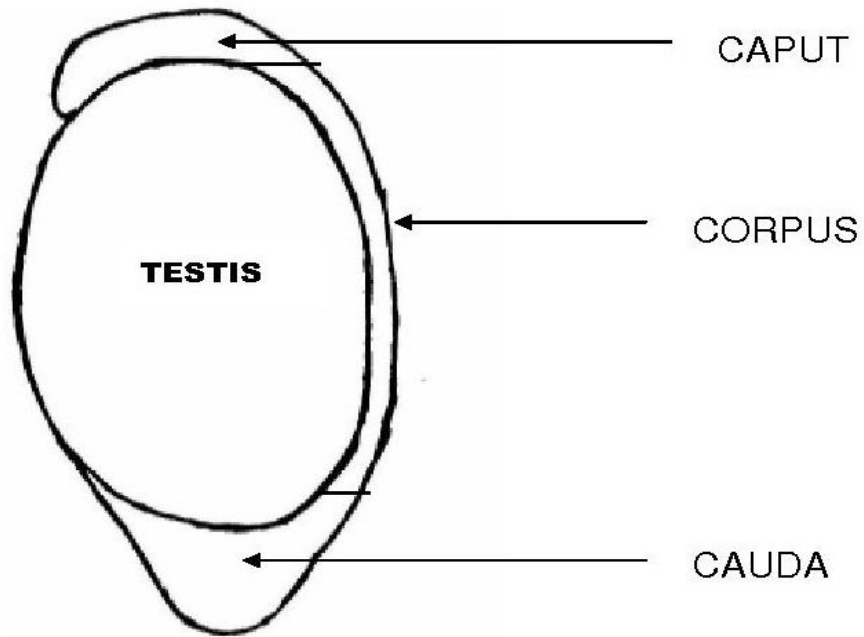


Figure.2 Photomicrograph showing transverse histological section of caput epididymis of sheep (H&E, X100)

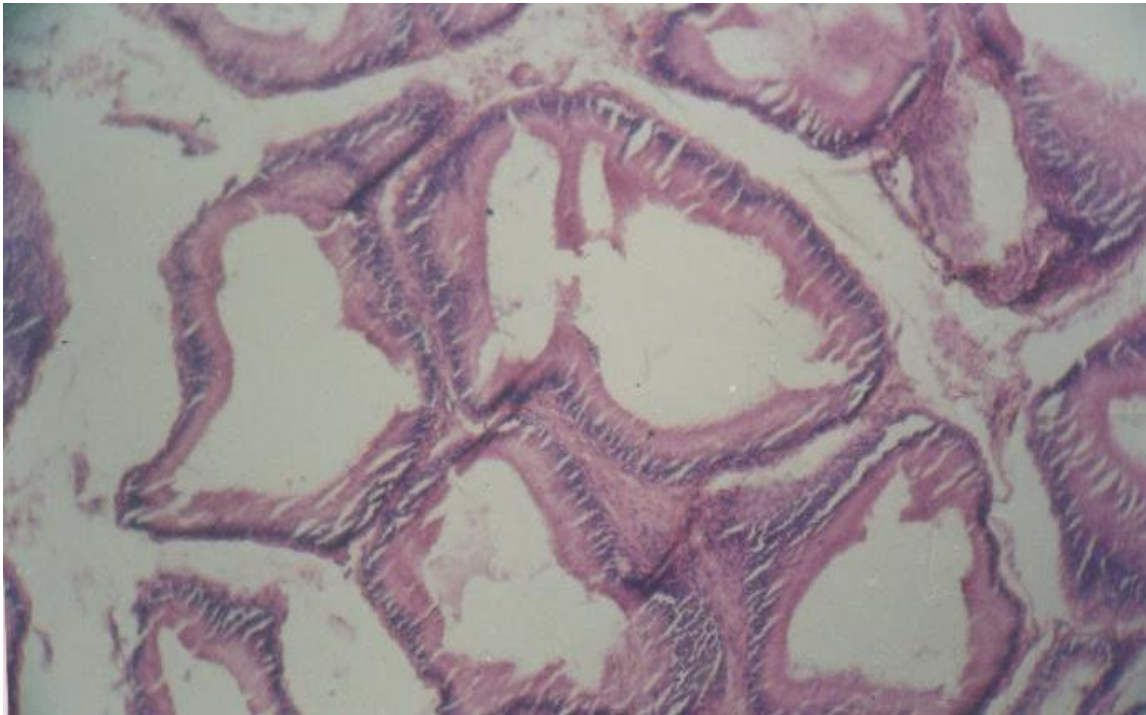


Figure.3 Photomicrograph showing transverse histological section of corpus epididymis of sheep (H&E, X100)

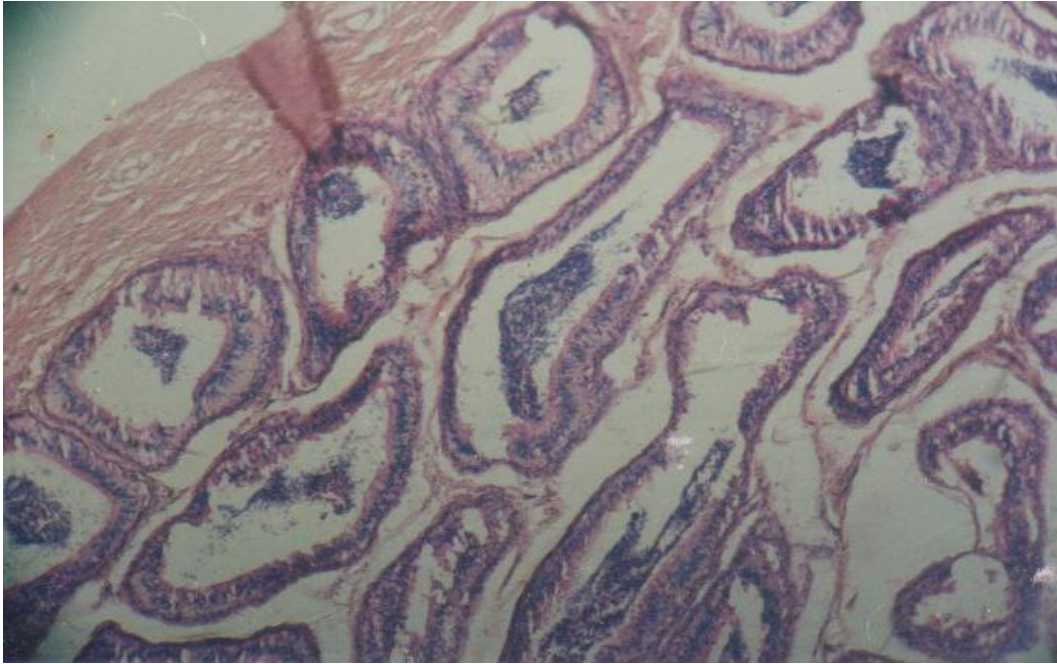
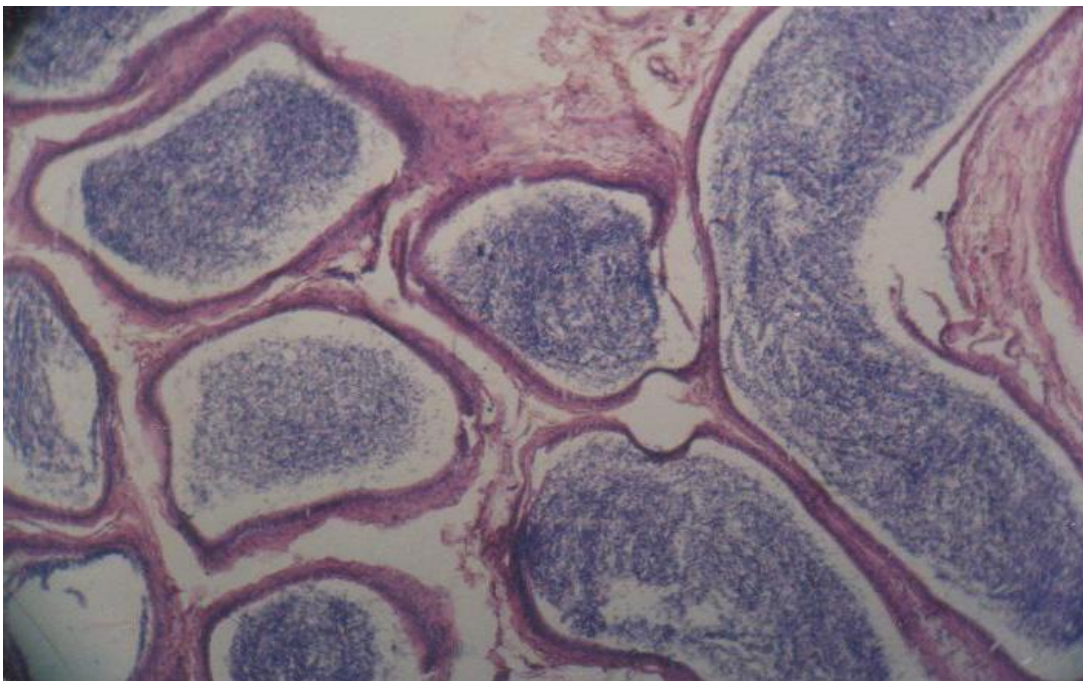


Figure.4 Photomicrograph showing transverse histological section of cauda epididymis of sheep (H&E, X100)



It is concluded thus, this study indicates that the caput with longest stereocilia having

secretory, phagocytic and absorptive function plays a vital role in spermatozoan maturation,

whereas the cauda having the thinnest pseudostratified epithelium with abundant surrounding smooth muscle cells and wider lumen serves well as a storehouse of spermatozoa.

References

- Bedford, J. M. (1975). Maturation, transport & fate of spermatozoa in the epididymis. In: Handbook of Physiology, Vol. V., Section – 6, Am. Phy. Soc., Washington D. C., pp 307.
- Cullin, C. F. A. (1974). Handbook of histopathological and histochemical techniques. Butterworth, Co. Ltd., London, UK.
- Dinakar, R.; Dinakar, N.; Kumar, P.; Talesara, C. L. and Prasad, M. R. N. (1977). Histochemical distribution of phosphatases in different region of the epididymis of the adult rhesus monkey, *Macaca mulatta*. *Indian J. Exp. Biol.* 15: 859.
- Glover, T. D. (1973). Aspects of sperm production in East African mammals. *J. Reprod. Fertil.* 35: 45.
- Humason, G. L. (1972). Animal Tissue Techniques, 3rd edn., W. H. Freeman, Co. Ltd., San Francisco, USA.
- Korman, M. and Reijonen, K. (1976). Microvascular structure of the human epididymis. *Am. J. Anat.* 145(1): 23.
- Nicander, L. and Glover, T. D. (1973). Regional histology and fine structure of the epididymal duct in the golden hamster (*M. auratus*). *J. Anat.* 114: 347.
- O' Conner, J. J. (1980). Dollar's Veterinary Surgery. 4th eds., CBS. Publication and Distributors, Delhi, India.
- Vitale-Calpe, R. and Aoke. A. (1971). The hamster cauda epididymis after coitus. *Acta Anat.* 77: 98.
- Wrobel, K. H. and Fallenbacher, E. (1974). Histological and histochemical studies on the epithelium of the epididymis of the adult boars. *Zuchththygiene*, 9(1): 20.

How to cite this article:

Sengupta, D., K. Ray, C. S. Azad and Sheetal, S.K. 2020. Histological Differences in the Three Epididymal Regions of Sheep (*Ovis aries*) in Relation to Spermatozoan Maturation. *Int.J.Curr.Microbiol.App.Sci.* 9(07): 2018-2022. doi: <https://doi.org/10.20546/ijcmas.2020.907.232>