

Original Research Article

<https://doi.org/10.20546/ijcmas.2020.904.137>

A Study on Histomorphology of Adrenal Gland in Broiler Chickens Subjected to Cold Stress and its Ameliorating Remedies

Saim Qureshi^{1*}, H. M. Khan¹, Sana Shafi², M. S. Mir³, S. Adil¹ and A. A. Khan³

¹Division of Livestock Production and Management, Faculty of Veterinary Sciences and Animal Husbandry, Shuhama, SKUAST-K, Kashmir, India

²Department of Environmental Sciences, S.P. College, Cluster University Srinagar, India

³SKUAST-K, Kashmir, India

*Corresponding author

ABSTRACT

Environmental stress causes structural changes in adrenal gland. Therefore the present study was undertaken to evaluate the histomorphology of adrenal gland in broiler chicken subjected to cold stress and its various ameliorating remedies. 270 day-old commercial broiler chicks were used for the study. The chicks were distributed into 7 treatments of 3 replicates with 13 chicks each. Cold stress was provided at 2°C to 8°C for 8 hours from 3rd to 6th week of age in all treatment groups except first and fifth treatment groups. The broiler birds in T₁ and T₅ were reared under normal temperature conditions (25°C). T₁ was kept as control group. Antioxidant vitamin E 250 mg per kg of feed was supplemented to basal diet in T₃. Chromium 0.1 gram per kg of feed was supplemented to basal diet in T₄. The results revealed that adrenal glands from T₁ showed no shift from normal histology. Adrenal gland from T₅ group revealed similar histology as in control group. The adrenal gland from T₂ group revealed severe hypertrophy of cells. Hyperaemia was also observed on histological examination. There was severe depletion of lipid content in cortical cells. There was also seen severe distortion of architecture of adrenal cells. The adrenal gland from T₃ group revealed mild changes in terms of hyperaemia and hypertrophy of cells. T₄ group showed moderate changes in adrenal gland on histological examination. T₇ group revealed mild changes in terms of hyperaemia, hypertrophy of cells and lipid depletion in cortical cells. T₆ group also showed mild changes. In conclusion, the cold stress mitigating remedies such as early cold conditioning, supplementation of vitamin E or chromium reduced the pathological effects of cold stress in this organ.

Keywords

Adrenal gland, Cold stress, Broiler chicken, Chromium, Vit E.

Article Info

Accepted:

10 March 2020

Available Online:

10 April 2020

Introduction

Stress caused due to cold temperature is a common environmental factor in the northern region of the globe which reduces the performance, immunity and reproduction activities of broiler birds and even causes death (Fu *et al.*, 2013; Olfati *et al.*, 2018). There is a range of environmental temperature

in broiler birds called as zone of thermo-neutrality in which broiler chickens maintain a normal body temperature and beyond the upper or lower limit of this thermoneutral zone, the broiler birds are subjected to stress (Qureshi *et al.*, 2018). The broiler chicks are exposed to cold conditions from time to time because of sudden changes in environmental temperature.

The cold environmental condition associated with poor housing increases the risk of significant economic loss to the producer. The cold stress increases mortality and results in reduced profitability (Yardimci *et al.*, 2006). In a stress reaction, there is an activation of a major neuroendocrine mechanism called hypothalamic–pituitary–adrenal (HPA) axis, which increases blood circulating levels of corticotrophin (ACTH) and subsequently increases adrenal corticoids in the blood for successful adaptation (Kober *et al.*, 2012).

The adrenal glands are important organs. The right adrenal gland in adult chicken is roughly pyramidal in shape with a caudally pointing apex and the left adrenal gland is less constant in shape (Kober *et al.*, 2012). They help to maintain homeostasis as well as play important role in all types of stress by producing hormones.

The hormone production within the avian adrenal gland occurs in a divided cortex that produces glucocorticoids (corticosterone) and mineralocorticoids (aldosterone) and an adrenal medulla that produces catecholamines (norepinephrine and epinephrine) (Kober *et al.*, 2012).

The increase in ACTH secretion due to stress, exert tropic (short-term) and trophic (long-term) effects on the adrenal cortex (Koko *et al.*, 2004). The tropic effect involves an immediate increase in corticosteroid hormone secretion. The trophic effect of ACTH involves an increase in adrenal mass and in the steroidogenic capacity of adrenocortical cells (Koko *et al.*, 2004).

The cold stress also decreases serum concentrations of some vitamins, minerals and insulin while increases serum corticosterone in poultry (Ozdemir *et al.*, 2011). During stress, a deficiency of the antioxidants like vitamin E or decrease in

defensive enzyme activities may cause irreparable and severe oxidant damage to cells (Ozdemir *et al.*, 2011). Antioxidants like vitamin E are used in the poultry diet because of their anti-stress effects and also due to the fact that their synthesis is reduced during stress. Supplementing antioxidant like vitamin E is an effective way of alleviating the adverse effects of stress on poultry production (Kucuk *et al.*, 2003).

When the temperature is above or below thermoneutral zone, corticosteroid secretion increases as a response to stress. Therefore by decreasing synthesis and secretion of corticosteroids, antioxidants alleviate the negative effects of cold stress (Kucuk *et al.*, 2003). It was also reported that corticosteroids cause chromium depletion in the body of organisms during stress (King *et al.*, 2016). Chromium supplemented broiler birds have lower levels of blood corticosteroids so they suffer less from negative effects of stress (Zha *et al.*, 2009).

At an early age short-term cold conditioning of chicks cause an improvement in thermotolerance and performance when these broiler chickens were subjected to cold stress in latter part of their lives (Shahir *et al.*, 2012) due to epigenetic adaptations (Shinder *et al.*, 2011). Therefore, early cold conditioning of broiler chicks can be one of the important remedy to reduce negative effects of cold stress.

As environmental stress produces structural changes in adrenal gland (Ozdemir *et al.*, 2011) and not much literature is available regarding the effect of cold stress on histomorphology of adrenal gland, therefore, the present study was conducted to investigate the effect of cold stress and its various ameliorating measures on the histomorphology of adrenal gland in broiler chickens.

Materials and Methods

From a reputed source, two hundred and seventy (273) day-old commercial meat type broiler chicks were procured. Until 14 days of age, the chicks were reared in battery cages. All the birds were provided with a pre-starter mash (23% crude protein) during the first seven days period. The birds were provided starter (crude protein 22%) diet for second and third week of their age while finisher (crude protein 19%) diet for fourth, fifth and sixth week of their age.

The diets were isonitrogenous, isocaloric and formulated to meet the recommendations of the Bureau of Indian standards (BIS, 2007). Birds were maintained on a constant 24-hour light schedule and had free access to feed and water throughout the growth period. All chicks were vaccinated against Ranikhet disease on 5th day with F1 strain vaccine and IBV-95 vaccine against infectious bursal disease on 16th day. Chicks were checked twice daily for mortality, if any.

On commercial chicks, a biological trial was conducted during the winter months (December and January) in the farm of division of Livestock Production and Management, Faculty of Veterinary Sciences at Shuhama, SKUAST-K, Jammu and Kashmir. At third and fourth day of age, cold conditioning (2°C to 8°C) for 3-4 hours was provided to 78 birds. These early cold conditioned birds were kept separate, until distributed into respective treatment groups (fifth and sixth).

At the end of second week (on fourteenth day), the chicks were individually weighed, distributed into seven treatment groups of three replicates, with 13 chicks in each replicate in a completely randomized design so that the treatment means differ as little as possible. From third week of age to sixth

week of their age, cold challenge was provided at 2 °C to 8 °C for 8 hours for all treatment groups except first and fifth treatment groups. The broiler birds in the treatment groups T₁ and T₅ were reared under normal temperature conditions (25 °C). Treatment group first (T₁) was kept as control group. In the third treatment group, antioxidant vitamin E at 250 mg per kg of feed was supplemented to the basal diet.

Supplementation of chromium at 0.1 gram per kg of feed was done to the basal diet in the fourth treatment group. Chromium at 0.2 gram per kg of feed was added as a supplement to the basal diet in the seventh treatment group. E-Care (Vitamin E) from Gujarat Liqui Pharmacaps India was source of Vitamin E. Chromisac from Zeus Biotech Limited India was source of chromium. The birds were reared on deep litter system throughout the experimental period. The second treatment group was subjected to cold stress and no cold stress mitigation measures of any kind were applied to the broiler birds in this group (Table 1).

The tissue samples from adrenal gland from the slaughtered birds (6 birds per treatment) were collected for the histopathological analysis, at the end of experimental period (42 days). The tissue samples were fixed in 10% buffered formalin saline. Tissues were dehydrated by immersing through a series of alcohols of increasing concentrations (from 70% to absolute), infiltrated with xylene, and embedded in paraffin.

The casting of blocks was carried out in L-molds (two L-shaped pieces) which facilitated the manipulation of size as per the requirement. The rotary type microtome was used for cutting the paraffin sections. The blocks were properly trimmed, and the sections of 5 mm thickness were cut. Continuous ribbons (6-7 inches long) of the

material were cut and laid on the surface of constant temperature water bath (around 55°C). The sections were separated with a heated scalpel after they spread completely. The cut sections were mounted on the clean glass slides using Mayer's egg albumin as the section adhesive. The mounted slides were dried in paraffin oven at 60°C for 1 hour. The tissue sections were stained by the Harris hematoxylin and eosin staining method (Lunas, 1968). The paraffin sections were deparaffinized with the xylene before hydration through graded alcohol to distilled water.

This was followed by the dehydration in ascending grades of alcohol. The clearing was performed in the xylene, and a drop of distrene plasticizer xylene mountant was placed on a coverslip and the section on the slide pressed on it. The slide was inverted, and the cover slip was pressed with a rod to remove the air bubbles if any trapped.

The prepared slides were observe at a magnification of $\times 20$ under a light microscope fitted with the stage micrometer. The study was conducted after approval of research committee and institutional ethical committee (Registration no: 1809/GO/ReBi/S/15/CPCSEA).

Results and Discussion

Table 2 presents the effect of cold stress and its various mitigating remedies on histology of adrenal gland in broiler chicken. The adrenal glands from (T₁) showed no shift from normal histology. There were no signs of hyperaemia or hypertrophy of adrenal cells.

The adrenal gland retained the normal architecture of cells (Figure 1). Adrenal gland from T₅ group revealed similar histology as in control group. There were not found any signs of hyperaemia and hypertrophy of adrenal

cells. Normal architecture of cells was retained (Figure 5). The adrenal gland T₂ group revealed severe hypertrophy of cells. Hyperaemia was also observed on histological examination. There was severe depletion of lipid content in cortical cells. There was also seen severe distortion of architecture of adrenal cells (Figure 2). The adrenal gland from broiler birds of T₃ group revealed mild changes in terms of hyperaemia and hypertrophy of cells. There was seen mild distortion of architecture of adrenal cells (Figure 3).

Treatment group (T₄) under cold stress showed moderate changes on histological examination. There was moderate hyperaemia, hypertrophy of cells and lipid depletion in cortical cells (Figure 4). Broiler chickens from T₇ group revealed mild changes in terms of hyperaemia, hypertrophy of cells and lipid depletion in cortical cells.

There was mild shift from the normal architecture of adrenal cells (Figure 7). T₆ group showed mild changes. There was seen mild hyperaemia and hypertrophy. There was seen mild depletion of lipid in cortical cells. Mild distortion of normal architecture of adrenal cells was observed on histology (Figure 6).

The adrenal glands from control group in which broiler birds were reared under normal temperature conditions (T₁) and T₅ group where early cold conditioning followed normal rearing showed no shift from normal histology. There were no signs of hyperaemia or hypertrophy of adrenal cells. The adrenal gland retained the normal architecture of cells. The normal temperature of rearing broiler chickens maintains normal physiological functions without any change in neuroendocrine system so there is no change in histomorphology of adrenal gland (Olfati *et al.*, 2018).

The adrenal gland from broiler birds reared under cold challenge without any stress mitigating practice (T₂) revealed severe hypertrophy of cells. Hyperaemia was observed on histological examination.

There was severe depletion of lipid content in cortical cells. There was also seen severe distortion of architecture of adrenal cells. Zikic *et al.*, (2011) studied the histology of adrenal gland of broiler chickens reared under prolonged sound stress. Histology of adrenal glands of broiler chickens exposed to sound stress reveal marked hyperaemia, hypertrophy of cells when compared with the histology of adrenal gland of control group (Zikic *et al.*, 2011). There is hypertrophy of cells, distortion of normal architecture of cells and hyperaemia in adrenal gland due to stress in rats (King *et al.*, 2016). Muller *et al.* (2015) investigated the effect of stress on histology of adrenal gland in broiler chickens.

They reported hyperaemia of the tissue and hyperactivity of adrenal cells due to stress in broiler chickens. The histology of adrenal glands of rats under stress reveals distortion of the cords, loss of architecture, swelling in cortical region and lipid depletion in cells (Nachankar *et al.*, 2005). The changes in the histology of adrenal gland of broiler chickens reared under stress may be attributed to activation of hypothalamic-pituitary-adrenal axis due to stress which releases ACTH (adrenocorticotrophic hormone) in excess to stimulate adrenal gland to increase size and release more cortisol in the blood (King *et al.*, 2016). The adrenal gland from treatment group where broiler birds under cold stress were supplemented with vitamin E @ 250mg/kg of feed (T₃) revealed mild changes in terms of hyperaemia and hypertrophy of cells. There was seen mild distortion of architecture of adrenal cells. There was seen improvement in the histology of T₃ group when compared with T₂ group. Ozdemir *et al.*

(2011) studied the effect of supplementation of vitamin E on the histology of adrenal gland in quails reared under heat stress. There is reduction in hyperaemia and improvement in cell architecture of adrenal gland due to vitamin E supplementation (Ozdemir *et al.*, 2011). The beneficial effects of vitamin E on the adrenal gland of broiler chickens reared under cold stress may be attributed to its anti-oxidant activity which reduces stress (Watson and Petro, 1982). Treatment group under cold stress but supplemented with chromium @ 0.1 g/kg of feed (T₄) showed moderate changes on histological examination. There was moderate hyperaemia, hypertrophy of cells and lipid depletion in cortical cells.

Broiler chickens reared under cold stress and supplemented with chromium @ 0.2 g/kg of feed in the diet (T₇) revealed mild changes in terms of hyperaemia, hypertrophy of cells and lipid depletion in cortical cells. There was mild shift from the normal architecture of adrenal cells. T₇ group revealed improvement in histology of adrenal gland as compared to T₂ group. The beneficial effects of chromium on adrenal glands of broiler chickens reared under cold stress may be attributed to the role of chromium as an anti-oxidant and activator of insulin which improves metabolism and reduces stress (Farag *et al.*, 2017).

Early cold conditioned birds under cold stress (T₆) showed mild changes. There was seen mild hyperaemia. The adrenal cells had mild hypertrophy. There was seen mild depletion of lipid in cortical cells. Mild distortion of normal architecture of adrenal cells was observed on histology. The histological examination of adrenal gland in T₆ group revealed improvement when compared with T₂ group. The improvement in the adrenal gland may be attributed to increase in resistance against cold due to early cold conditioning which reduces stress (Shahir *et al.*, 2012; Qureshi *et al.*, 2018).

Table.1 Treatments details of experimental plan

Treatment	Details
T ₁	Broiler chickens reared under normal temperature conditions.
T ₂	Broiler chickens reared under cold stress conditions
T ₃	Broiler chickens reared under cold stress and supplemented with vitamin E @ 250 mg/kg of feed
T ₄	Broiler chickens reared under cold stress and supplemented with chromium @ 0.1 g/kg of feed
T ₅	Broiler chickens provided early cold conditioning followed by rearing under normal temperature conditions.
T ₆	Broiler chickens provided early cold conditioning followed by rearing under cold stress conditions.
T ₇	Broiler chickens reared under cold stress and supplemented with chromium @ 0.2 g/kg of feed

Table.2 Histology of adrenal gland in broiler chickens reared under different treatment conditions

Characteristics	T ₁	T ₂	T ₃	T ₄	T ₅	T ₆	T ₇
Hyperaemia	-	+++	+	++	-	+	+
Hypertrophy of cells	-	+++	+	++	-	+	+
Depletion of lipid content in cortical cells	-	+++	+	++	-	+	+
Distortion of Normal architecture	-	+++	+	++	-	+	+

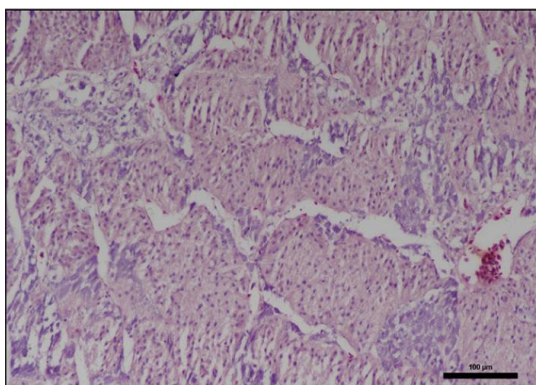


Fig.1 Histological section of Adrenal gland from control group T1 (H&E 20X)

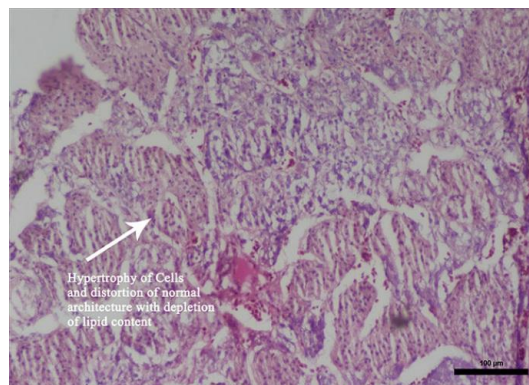


Fig.2 Histological section of Adrenal gland from T2 showing severe hypertrophy of cells and distortion of normal architecture with depletion of lipid content (H&E 20X)

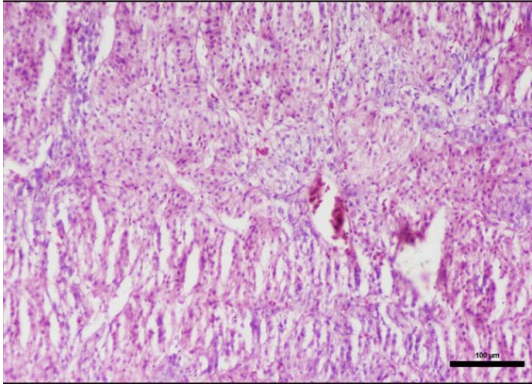


Fig.3 Histological section of Adrenal gland from T3 showing moderate hypertrophy of cells and distortion of normal architecture with depletion of lipid content (H&E 20X)

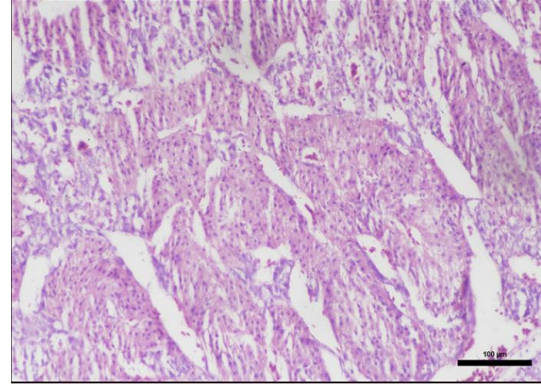


Fig.4 Histological section of Adrenal gland from T4 showing severe to moderate hypertrophy of cells and distortion of normal architecture with depletion of lipid content (H&E 20X)

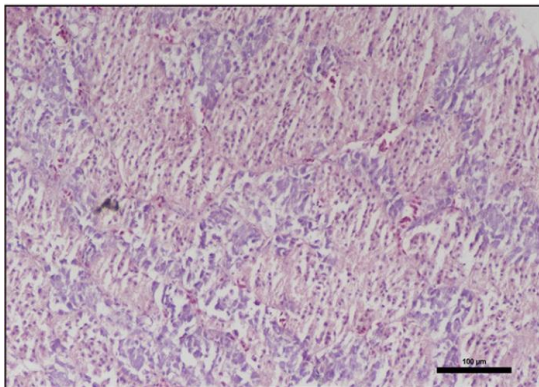


Fig.5 Histological section of Adrenal gland from control group T5 (H&E 20X)

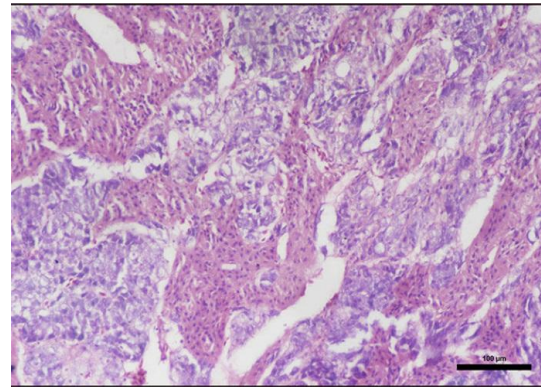


Fig.6 Histological section of Adrenal gland from T6 showing moderate hypertrophy of cells and distortion of normal architecture with depletion of lipid content (H&E 20X)

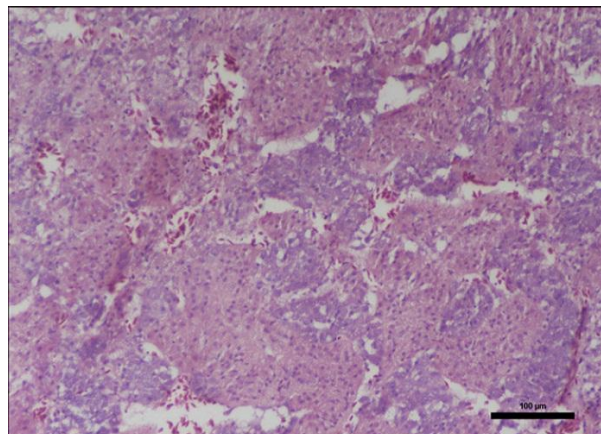


Fig.7 Histological section of Adrenal gland from T7 showing moderate hypertrophy of cells and distortion of normal architecture with depletion of lipid content (H&E 20X)

In conclusion, severe histomorphological /pathological changes were observed in the histological sections of adrenal glands of the broiler chickens reared under cold stress conditions. But the cold stress mitigating remedies such as early cold conditioning, supplementation of vitamin E or chromium reduced the pathological effects of cold stress in this organ.

References

- BIS (Bureau of Indian standards). (2007) Nutrient requirement of Poultry IS1374: 2007.
- Farag, M.R., Alagawany, M., Arif, M. and Ayasan, T. (2017) Role of Chromium in Poultry Nutrition and Health: Beneficial Applications and Toxic Effects. *Int. J. Pharmacol.*, 3(7): 907-915.
- Fu, J., Liu, C.P., Zhang, Z. W., Liao, W. and Xu, S.W. (2013) Effects of acute and chronic cold stress on expression of cyclooxygenase-2 and prostaglandin E synthase mRNA in quail intestine. *Pak. Vet. J.*, 33(3): 358-363.
- King, H.H., Wang, H.C., Chen, K.S. and Lee, W.M. (2016) Trivalent Chromium Attenuated Corticosterone Secretion and Actions in Adrenocorticotrophic Hormone-Stimulated Rats. *Pak. Vet. J.*, 36(1): 41-44.
- Kober, A.K., Humayun, M., Masato, A. and Shoei, S. (2012) Morphological and Histological Studies on the Adrenal Gland of the Chicken (*Gallus domesticus*). *J. Poult. Sci.*, 49(1): 39-45.
- Koko, V., Jelena, D., Gordana, C. and Vukosava, D. (2004) Effect of acute heat stress on rat adrenal glands: a morphological and stereological study. *J. Exp. Biol.*, 207: 4225-4230.
- Kucuk, O., Sahin, N., Sahin, K., Gursu, M.F. and Gulcu, F. (2003) Egg production, egg quality, and lipid peroxidation status in laying hens maintained at a low ambient temperature (6°C) and fed a vitamin C and vitamin E-supplemented diet. *Vet. Medic. Czech.*, 48 (1-2): 33-40.
- Lunas, L.G. (1968) Manual of Histologic staining methods of the Armed forces, Institute of pathology, Third edition New York, McGraw Hill Book Company.
- Muller, B.R., Hisly, A. S.M. and Renato, S. (2015) Chronic welfare restrictions and adrenal gland morphology in broiler chickens. *Poult. Sci.*, 94(4): 574-578.
- Nachankar, R.S., Juvekar, A.R. and Sonawane, A. (2005) Prevention of cold stress induced adrenal hypertrophy by *Spirulina plantesis*. *Trad. Med. Nutr.*, 6(3): 101-107.
- Olfati, A., Mojtahedin, A., Sadeghi, T. and Akbari, M. (2018) Comparison of growth performance and immune responses of broiler chicks reared under heat stress, cold stress and thermoneutral conditions. *Span. J. Agric. Res.*, 16(2): 1-7.
- Ozdemir, D., Ozudogru, Z., Imik, H. and Can, M. (2011) Effects of dietary antioxidant supplementation on the adrenal glands in quails (*Coturnix coturnix japonica*) reared under heat stress. *Rev. Med. Vet.*, 162(1): 8-12.
- Qureshi, S., Musadiq, K. H, Saleem, M. M., Ahmad, R. T., Alam, K. A., Ali, H and Adil, S. (2018) Effect of Cold Stress and Various Suitable Remedies on Performance of Broiler Chicken. *J. World's Poult. Res.*, 8(3): 66-73.
- Shahir, M.H., Dilmagani, S. and Tzschentke, B. (2012) Early-age cold conditioning of broiler chickens: effects of timing and temperature. *Brit. Poult. Sci.*, 53(4): 538-544.
- Shinder, D., Ruzal, M., Giloh, M., Druyan, S., Piestun, Y. and Yahav, S. (2011) Improvement of cold resistance and

- performance of broilers by acute cold exposure during late embryogenesis. *Poult. Sci.*, 90(3): 633-641.
- Watson, R.R. and Petro, T.M. (1982) Cellular immune response, corticosteroid levels and resistance to *Listeria monocytogenes* and murine leukemia in mice fed a high vitamin E diet. *Ann. New York Acad. Sci.*, 393(1): 205-210.
- Yardimci, M., Sengo, E., Sahin, E. H. and Bayram, I. (2006) The influence of cold conditioning on the performance of the broiler chicken. *Turk. J. Vet. Anim. Sci.*, 30(5): 583-588.
- Zha, L.Y., Zeng, I.W., Chu, X.W., Mao, L.M. and Luo, H.J. 2009. Efficacy of trivalent chromium on growth performance, carcass characteristics and tissue chromium in heat-stressed broiler chicks. *Journal of Science Food Agriculture*. 89(10): 1782-1786.
- Zikic, D., Uscebrk, G. and Gledic, D. 2011. The influence of long term sound stress on histological structure of broiler's adrenal glands. *Biotechnology in Animal Husbandry* 27(4): 1613-1619.

How to cite this article:

Saim Qureshi, H. M. Khan, Sana Shafi, M. S. Mir, S. Adil and Khan, A. A. 2020. A Study on Histomorphology of Adrenal Gland in Broiler Chickens Subjected to Cold Stress and its Ameliorating Remedies. *Int.J.Curr.Microbiol.App.Sci*. 9(04): 1160-1168.
doi: <https://doi.org/10.20546/ijcmas.2020.904.137>