

Original Research Article

<https://doi.org/10.20546/ijcmas.2020.903.310>

## Evaluation of Microfilaricidal Efficacy of Doxycycline, Ivermectin and Selamectin in Dogs Naturally Infected with *Dirofilaria repens*

D. S. Malatesh\*, C. Ansar Kamran, K. J. Ananda, K. Ganesh Udupa,  
Ramesh, P.T. Suguna Rao and N. B. Shridhar

Department of Veterinary Medicine, Veterinary College, KVAFSU, Shivamogga-577 204  
Karnataka, India

\*Corresponding author

### ABSTRACT

The present study was conducted to evaluate the microfilaricidal efficacy of doxycycline, ivermectin and selamectin in dogs naturally infected with *D. repens*. A total of eighteen dogs positive for microfilaria by modified Knott's method were included in the study. The species of microfilaria was identified as *D. repens* based on the morphology and micrometry by modified Knott's and Giemsa's staining technique. The dogs were divided in to doxycycline, ivermectin and selamectin group with six dogs in each group. The drugs were administered as per standard protocol. The blood samples of dogs from all three groups were analysed for microfilarial count before treatment (0 day), 7<sup>th</sup> and 14<sup>th</sup> day of post-treatment. The study demonstrated that, the dogs treated with selamectin showed significant reduction in the microfilarial count from 0 day to 14<sup>th</sup> day with complete elimination of microfilaria in few dogs followed by ivermectin group which also showed significant reduction in the microfilarial count but, without complete removal of microfilaria in any of the dogs in the group. Even though, decrease in the microfilarial count was observed in dogs treated with doxycycline, they were ineffective in reducing the number of microfilaria significantly.

#### Keywords

Microfilaricidal,  
*D. repens*, Efficacy,  
Doxycycline,  
Ivermectin,  
Selamectin, Dogs

#### Article Info

Accepted:  
20 February 2020  
Available Online:  
10 March 2020

### Introduction

Microfilariosis in dogs is caused by several species of filarid nematodes viz *Dirofilaria immitis*, *D. repens*, *Acanthocheilonema* spp. *Brugia* spp etc. Among these *D. immitis* is the

most pathogenic canine filarid nematode that causes heartworm disease in dogs whereas, *D. repens* is responsible for subcutaneous dirofilariosis. Even though *D. repens* is considered as less pathogenic in dogs, the ability to infect humans makes it as zoonotic

important parasite. The *D. immitis* is distributed worldwide and endemic in North, Central and South America, Africa, southern Europe and Asia whereas, *D. repens* is widely distributed throughout Europe, Asia and Africa, with higher prevalence reported from Sri Lanka, Iran and Italy (Tarello, 2002). Most common filarial species reported in India are *D. immitis*, *D. repens*, *Acanthocheilonema* spp. and *Brugia* spp. They are distributed in various parts of India, mainly Kerala, Tamil Nadu, Karnataka, Orissa, West Bengal, Bihar, Uttar Pradesh and Maharashtra (Ravindran *et al.*, 2014).

Different techniques are used for detection and identification of microfilariae with varying degree of sensitivity and reliability. But concentration techniques appear to be the best in detection of low level infections according to Wylie (1970). Diagnosis of dirofilariosis in dogs is mainly performed by conventional tests viz., wet blood film method, modified Knott's technique, Giemsa's staining, histochemical staining technique, citrate-saponin-acid method and quantitative buffy coat technique for detection of microfilariae in blood.

Successful treatment and management of canine filariosis require a thorough understanding of the life cycle, the host parasite relationship and the susceptibility of various parasite stages to microfilaricidal and adulticidal drugs. The goal of any treatment is to improve the clinical condition of the animal and to eliminate all adult worms and developmental stages with minimal post treatment complications (Nelson, 2011).

Filarial infections can be treated either by adulticidal or microfilaricidal drugs. Presently arsenical-based drug like Melarsomine dihydrochloride is the only available adulticidal drug approved by Food and Drug Administration (FDA). Most commonly used

microfilaricidal drugs are macrocyclic lactones (ivermectin, milbemycin oxime, moxidectin, and selamectin). Recently, antibiotic therapy with doxycycline has shown good efficacy against both human and animal filarial worms, based on the hypothesis that, the bacterial endosymbiont *Wolbachia* represents a suitable target (Bazzocchi *et al.*, 2008).

## **Materials and Methods**

The blood samples were examined for detection of microfilariae by modified Knott's method as per Lindsey (1965). The identification of microfilaria was done by morphology and micrometry by modified Knott's method and Giemsa's staining technique. A total of eighteen animals found positive for microfilaria by modified Knott's method were divided in to three groups viz., doxycycline, ivermectin and selamectin group. The drugs were administered as per the standard protocol (Table 1). The blood samples of dogs from all three groups were analysed for microfilarial count before treatment (0 day), 7<sup>th</sup> and 14<sup>th</sup> day of post-treatment

Enumeration of microfilariae was done as per the method employed by Bazzocchi *et al.*, (2008) similar to modified Knott's method. One ml of blood was mixed with 10 ml of 2% buffered formalin and centrifuged for 5 min at 1000 rpm. One hundred microliter of sediment was mixed with equal parts of 1:1000 methylene blue stain. Twenty microliter of stained sediment was placed on a slide, covered with a cover slip and examined under a microscope. The number of microfilaria was counted, multiplied by 10 and expressed as mf/ml.

The efficacy of the drugs has been calculated based on the per cent of reduction in microfilarial count after the end of the

treatment trail by following the formula:

$$\text{Efficacy of drug} = Z \times 100 / X$$

Where, X- no. of microfilariae/ml of blood before treatment

Y- no. of microfilariae/ml of blood by 14<sup>th</sup> day post treatment

Z- no. of microfilariae reduction /ml of blood (X-Y)

## Results and Discussion

The microfilariae in modified Knott's method were unsheathed, with blunt head and a tapering tail (Fig. 1). In Giemsa stained blood smear, the cuticle appeared to be striated in higher magnification. Hook muscle cells could be appreciated near the head. The nerve ring and excretory cell at the excretory pore region of the microfilaria could be well appreciated. The tail was long and tapering, leaving a clear space at the end (Fig. 2). The biometrical studies revealed that, the lengths of the microfilaria were in the range of 298 to 312µm and widths in the range of 8.6 to 10.5µm. Based on morphology and micrometry, the microfilariae were identified as *Dirofilaria repens* as per the descriptions of Soulsby (2005) and Bowman (2014).

The group-I had microfilarial count of 65.17±1.47, group-II 35.33±1.75 and group-III showed 66.83±2.32 (microfilaria/ml of blood) on day zero. Group-I dogs treated with oral doxycycline showed significant (P<0.05) decrease in microfilarial count on day 7 (41.17±1.47) and further decrease on day 14 (23.17±1.47). The significant (P<0.05) decrease in microfilarial count by day 7 (19.67±1.37) was observed in group-II dogs treated with ivermectin subcutaneously. The

second injection of ivermectin further reduced the microfilarial count significantly to 5±0.63 microfilaria/ml of blood on day 14. Topical application of selamectin to group-III dogs decreased the microfilarial count significantly (P<0.05) to 18.33±1.63 microfilaria/ml of blood on day 7 and on day 14 microfilarial count reduced significantly to 0.67±1.03 microfilaria/ml of blood with few dogs showed nil microfilaria in the blood (Fig. 3).

In the present study, among three groups, the dogs treated with selamectin showed significant reduction (98.99%) in the microfilarial count from 0 day to 14<sup>th</sup> day with complete removal of microfilaria in few dogs followed by ivermectin group which also showed significant reduction (85.71%) in the microfilarial count without complete removal of microfilaria in any of the dogs in the group. Even though, decrease in the microfilarial count was observed in dogs treated with doxycycline (64.61%), they were ineffective in reducing the number of microfilaria significantly (Table 2).

The previous studies reported that, evaluation of ivermectin @ 0.2 or 0.3 mg/kg b. wt. s/c once in 2 weeks for two to three injections in cases of dermatitis associated with microfilariae in 10 dogs from western United States showed improvement in seven dogs by second injection and by fourth week, six dogs were almost asymptomatic except with some residual alopecia and scale (Hargis *et al.*, 1999). Similarly Grandi *et al.*, (2010) evaluated the effect of combination of doxycycline @ 10 mg/kg daily for 30 days and ivermectin @ 6 µg/kg once in 15 days for 6 month on microfilaremia in naturally infected dogs with *Dirofilaria immitis* from an endemic region of Italy. By day 90, all dogs (100%) became negative for circulating microfilariae.

**Table.1** Treatment trial protocol

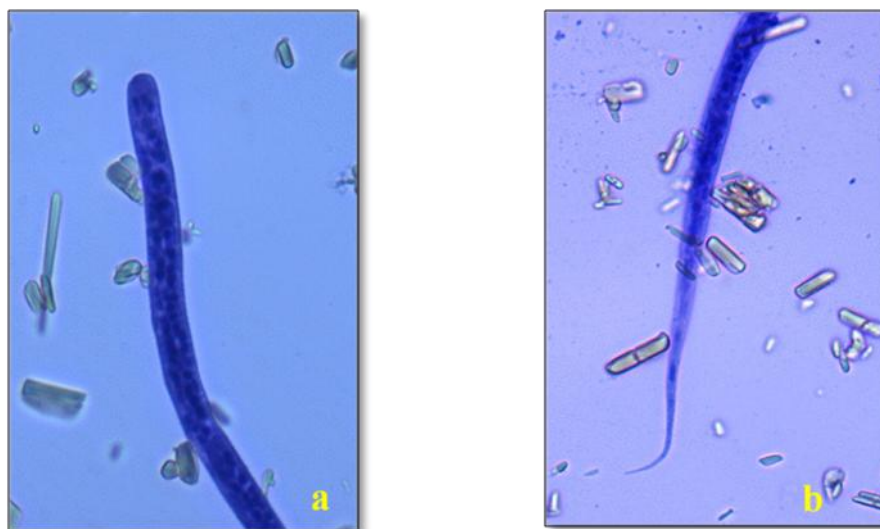
| Sl. No. | Group     | Number of animals | Drug                                  | Dosage                                  |
|---------|-----------|-------------------|---------------------------------------|---|
| 1.      | Group I   | 6                 | Doxycycline (Doxypet <sup>®</sup> )   | 10 mg/ kg po once daily for 14 days     |
| 2.      | Group II  | 6                 | Ivermectin (Neomec <sup>®</sup> )     | 0.02/mg/ kg s/c once a week for 2 weeks |
| 3.      | Group III | 6                 | Selamectin (Revolution <sup>®</sup> ) | 6-12 mg/ kg topical once                |

**Table.2** Microfilarial count (No./ml) in dogs during the course of treatment

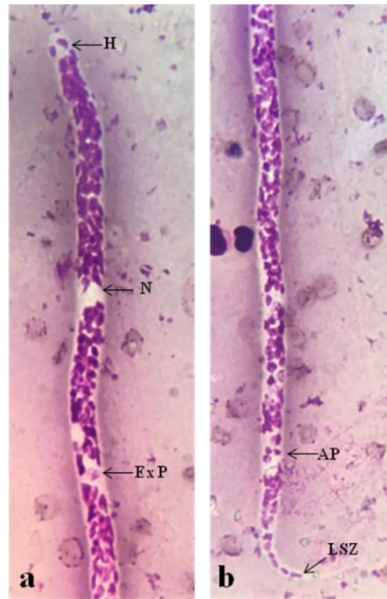
| Sl. No. | Group (n=6) | 0 day                                 | 7 day                                 | 14 day                                | Efficacy (%) |
|---------|-------------|---------------------------------------|---------------------------------------|---------------------------------------|--------------|
| 1.      | Doxycycline | 65.17 ± 1.47 <sup>Aa</sup><br>(63-67) | 41.17 ± 1.47 <sup>Ba</sup><br>(39-43) | 23.17 ± 1.47 <sup>Ca</sup><br>(21-25) | 64.61        |
| 2.      | Ivermectin  | 35.33 ± 1.75 <sup>Ab</sup><br>(33-38) | 19.67 ± 1.37 <sup>Bb</sup><br>(18-22) | 5 ± 0.63 <sup>Cb</sup><br>(4-6)       | 85.71        |
| 3.      | Selamectin  | 66.83 ± 2.32 <sup>Aa</sup><br>(64-70) | 18.33 ± 1.63 <sup>Bb</sup><br>(16-20) | 0.67 ± 1.03 <sup>Cd</sup><br>(0-2)    | 98.99        |

**Note:** Mean±SE values with different superscripts (upper case in column and lower case in row) are significantly different at P<0.05

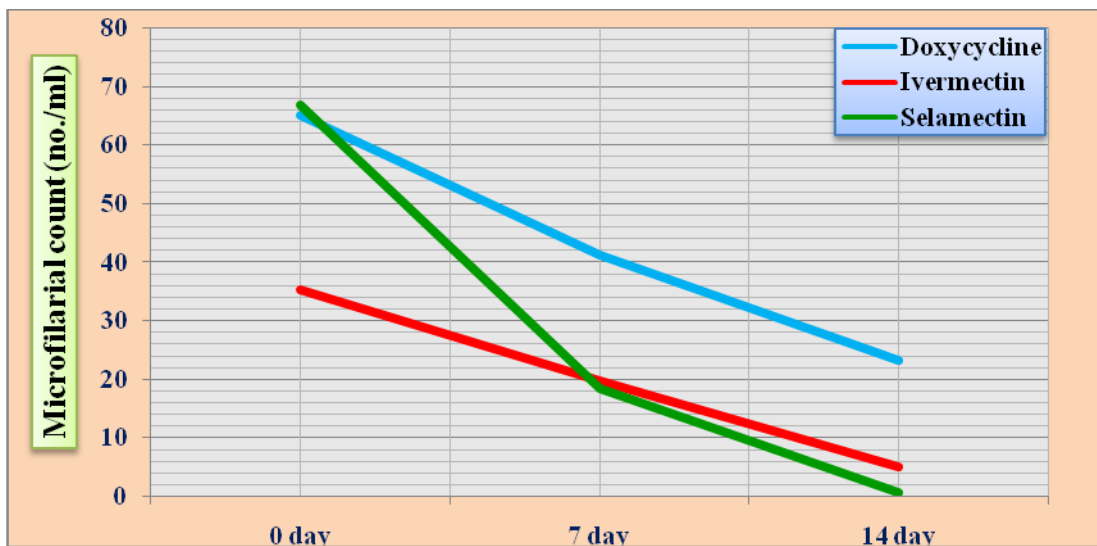
**Fig.1** Microfilaria of *D. repens* in modified Knott's method: unsheathed, (a) blunt head (b) tapering tail (400X)



**Fig.2** Microfilaria of *D. repens* (a) head and (b) tail under Giemsa stained blood smear (1000X) (H- Hook muscle cell; N- Nerve ring; ExP- Excretory pore; AP- Anal pore; LSZ- Last tail cell)



**Fig.3** Microfilarial count (no./ml) in dogs during the course of treatment



Razi Jalali *et al.*, (2011) used combined therapy of ivermectin (440 µg/kg as single dose), Levamisol (10 mg/kg q 24 h for 10 days) and Aspirin (10 mg/kg q 12 h for 10 days) for a case of *Dirofilaria immitis* infection in Dachshund dog from Ahvaz district, Iran. The number of microfilariae

dropped from 1250±50/ml blood pre-treatment to 150±10/ml following the first treatment and reached zero a day after the second treatment. The animal remained negative for *D. immitis* microfilariae during a follow-up period of 180 days and combined therapy was found effective. Moraes-da-Silva

*et al.*, (2016) conducted a study to evaluate the efficacy of selamectin topical application @ 6 mg/kg b. wt. to dogs living in a high risk area in Brazil. The blood samples were collected before the first treatment and at the end of the treatment for detection of microfilariae by the modified Knott's test. All dogs tested negative after receiving monthly topical treatment with selamectin.

Higher efficacy of selamectin and ivermectin as microfilaricidal drugs in the present study might be attributed to the fact that, macrocyclic lactones has effect on embryogenesis of microfilariae within female heartworms and also on developmental stages in the circulation (Lok *et al.*, 1988). Lower efficacy of doxycycline might be due to the fact that, the drug is effective against adult filarid worms (Baneth *et al.*, 2002 and Grandi *et al.*, 2010).

Many researchers used different therapeutic agents against *D. immitis* and *D. repens* infection in dogs either alone or in combination with other drugs (Lok *et al.*, 2005; Fok *et al.*, 2010; Genchi *et al.*, 2010; Razi Jalali *et al.*, 2011; Rocconi *et al.*, 2012; Genchi *et al.*, 2013; McCall *et al.*, 2014; Chandrashekar *et al.*, 2014; Frangipane *et al.*, 2016 and Moraes-da-Silva *et al.*, 2016) and opined that, the combined use of microfilaricide and adulticide drugs are effective compared with either microfilaricide or adulticide drugs alone against filarial infections in dogs.

### Acknowledgement

The Authors are grateful to Department of Veterinary Medicine, Veterinary College Bangalore for providing financial assistance and Department of Veterinary Parasitology, Veterinary College, Shimoga for providing laboratory facility to conduct the present study. The authors are also thankful to Dr.

Yashawi Naravi for his co-operation and help during the present study.

### References

- Baneth, G., Volansky, Z., Anug, Y., Favia, G., Bain, O., Goldstein, R.E., and Harrus, S. 2002. *Dirofilaria repens* infection in a dog: diagnosis and treatment with Melarsomine and Doramectin. *Vet. Parasitol.*, 105: 173–178.
- Bazzocchi, C., Mortarino, M., Grandi, G., Kramerl, H., Genchi, C., Bandi, C., Genchi, M., Sacchi L. and McCall. J.W. 2008. Combined Ivermectin and Doxycycline treatment has microfilaricidal and adulticidal activity against *Dirofilaria immitis* in experimentally infected dogs. *Int. J. Parasitol.*, 38: 1401–1410.
- Bowman, D.D., 2014, Georgis' Parasitology for Veterinarians. 10th edition, W.B. Saunders company, Sidney. Pp. 320-321.
- Chandrashekar, R, Beall, M.J., Saucier, J., O'connor, T., Mccall, J.W. and Mccall, S.D. 2014. Experimental *Dirofilaria immitis* infection in dogs: Effects of Doxycycline and Advantage Multi® administration on immature adult parasites. *Vet. Parasitol.*, 206(1-2): 93-98.
- Fok, E., Jacso, O., Szebeni, Z., Gyorffy, A., Sukosd, L., Lukacs, Z. and Schaper, R. 2010. Elimination of *Dirofilaria* (syn. *Nochtiella*) *repens* microfilariae in dogs with monthly treatments of moxidectin 2.5%/imidacloprid 10% (Advocate®, Bayer) spot-on. *Parasitol. Res.*, 106(5): 1141-1149.
- Frangipane, R.A., Di Cesare, A., Traversa, D., Simonato, G., Poser, H., Danesi, P., Furnari, C., Russi, I., Raele, D.A., Crisi, P., Pampurini, F. and Pietrobelli, M. 2016. Microfilaricidal efficacy of a single administration of Advocate® (Bayer Animal Health) in dogs naturally infected with *Dirofilaria immitis* or *Dirofilaria repens*. *Vet. Parasitol.*, 226: 30-34.
- Genchi, C., Genchi, M., Petry, G., Kruedewagen, E.M. and Schaper, R. 2013. Evaluation of the efficacy of Imidacloprid 10%/Moxidectin 2.5 % (Advocate®,

- Advantage® Multi, Bayer) for the prevention of *Dirofilaria repens* infection in dogs. *Parasitol. Res.*, 112(1): 81-89.
- Genchi, M., Pengo, G. and Genchi, C. 2010. Efficacy of moxidectin microsphere sustained release formulation for the prevention of subcutaneous filarial (*Dirofilaria repens*) infection in dogs. *Vet. Parasitol.*, 170(1-2): 167-169.
- Grandi, G., Quintavalla, C., Mavropoulou, A., Genchi, M., Gnudi, G., Bertoni, G. and Kramer, L. 2010. A combination of Doxycycline and Ivermectin is adulticidal in dogs with naturally acquired heartworm disease (*Dirofilaria immitis*). *Vet. Parasitol.* 169(3-4): 347-351.
- Hargis, A.M., Lewis, T.P., Duclos, D.D., Loeffler, D.G. and Rausch, R.L. 1999. Dermatitis associated with microfilariae (Filarioidea) in 10 dogs. *Vet. Dermatol.*, 10(2): 95-107.
- Lindsey, J.R. 1965. Identification of canine microfilariae. *J. Am. Vet. Med. Assoc.*, 146: 1106-1114.
- Lok, J.B., Harpaz, T. and Knight, D.H. 1988. Abnormal pattern of embryogenesis in *Dirofilaria immitis* treated with Ivermectin. *J. Helminth.*, 62(3): 175-180.
- Lok, J.B., Knight, D.H., Nolan, T.J., Grubbs, S.T., Cleale, R.M. and Heaney, K. 2005. Efficacy of an injectable, sustained-release formulation of moxidectin in preventing experimental heartworm infection in mongrel dogs challenged 12 months after administration. *Vet. Parasitol.*, 128: 129-135.
- McCall, J.W., Arther, R., Davis, W. and Settje, T. 2014. Safety and efficacy of 10% imidacloprid+2.5% moxidectin for the treatment of *Dirofilaria immitis* circulating microfilariae in experimentally infected dogs. *Vet. Parasitol.*, 206(1-2): 86-92.
- Moraes-Da-Silva, M.F., Mendes-De-Almeida, F., Abdalla, L., Merlo, A., Paiva, J.P. and Labarthe, N.V. 2016. Selamectin for the prevention of canine *Dirofilaria immitis* infection: Field efficacy in client-owned dogs in a high risk area. *Parasit. Vectors*, 9(1): 407.
- Nelson, T.C. 2011. Heartworm Disease. In: Greene, E.C. Infectious Diseases of the Dog and Cat. 4th Edn, Saunders, St Louis. pp 865-877.
- Ravindran R, Varghese S, Nair SN, Balan VM, Lakshmanan B, Ashruf RM, Kumar SS1, Gopalan AK, Nair AS, Malayil A, Chandrasekhar L, Juliet S, Kopparambil D, Ramachandran R, Kunjupillai R. and Kakada SA. 2014. Canine Filarial Infections in a Human *Brugia malayi* Endemic Area of India. *Biomed Res Int.*, pp 1-9.
- Razi Jalali, M.H., Mosallanejad, B. and Avizeh, R. 2011. *Dirofilaria immitis* infection in a Dachshund dog: Diagnosis and treatment. *Iran J. Vet. Sci. Tech.*, 3(1): 49-56.
- Rocconi, F., Di Tommaso, M., Traversa, D., Palmieri, C., Pampurini, F. and Boari, A. 2012. Allergic dermatitis by *Dirofilaria repens* in a dog: clinical picture and treatment. *Parasitol. Res.*, 111(1): 493-496.
- Soulsby, E.J.L., 2005. Helminths, Arthropods and Protozoa of Domesticated animals. 7<sup>th</sup> Edn. ELBS Bailliere Tindal, London., pp 306-311.
- Tarello W. 2002. Cutaneous lesions in dogs with *Dirofilaria (Nochtiella) repens* infestation and concurrent tick-borne transmitted diseases. *Vet Dermatol.* 13(5):267-274.
- Wylie, J.P., 1970, Detection of microfilariae by a filter technique. *J. Am. Vet. Med. Assoc.*, 163: 140-141.

#### How to cite this article:

Malatesh, D. S., C. Ansar Kamran, K. J. Ananda, K. Ganesh Udupa, Ramesh, P.T. Suguna Rao and Shridhar, N. B. 2020. Evaluation of Microfilaricidal Efficacy of Doxycycline, Ivermectin and Selamectin in Dogs Naturally Infected with *Dirofilaria repens*. *Int.J.Curr.Microbiol.App.Sci.* 9(03): 2715-2721. doi: <https://doi.org/10.20546/ijcmas.2020.903.310>