

Original Research Article

<https://doi.org/10.20546/ijcmas.2020.901.035>

## Evaluation of Cardiac Troponin - cTnI in Cows with Traumatic Reticulo- Pericarditis

M. Venkatesan<sup>1\*</sup>, P. Selvaraj<sup>2</sup>, M. Saravanan<sup>3</sup>, S. Yogeshpriya<sup>1</sup>,  
K. Jayalakshmi<sup>1</sup>, M. Veeraselvam<sup>1</sup> and N. Premalatha<sup>1</sup>

<sup>1</sup>Department of Veterinary Medicine, Cardiology Referral Clinic, Veterinary College and Research Institute, Orathanadu, Thanjavur, TANUVAS, India

<sup>2</sup>Department of Veterinary Medicine, Madras Veterinary College, Chennai – 07, TANUVAS, India

<sup>3</sup>Veterinary Clinical Complex, Veterinary College and Research Institute, Orathanadu, Thanjavur, TANUVAS, India

*\*Corresponding author*

### ABSTRACT

#### Keywords

cTnI; Bovine; Cow; Traumatic reticulo pericarditis (TRP)

#### Article Info

Accepted:  
15 December 2019  
Available Online:  
20 January 2020

Evaluation of Cardiac Troponin -cTnI was under taken in Nineteen Cross bred diary cows. These are aged between 2.5 to 8 years and presented with the history of jowl and brisket edema to the Cardiology Referral Clinic, Veterinary College and Research Institute, Orathanadu, Thanjavur from June 2018 to May 2019. All the cases were confirmed to be affected by TRP. cTnI was assessed using Point-of-Care immunoassay issuing i-STAT handheld analyser. The affected cows had elevated cTnI ( $0.10 \pm 0.034$  ng / ml) than healthy cows ( $0.027 \pm 0.016$  ng / ml) ( $P < 0.05$ ). Point-of-care cTnI measurement helped as an easy and early diagnostic measure. It helped to assess the nature of myocardial involvement and cell damage in Traumatic reticulo pericarditis affected cows.

### Introduction

In bovines, traumatic pericarditis (TP) is one of the most important cardiac diseases as it causes huge economic losses to farmers in the way of drop-in milk yield as well as mortality. Most of the times, the cases were presented to hospital only in the advanced stages of the

disease where there is cardiac dysfunction which leads to subsequent heart failure (Reef and Mc Guirk, 2002). Clinical cases presented do not always show all the pathognomonic signs of traumatic reticulo pericarditis such as edema of jowl or brisket, bilateral jugular engorgement and positive venous stasis. In veterinary filed heart failure due to traumatic

pericarditis were not diagnosed commonly due to non-availability of appropriate tests. Apart from that the available diagnostic procedures to rule out traumatic pericarditis were not enough for confirmative diagnosis of myocardial damage. The availability of an advanced, non-invasive, time bound, point of care diagnostic tests is currently available. Cardiac biomarkers are now considered to be useful index for the early diagnosis of Traumatic pericarditis (Attia, 2016). This study was aimed at evaluating the cardiac troponin I (cTnI) using Point-of-care immunoassay i-STAT. This marker is elevated during myocardial injury or due to increased pericardial permeability. This test can now be made part of the routine blood profile for early detection of myocardial damage in traumatic pericarditis (TP) affected cows as evidenced from this study.

## Materials and Methods

A total of nineteen crossbred cows aged between 2.5 to 8 years were presented to the Cardiology Referral Clinic, Veterinary College and Research Institute, Orathanadu, Thanjavur from June 2018 to May 2019 with the history of jowl and brisket edema. All animals were clinically assessed and physical examination, feroscopic examination for metal detection of foreign bodies, radiographic and ultrasonographic examination of thorax (Venkatesan *et al.*, 2019. pp.14(3): 73-74) were done. Five ml of blood was collected for haematology, serum biochemistry and cardiac biomarkers. For haematology the samples collected in EDTA vials were analyzed immediately using haematology auto analyzer (VetScan HM5 @ Abbott) as manufacturer instructions. The samples collected in clot activator vials kept without disturbing at room temperature for 1 hr and centrifuged at 3000 rpm for 15 minutes, and the serum was separated and stored at  $-20^{\circ}\text{C}$  until analysed. Serum biochemical activities of Blood Urea

Nitrogen (BUN), Total Protein, Albumin, Glucose, Creatine Kinase -Myocardial band (CK-MB); Alkaline Phosphatase (ALT), Aspartate aminotransferase (AST); Lactate dehydrogenase (LDH), Calcium (Ca), Phosphorus (P) were determined using an autoanalyser with commercially available biochemistry testing kits.

A commercially available human point-of-care lateral flow immunochromatographic test kits (SD Bioline Troponin I<sup>®</sup>, Standard Diagnostics. Inc.) was used to determine qualitatively the concentration of cTn-I as per manufacturer's instruction (Fig.1). cTnI was assessed in serum samples using the Point-of-Care immunoassay i-STAT<sup>®</sup> analyser (Abbott Healthcare Pvt. Ltd) (Fig.2). The data obtained were statistically analyzed using T-test with SPSS software. Significance level was  $P < 0.05$ .

## Results and Discussion

The haematology and serum biochemistry results of TRP affected cows and healthy cows were shown in Table 1 & 2 respectively. The mostly observed abnormality in haematological parameters in this study was increase in the leukocyte count in TRP affected cows than the healthy cows ( $p < 0.01$ ). It possibly indicated the associated infection. Statistically significant differences in Haemoglobin ( $p < 0.01$ ), RBC and in PCV ( $p < 0.05$ ) indicated that the animals were in anaemic state. There was a statistically significant difference between healthy cows and the cows affected with TRP for the levels of BUN, Ca, P ( $P < 0.05$ ), AST, ALT, LDH; CK-MB ( $P < 0.01$ ). Braun *et al.*, (2018) had also reported of similar findings.

Such changes reported in buffaloes included hypoalbuminaemia, an increase of BUN possibly due to low cardiac output to the kidneys, Alanine and Aspartate

aminotransferase (ALT & AST) (Neamat-Allah, 2015). The findings of this study agreed with the previous authors reports that increase in ALT indicated hepatic congestion and that it may had to degenerative changes in liver; increase in AST indicated the involvement of liver and or myocardial muscle ((Braun, 2009; Kaneko *et al.*, 2008). Even though, the present study TP affected cows had high serum activities of Creatinine, Calcium and Phosphorus than the healthy cows the values were within normal range of bovine serum.

Reef and Mc Guirk (2002) reported CK MB and LDH could be increased when heart

muscle is degenerated. The present study also documented that the mean activities of these enzymes were high in cattle with traumatic pericarditis. The human based point-of-care lateral flow immunochromatographic test kits used to determine the concentration of cTn-I was not satisfactory for bovine usage (Fig.1).

These kits are sensitivity of assessing the cTnI at levels more than 0.5 ng / ml. In the present study we got it quantitatively measured and observed maximum of cTnI 0.3 ng / ml by using Point-of-Care immunoassay i-STAT<sup>®</sup> analyser on bovine serum samples.

**Table.1** Haematology parameters of healthy and TRP affected cows

Parameters	Healthy cows (N=10)	TRP affected cows (N=19)
<b>Hb (g/ dl)</b>	8.5 ± 0.26	6.05 ± 0.51**
<b>PCV (%)</b>	21.63 ± 0.73	25.42 ± 1.92*
<b>RBC (mill./cumm)</b>	5.53 ± 0.23	4.79 ± 0.28*
<b>WBC (/ cumm)</b>	6145 ± 807	11471.37 ± 824.10**
<b>N (%)</b>	46.39 ± 2.65	38 ± 2.17*
<b>L (%)</b>	48.04 ± 2.56	53.57 ± 3.36*
<b>M (%)</b>	3.4 ± 0.44	2.8 ± 0.5*
<b>B (%)</b>	1 ± 0.00	1 ± 0.00
<b>E (%)</b>	1.7 ± 0.49	1.37 ± 0.32*

The values are presented Mean ± Standard Error. Hb – Hemoglobin, PCV – Packed Cell Volume, RBC – Red Blood Cell, WBC – White Blood Cell, N- Neutrophils, L – Lymphocytes, M – Monocytes, B –Basophils, E – Eosinophils.

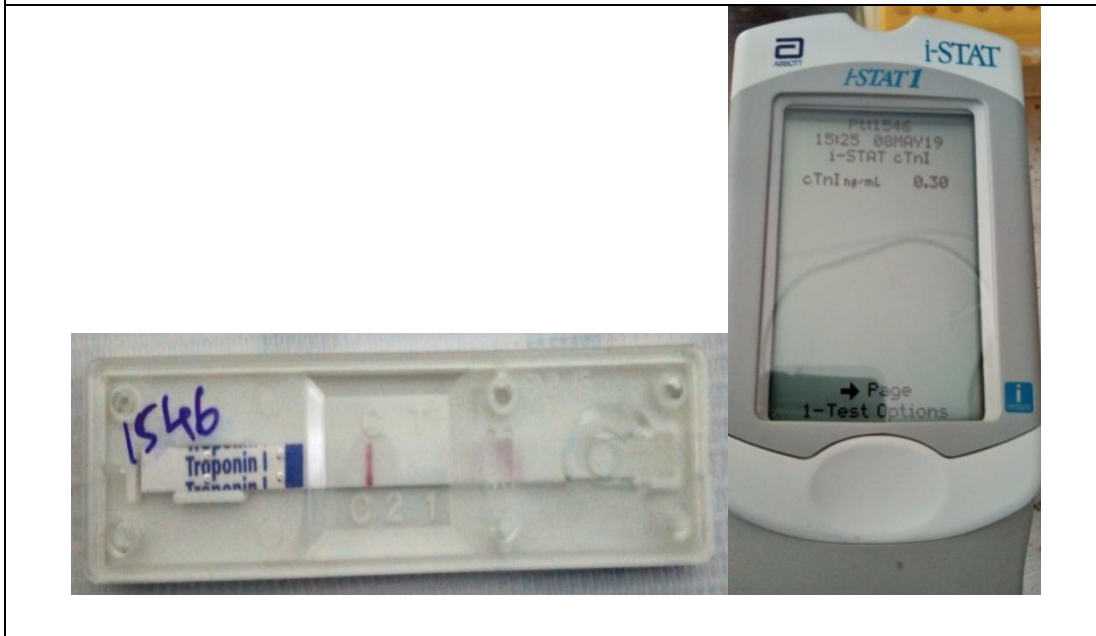\* Significant at p < 0.05. \*\* Significant at p < 0.01.

**Table.2** Serum biochemical parameters and Cardiac Troponin (cTnI) of healthy and TRP affected cows


Parameters	Healthy cows (N=10)	TRP affected cows (N=19)
<b>BUN (mg/dL)</b>	22.80 ± 1.590	39.26 ± 4.68*
<b>Creatinine (mg /dL)</b>	0.72 ± 0.075	1.21 ± 0.15**
<b>Glucose (mg /dL)</b>	52.60 ± 3.27	52.47 ± 6.24
<b>Total Protein (g /dL)</b>	8.8 ± 0.35	6.5 ± 0.41**
<b>Albumin (g /dL)</b>	4.4 ± 0.11	2.83 ± 0.19**
<b>ALT (U/L)</b>	21.70 ± 1.61	42.63 ± 5.31**
<b>AST (U/L)</b>	101.30 ± 7.59	174.26 ± 15.64**
<b>CK-MB (U/L)</b>	76.45 ± 28.24	221.22 ± 31.16**
<b>LDH (U /dL)</b>	2052.10 ± 76.39	2138 ± 363.42*
<b>Ca (mg/dL)</b>	8.9 ± 0.75	9.6 ± 1.09*
<b>P (mg/dL)</b>	5.60 ± 0.40	6.06 ± 0.26*
<b>cTnI (ng /ml)</b>	0.0204 ± 0.011	0.10 ± 0.034*

The values are presented Mean ± Standard Error. BUN – Blood Urea Nitrogen, ; CK-MB - CK-Myocardial band; ALT – Alkaline Phosphatase, AST - Aspartate aminotransferase; LDH - Lactate dehydrogenase, Ca – Calcium, P – Phosphorus. CTnI – Cardiac troponin I. \* Significant at p < 0.05. \*\* Significant at p < 0.01.

**Fig.1** The negative result in reading window of cTn-I immunochromatographic test kit and positive result in iSTAT immune assay kit of same cow that affected with TRP



**Fig.2** Point-of-Care immunoassay i-STAT equipment for assessing cTnI in TRP cow



Measurement of cTnI is a very sensitive way of demonstrating myocardial cell damage in animals with clinically suspected myocarditis (Tunca *et al.*, 2008). During myocardial cell damage increased in cTn proteins have a high sensitivity and absolute specificity; they are released even in micro injuries into the blood stream (Oyama and Sisson, 2004). These proteins are usually present in blood either at very low concentrations or below the limit of detection for most of the assays (Gunes *et al.*, 2008). Traumatic reticulo pericarditis affected dairy cows had elevated cTnI levels than the healthy ones. Serum cTnI concentrations were significantly different in cattle with traumatic pericarditis compared with that of healthy cattle (Table 2, (P<0.05)). The findings of the present study agreed with the previous study which observed that, cattle with pericarditis, endocarditis, congenital cardiac disease, and chronic suppurative pneumonia had significantly increased serum cTnI concentrations (Mellanby *et al.*, 2009). Bovine Foot and Mouth Disease (FMD) associated

cardiac damages may be assessed with both quantitative cTn-I analyses and qualitative cTn-I methods (Akin *et al.*, 2015).

A few human study reported that myocardial necrosis is not a requisite for the release of cTn; instead the cell death in any shape or form can result in its release (e.g. autophagy, apoptosis, necroptosis) (Jaffe and Wu., 2012; Wu *et al.*, 2007). In animals affected with traumatic pericarditis, effusion in pericardium occurs as sequelae of piercing up of foreign body which on forceful cardiac pumping may pierce the heart and end up in myocardial damage and release the cardiac markers (CTn).

Point-of-care immunoassay i-STAT evaluation of cTnI is an easy and early diagnostic measure and helped to assess the nature of myocardial involvement and cell damage in Traumatic reticulo pericarditis affected cows.

## **Acknowledgment**

Authors sincerely acknowledge the Dean, Veterinary College and Research Institute, Orathanadu, TANUVAS, Tamil Nadu, India for providing necessary facilities to carry out research.

## **References**

- Akin, H., V. Günes, and Bekdik., L.K. 2015. Practice cardiac troponin I kit expressions and concentrations of cardiac troponin I in Beef cattle with oot and Mouth Disease. *Journal of Faculty of Veterinary Medicine, Erciyes University.* 12(3): 163-170.
- Attia, N.E., 2016. Cardiac biomarkers and ultrasonography as tools in prediction and diagnosis of traumatic pericarditis in Egyptian buffaloes, *Veterinary World.* 9(9): 976-982.
- Braun, U., S.Warislohner, P.Torgerson, K.Nuss and Gerspach, C. 2018. Clinical and Laboratory findings in 503 cattle with traumatic reticuloperitonitis. *BMC Veterinary Research,* 14:66.
- Braun, U., 2009. Traumatic pericarditis in cattle: clinical, radiographic and Ultrasonographic findings. *Vet.J.* 182 (2): 176-186.
- Gunes, V., G.Atalán, M.Citil and Erdogan, H.M. 2008. Use of cardiac troponin kits for the qualitative determination of myocardial cell damage due to traumatic reticuloperitonitis in cattle. *Vet. Rec.* 162: 514-517.
- Jaffe, A.S. and Wu, A.H. 2012. Troponin release – reversible or irreversible injury? Should we care?. *Clin. Chem.* 58:148-150.
- Kaneko, J.J., J.W. Harver and Bruss, M.L. 2008. *Clinical biochemistry of domestic animals.* 6<sup>th</sup> ed. California, USA, Academic Press.
- Mellanby, R.J., J.P. Henry, R. Cash, S.W, Ricketts, R. Bexiga, I.Truiyers, and Mellor, D.J. 2009. Serum Cardiac Troponin I concentrations in Cattle with cardiac and Noncardiac disorders. *J. Vet. Intern. Med.* 23 (4): 926-30.
- Oyama, M.A. and Sisson, D.D. 2004. Cardiac troponin-I concentration in dogs with cardiac disease. *J. Vet. Intern. Med.* 18(6): 831-9.
- Reef, V.B. and McGuirk, S.M. 2002. Diseases of the cardiovascular system. In: Smith, B.P., editor. *Large Animal Internal Medicine.* 3rd ed. Mosby, St. Louis, MO, USA. p957, 463-6.
- Tunca, R., M. Sozmen, H.Erdogan, M.Citil, E.Uzlu, H. Ozen, and Goke, E. 2008. Determination of cardiac troponin I in the blood and heart of calves with Foot – and - Mouth. *J.Vet. Diagn. Invest.* 20: 598-605.
- Venkatesan, M., P.Selvaraj, M.Saravanan, M. Veeraselvam, S.Yogeshpriya, and Jayalakshmi, K. 2019. Palliative Management with Ultrasound Guided percutaneous pericardial lavage for cow with pericarditis – A case report. *Indian J.Vet Sci, Biotech.* 14 (3): 73-74.
- Wu, A.H.B., A.S. Jaffe, F.S.Apple, R.L. Jesse, G.L.Francis, D.A. Morrow, L.K. Newby, J. Ravkilde, W.H.W.Tang, R.H.Christenson, C.P. Cannon, and Storrow, A.B. 2007. National academy of clinical biochemistry laboratory medicine practice guidelines: Use of cardiac troponin and B-type natriuretic peptide or N-terminal proB-type natriuretic peptide for etiologies other than acute coronary syndromes and heart failure. *Clin. Chem.* 53: 2086-2096.

**How to cite this article:**

Venkatesan, M., P. Selvaraj, M. Saravanan, S. Yogeshpriya, K. Jayalakshmi, M. Veeraselvam and Premalatha, N. 2020. Evaluation of Cardiac Troponin - cTnI in Cows with Traumatic Reticulo– Pericarditis. *Int.J.Curr.Microbiol.App.Sci.* 9(01): 308-314.  
doi: <https://doi.org/10.20546/ijcmas.2020.901.035>