

Case Study

<https://doi.org/10.20546/ijcmas.2019.807.001>

## Successful Surgical Retrieval of an Insulated Electrical Wire by Cystotomy in a Mudhol Hound Dog - A Case Report

H.K. Santosh\*, G. Kamalakar, K.M. Srinivasa Murthy and B.N. Nagaraja

Department of Veterinary Surgery and Radiology, Veterinary College, Hebbal, Bengaluru - 560024, Karnataka, India

\*Corresponding author

### ABSTRACT

#### Keywords

Mudhol Hound, Stranguria, Cystotomy, Insulated Electrical wire

#### Article Info

Accepted:  
04 June 2019  
Available Online:  
10 July 2019

An adult dog was presented to the clinics with the history of difficulty in passing the urine since 10 days. Physical examination revealed the signs of urinary tract obstruction. Catheterization of the bladder revealed obstruction at the level of os penis groove. The survey radiograph revealed presence of calculi in the os penis and curled radio-opaque material in the urinary bladder. The retrohydropulsion of urethra was successful in propelling the urethroliths into the bladder. The cystotomy was performed through caudal midline ventral abdominal approach and an insulated electrical wire and cystoliths were removed. The patient was recovered uneventfully.

### Introduction

Reports of incidence of foreign bodies in urinary system in animals were meager, though few were reported in humans since the earliest days of the medical literature (Eckford *et al.*, 1992). The types of foreign bodies have been classified as inserted, like intra uterine devices (Nabi and Hemal, 2001), migratory, like surgical instruments (Tornero *et al.*, 2000) and iatrogenic, like placement of artificial material within the urinary system (Hiller *et al.*, 1999). The precipitation-crystallization theory of stone formation likely plays a role in struvite urolithiasis (Dibartola and Chew,

1981). In this theory, super saturation of urine with ions results in precipitation and formation of particles. Particles grow into small crystals and aggregate into larger crystals. Ultimately, calculi form if the microenvironment favours this process.

### Case History and Clinical Observations

A 9 year old male intact Mudhol hound dog was presented to the Dept. of Veterinary Surgery and Radiology, Veterinary College, Hebbal, Bengaluru with the signs of stranguria, dysuria, haematuria, dehydration and inanition since 10 days. Clinically, the

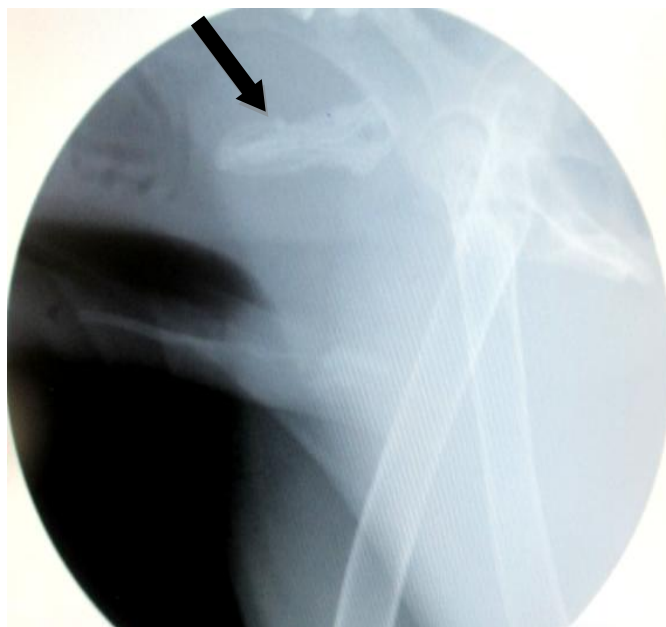dog was dull, depressed, dehydrated and struggling to void urine. Haematological parameters were almost normal except a high PCV (42%) and all physiological parameters were within the normal range. Urethral catheterization revealed obstruction proximal to os penis. A survey radiograph revealed presence of numerous small calculi in the os penis and a recoiled radio opaque material in urinary bladder suspected of cystic calculi (Fig. 1). Retrohydropulsion of urethra using KY jelly mixed with normal saline could successfully propel the urethroliths into the bladder and could retrieve little quantity of urine. Hence, an emergency cystotomy was planned and executed.

### **Treatment and Discussion**

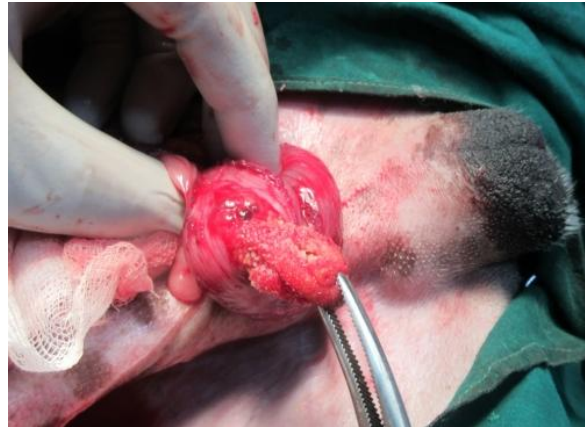The dog was rehydrated using DNS 300 ml I/V and premedicated with inj. atropine sulphate @ 0.04 mg/kg BW, S/C; inj. xylazine hydrochloride @ 1 mg/kg BW, I/M. The caudal mid ventral abdomen was prepared for aseptic surgery. General anaesthesia was induced by inj. thiopentone sodium @ 12.5

mg/kg BW, I/V and maintained by using Isoflurane. The animal was placed in dorsal recumbency and the skin incision was given left paramedian to the penis and abdomen opened over linea alba. Semi distended urinary bladder was exteriorized and given a stab incision over its dorsal border to remove red coloured urine. The foreign body (Fig. 2) was retrieved out with the help of Allis tissue forceps. Few small calculi were also removed. Once again the calculi in urethra were flushed with normal saline into bladder and removed. Cystorrhaphy was done in double inversion manner using polyglactin 910 no. 3/0, linea alba using polyglactin 910 no. 1 in simple interrupted manner and skin in horizontal mattress pattern using polyamide black no. 1. Post-operatively it was administered with 300 ml RL, inj. Ceftriaxone @ 20 mg/kg BW and meloxicam @ 0.2 mg/kg BW I/V for next 5 days along with alternative days dressing. The foreign body retrieved was found to be a recoiled electrical insulated wire covered with multiple sharp irregular small calculi (Fig. 3a) and it was measured > 30 cm in length in its fully extended state (Fig. 3b).

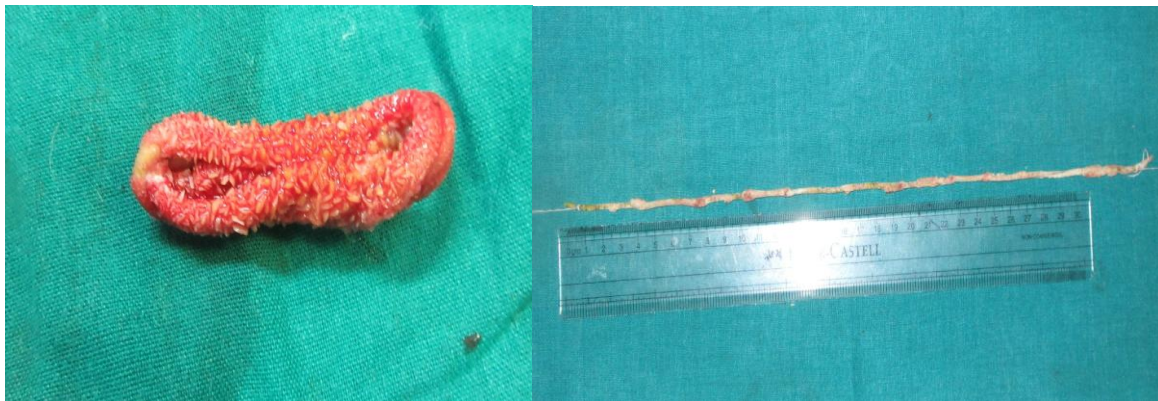
**Fig.1** Survey radiograph of radio-opaque curled foreign body (black arrow) in the bladder



**Fig.2** Insulated electrical wire foreign body in the urinary bladder



**Fig.3** Retrieved foreign body, an insulated electric wire covered with rough edged calculi (3a) and extended electric wire measured about > 30 cm in length (3b)



3a

3b

In dogs, incidence of cystoliths is not uncommon but it is very rare to find a foreign body in urinary bladder. Cherbinsky *et al.*, (2010) did exploratory cystotomy and removed grass awns in three male Yorkshire Terriers and one female domestic short-haired cat. In all patients, the route of entry of the grass awn was thought to have been retrograde migration from the urethral opening. In human patients, various foreign bodies like surgical forceps (Williams, 1986), cloth material (Poultion and Wessells, 2003), needle (Satija *et al.*, 2000), intra uterine devices (Atakan and Kaplan, 2002) and calcium encrusted foreign bodies including pencils, ballpoint pens and its refills, paper

clips and hair pins (Abdelsayed *et al.*, 1978) in urinary bladder or urethra were reported and those patients had previous history of surgery or urethral catheterization. The foreign bodies found in urethra or bladder in humans were also might be attributed to eroticism, inquisitiveness or psychotic illness (Rosenthal *et al.*, 2003) or iatrogenically due to faulty surgeries (Tornero *et al.*, 2000). The foreign body inside the bladder was found to be a recoiled insulated electric wire which might have used earlier for catheterizing urethra that unknowingly pushed by the next person in an attempt to make the urethra patent. This made the wire to enter the bladder and later formed a nidus for calculi

formation. Many treatment choices have been explained in case of humans, the endoscopic removal of foreign body from the bladder is considered as the treatment of choice (Georgius, 2000) but sometimes cystotomy and laparoscopic procedure or multidisciplinary approach is required for large objects (Tan *et al.*, 1993). But, in the present case the foreign body was retrieved by cystotomy.

## References

- Abdelsayed, M.A., Bissada, N.K, Finkbeiner, A.E and Redman, J.F. 1978. Spontaneous passage of bullet during voiding. *South. Med. J*, 71: 83-84.
- Atakan, R.H., and Kaplan, M. 2002. Intravesical migration of intrauterine device resulting in stone formation. *Urology*. 60: 911.
- Cherbinsky, O., Westropp, J, Tinga, S, Jones, B and Pollard, R. 2010: Ultrasonographic features of grass awns in the urinary bladder. *Vet. Radiol. Ultrasound*, 51: 462 – 465.
- Dibartola, S.P., and Chew, D.J. 1981. Canine urolithiasis. *Compendium on Continuing Education for the Practising Veterinarian*. 3(3): 226-234.
- Eckford, S.D., Persad, R.A, Brewster, S.F and Cingell, J.C. 1992. Intravesical foreign bodies: five-year review. *Br. J. Urol*, 69: 41-45.
- Georgius, P., 2000. A novel method to remove an unusual intravesical foreign body. *BJU International*. 86: 749-750.
- Hiller, N., Zagal, I and Solomom, I. 1999. Intravesical foreign bodies. The danger of eroticism. *Urologia*, 66: 2.
- Nabi, G., and Hemal, A.K. 2001. Endoscopic management of an unusual foreign body in the urinary bladder leading to intractable symptoms. *Int. Uro. Neph*, 33: 351-52.
- Poultion, T.L., and Wessells, H. 2003. Delayed presentation of an intravesical foreign body 6 years after impalement injury. *J. Urol*, 169: 1792.
- Rosenthal, M., Berkman, P, Shapira, A, Gil, I and Abramovic, J. 2003. Urethral masturbation and sexual disinhibition in dementia: A case report. *Isr. J. Psychiatry. Relat. Sci*, 40: 67 – 70.
- Satija, L., Dhagat, P, Sharma, A and Satija, N. 2000. Vesical calculus formation on a Perforating vaginal foreign body. *Ind. J. Radio. Image*, 10: 1-2.
- Tan, L.B., Chiang, C.P, Huang, C.H, Chou, Y.H and Wang, C.J. 1993. Foreign body in urinary bladder. *Kao. Gaoxiang. Yi. Xue. Ke. Xue. Za. Zhi*, 9: 604-609.
- Tornero, J., Palou, J, Prados, M, Salvador, J and Vicenti, J. 2000. Bladder perforation caused by foreign body migration. *Int. Urol. Nephrol*, 32: 241-243.
- Williams, D. J., 1986. Uric acid bladder stone associated with a foreign body. *Postgrad. Med. J*, 62: 495.

### How to cite this article:

Santosh, H.K., G. Kamalakar, K.M. Srinivasa Murthy and Nagaraja, B.N. 2019. Successful Surgical Retrieval of an Insulated Electrical Wire by Cystotomy in a Mudhol Hound Dog - A Case Report. *Int.J.Curr.Microbiol.App.Sci*. 8(07): 1-4.  
doi: <https://doi.org/10.20546/ijcmas.2019.807.001>