

Original Research Article

<https://doi.org/10.20546/ijcmas.2018.706.162>

Histopathological and Immunohistochemical Diagnosis of Canine Fibrosarcoma

S. Subapriya*, S. Vairamuthu, N. Pazhanivel, Ravi Sundar George,
K. Vijayarani and M. Gokulakrishnan

Madras Veterinary College, Chennai, TANUVAS, India

*Corresponding author

ABSTRACT

Keywords

Dog, cytology,
fibrosarcoma,
histopathology,
immunohistochemistry

Article Info

Accepted:
15 May 2018
Available Online:
10 June 2018

An one year old, female, Labrador dog was presented with a history of a big mass in right hindlimb. The mass was hard on clinical examination. Fine needle aspiration cytology (FNAC) revealed pleomorphic fibrocytes with prominent nucleoli. The mass was then surgically excised. Histopathology section showed fibrocytes arranged in varying patterns with numerous mitotic figures. Immunohistochemical study showed positive expression for vimentin and no expression for cytokeratin. Based on above findings the mass was confirmed as fibrosarcoma.

Introduction

Fibrosarcoma is a malignant tumour of the fibroblasts and it is of mesenchymal origin.

Although fibrosarcomas occur in all domestic species, they are most commonly seen in adult and aged cats and dogs with mean age of 9 years (Goldschmidt and Hendrick, 2002).

This case was impressive by the external appearance of huge size of the mass.

Hence the present study was undertaken to understand the pathology of fibrosarcoma in a Labrador dog.

Fibrosarcoma is a common neoplasm that occurs in dogs, cats and other domestic animals (Kass *et al.*, 1993; Goldschmidt and Hendrick 2002).

Sargan *et al.*, (2005) stated that these tumours are associated with defects or rearrangements in chromosomes 11 and 30.

Genetic susceptibility (Cullen *et al.*, 2002), various chemical substances (Smyth *et al.*, 2001; Cullen *et al.*, 2002), subcutaneous vaccine injections (Kass *et al.*, 1993), chronic inflammations (Doddy *et al.*, 1996) and traumas (Schumacher *et al.*, 1983) have been reported as causes of fibrosarcomas in dogs

and other animal species.

Materials and Methods

An one year old, female, Labrador dog was brought to Small Animal Clinic – Out Patient-Surgery unit of Madras Veterinary College Teaching Hospital with a history of progressively increasing mass in the right hindlimb. The mass was conspicuously big, to be witnessed even at distance as a huge spherical mass. Fine needle aspiration cytology (FNAC) was performed. Radiographic investigation revealed no metastatic foci. Following this, surgery was done to excise the mass. Excised mass was collected in 10 per cent neutral buffered formalin for histopathological examination.

Cytology smear was air dried and stained with Leishman and Giemsa cocktail stain as described by Garbyal *et al.*, (2006). In histopathological processing, paraffin embedded tissue sections were cut to 4-6 microns thickness and stained with Hematoxylin and Eosin (H&E). For immunohistochemistry, sections were stained for Cytokeratin and Vimentin as per the procedures given by the immunohistochemistry kit manual.

Results and Discussion

Grossly, the mass was a huge, ball like, diffuse swelling in the right hind limb, hip region, measuring about more than 15 cm in diameter (Fig-1). It was found extending upto the tail laterally and even seen raised dorsally above the sacrococcygeal vertebral column. It was hard, non-ulcerated with neat margins. The excised mass weighed around 3 kgs. Cytological examination revealed many pleomorphic, spindle shaped to plumpy fibrocytes (Fig-2) with multiple nucleoli. Higher magnification revealed binucleated

cells, plumpy prominent nuclei with eosinophilic cytoplasm, multiple nucleoli (Fig-3) and coarse chromatin. Mitotic figures were also seen.

Histopathological examination revealed interlacing bundles of neoplastic fibrocytes arranged in sheets, herring bone (Fig-4) and in haphazard pattern. The neoplastic cells were fusiform shaped, with elongated, round to oval nuclei and indistinct eosinophilic cytoplasm. Numerous mitotic figures were seen.

Based on the cytological and histopathologic examination, the huge mass was diagnosed as fibrosarcoma. Immunohistochemical study was carried out to identify the mesenchymal origin of tumour cells as fibrosarcoma is a kind of mesenchymal tumour. In this direction, paraffin embedded tissue sections were stained with markers like Cytokeratin and Vimentin. In our findings, the sections showed no positivity for Cytokeratin (Fig-5), which ruled out epithelial tumours. However, diffuse and very strong expression of Vimentin (Fig-6) was observed which confirmed the mesenchymal origin of the tumour.

Thus pooling all the findings, cytological, histopathological and immunohistochemical, the giant mass was confirmed as fibrosarcoma. In our study, the tumour was identified in a relatively young dog of just one year old. However earlier reports have reported the occurrence of this tumour in adult dogs with a mean age of 9 years (Goldschmidt and Hendrick 2002). As in our case, skin and subcutis have been reported as the primary sites of occurrence of fibrosarcomas in dogs and other domestic animals by Goldschmidt and Hendrick (2002). However Avci *et al.*, (2012) has reported a rare case of intestinal fibrosarcoma in a 11 year old Cocker Spaniel dog.

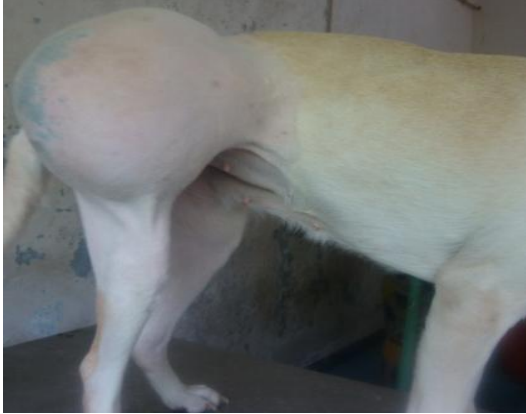

Fig-1 Dog-Fibrosarcoma - Right thigh-
Huge, spherical mass

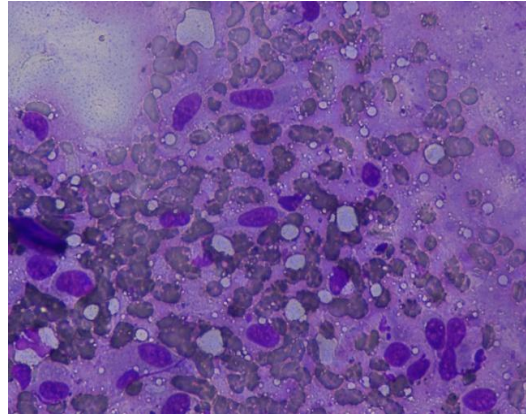


Fig-2 Dog - Fibrosarcoma- FNAC
Spindle to plump cells- LG - 40x

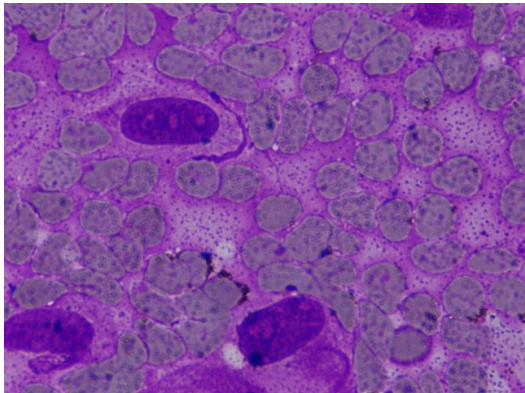


Fig-3 Dog - Fibrosarcoma- FNAC
Prominent,multiple nucleoli-LG-100x

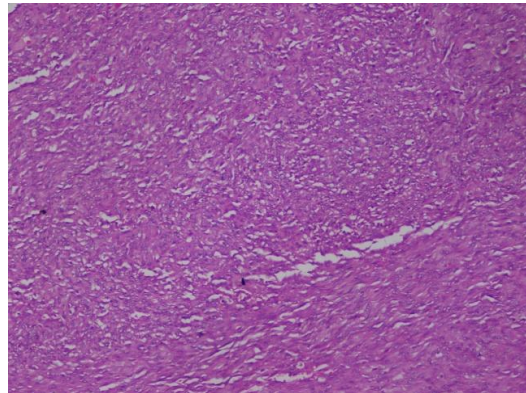


Fig-4 Dog -Fibrosarcoma-Neoplastic cells
arranged in herring bone pattern- H&E- 10x

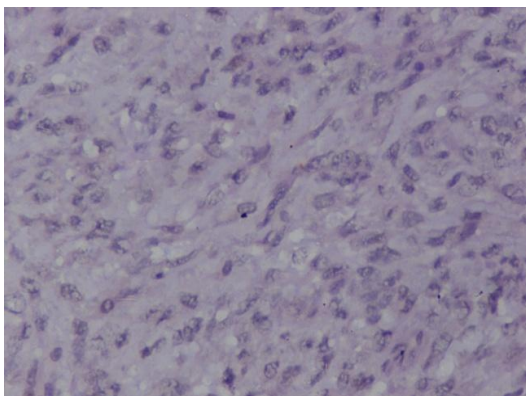


Fig-5 Dog – Fibrosarcoma – Immunohisto
Chemistry -Cytokeratin – Negative expression
40x

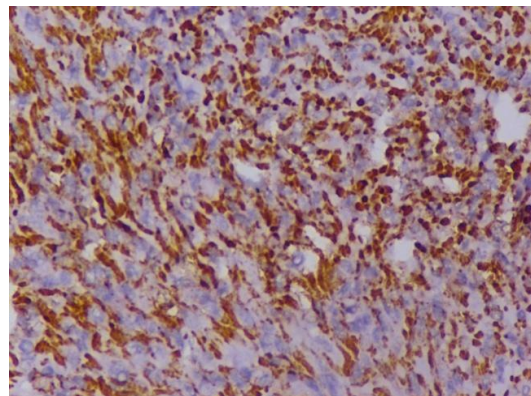


Fig-6 Dog – Fibrosarcoma – Immunohisto
Chemistry-Vimentin-Diffuse and strong
positive expression-40x

The numerous mitotic figures seen in microscopic examination were highly suggestive of the malignant nature of the tumour. In concordance with this, the animal had a fatal end during the follow up for tumour free survival time.

Acknowledgement

The authors are thankful to the Dean, Madras Veterinary College, TANUVAS, for providing the necessary facilities to carry out the work.

References

- Avci, H., R. Yaygingul, M. Gultekin, E.T. Epikmen, K. Ural, A. Belge and Birincioglu. S.S. 2012. Primary intestinal fibrosarcoma caused by intestinal perforation in a dog: a case report. *Veterinari Medicina*, 57 (6): 314–319
- Cullen, J.M., R. Page and Misdorp, W. 2002. An overview of cancer pathogenesis, diagnosis, and management. In: Meuten DJ (ed.): *Tumors in Domestic Animals*. 4th ed. Iowa State Press, Iowa. 3–44.
- Doddy, F.D., L.T. Glickman, N.W. Glickman and Janovitz, E.B. 1996: Feline fibrosarcomas at vaccination sites and non-vaccination sites. *Journal of Comparative Pathology*. 114: 165–174.
- Gallati, W.W., 1956. Fibrosarcoma associated with the cysticercus of *Taenia taeniaeformis* in the liver of a muskrat. *Ohio Journal of Science* 56: 71–75.
- Garbyal, R.S., N.Agarwal and Kumar, P. 2006. Leishman-Giemsa Cocktail, An Effective Romanowsky stain for air dried cytologic smears. *Acta Cytol*, 50: 403-406.
- Goldschmidt, M.H., and Hendrick M.J. 2002. Tumors of the skin and soft tissues. In: Meuten DJ (ed.): *Tumors in Domestic Animals*. 4th ed. Iowa State University Press, Iowa. 45–117.
- Kass, P.H., W.G. Barnes, W.L. Splanger, B.B. Chomel and Culbertson, M.R. 1993): Epidemiological evidence for a Veterinari Medicina, 57, 2012 6: 314–319 Case Report 319 casual relation between vaccination and fibrosarcoma tumorigenesis in cats. *Journal of the American Animal Hospital Association* 203, 396–405.
- Sargan, D.R., B.S. Milne, J.A. Hernandez, P.C. O'Brien, M.A. Ferguson-Smith, T. Hoather and Dobson, J.M. 2005. Chromosome rearrangements in canine fibrosarcomas. *J Hered* 96(7): 766-773
- Schumacher, J., J.P. Watkins, S.R. Wilson and Foreman, M.E. 1983: Burn-induced neoplasia in two horses. *Equine Veterinary Journal*. 18: 410–412.
- Smyth, M.J., N.Y. Crowe and Godfrey, D.I. 2001. NK cells and NKT cells collaborate in host protection from methylcholanthrene-induced fibrosarcoma. *International Immunology* 13:459–463.

How to cite this article:

Subapriya S., S. Vairamuthu, N. Pazhanivel, Ravi Sundar George, K. Vijayarani and Gokulakrishnan M. 2018. Histopathological and Immunohistochemical Diagnosis of Canine Fibrosarcoma. *Int.J.Curr.Microbiol.App.Sci*. 7(06): 1376-1379.
doi: <https://doi.org/10.20546/ijcmas.2018.706.162>