

Original Research Article

<https://doi.org/10.20546/ijcmas.2018.706.158>

## Histopathological and Immunohistochemical Diagnosis of Canine Haemangiopericytoma

S. Subapriya\*, S. Vairamuthu, N. Pazhanivel, Ravi Sundar George,  
K. Vijayarani and M. G. Mohamed Ali

Madras Veterinary College, Chennai-7 TANUVAS, India

\*Corresponding author

### ABSTRACT

#### Keywords

Dog, Haemangiopericytoma, fingerprint, histopathology, immuno histochemistry, vascular tumours

#### Article Info

##### Accepted:

15 May 2018

##### Available Online:

10 June 2018

A five years old female Labrador dog was presented with a history of swelling in the umbilical region. The mass was firm on clinical examination. Fine needle aspiration cytology (FNAC) revealed spindle shaped cells with round nuclei. The mass was then surgically excised. Histopathology section revealed perivascular whorls of fusiform cells in fingerprint pattern. Immunohistochemical study showed positive expression for PCNA, vimentin and p53 while cytokeratin, EMA, Bcl2 and S100 and dsemin showed no expression. Based on the above findings the mass was confirmed as hemangiopericytoma.

### Introduction

Haemangiopericytoma is a mesenchymal tumour which derives from pericytes that are capillary sub-endothelial lining cells that are particularly concentrated in areas of increased blood pressure such as distal extremities (Sims, 2000). Critical analysis of the histopathological details for the subtypes, mitosis, necrosis, and quantification of cell proliferation and apoptosis will help to assess the aggressive nature of the tumour.

Based on the paucity of literature on the occurrence of cutaneous hemangiopericytoma in dogs, the present paper reports a case of cutaneous haemangiopericytoma in a five year

old Non-Descript female dog. In addition to routine clinical, cytological and histopathological studies, immunohistochemical study was also done for confirming the diagnosis of haemangiopericytoma.

Haemangiopericytoma is an uncommon tumour in animals (Goldschmidt and Hendrick, 2002). Epithelioid, storiform and perivascular forms have been described as morphological subtypes of haemangiopericytoma with epithelioid form being the most common and aggressive subtype (Goldsmith *et al.*, 2002 and Santos *et al.*, 2009). Unlike in humans where haemangiopericytoma can be detected in non-

cutaneous locations, canine haemangiopericytoma is exclusively considered a tumour of skin and subcutaneous tissue (Pulley *et al.*, 1990). It has been stated that metastasis of haemangiopericytoma is very rare and 70 per cent of these neoplasms can be controlled by surgical excision (Mazzei *et al.*, 2002).

## Materials and Methods

A five years old Non-Descript female dog was brought to Small Animal Clinic –Out Patient - Surgery unit of Madras Veterinary College Teaching Hospital with a mass in the umbilical region. Radiographic examination revealed no metastatic foci in the dog.

Fine needle aspiration cytology (FNAC) was performed and excised mass was collected in 10 per cent neutral buffered formalin for histopathological examination. Cytological smear was air dried and stained with Leishman and Giemsa cocktail stain as described by Garbyal *et al.*, (2006).

Paraffin embedded tissue sections were cut into 4-6 microns thickness and stained with Haematoxylin and Eosin (H&E). For immunohistochemistry, sections were stained for Cytokeratin, Vimentin, Desmin, Epithelial membrane Antigen (EMA), PCNA and p53 as per the procedures given by the immunohistochemistry kit manual.

## Results and Discussion

Gross clinical examination of the mass didn't reveal any unique feature suggestive of haemangiopericytoma. It was a uniformly circumscribed, red coloured firm nodule measuring about 4 cm in diameter (Fig-1) and didn't evince any pain on palpation.

Cytological examination revealed spindle shaped cells with round nuclei and indistinct

cytoplasmic borders. Erythrocytes were also seen.

Histopathological examination revealed the perivascular whorls of fusiform cells like a fingerprint pattern (Fig-2) with blood vessels at the centre of the whorl. Neoplastic cells were spindle to pyriform shaped and separated by collagenous stroma.

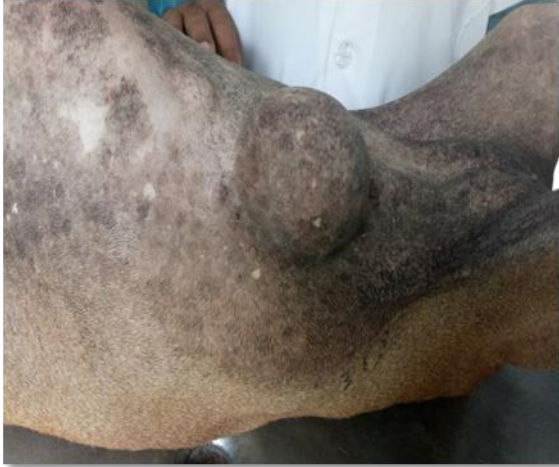The cells had oval to vesicular nuclei, anisokaryosis, one to two nucleoli per cell and basophilic cytoplasm. Whorls can also be appreciated in peripheral nerve sheath tumours but they are less prominent and most of whorls shall encircle collagen instead of capillaries.

In addition, the spindle cells are more delicate and often have more intercellular fibrillar or mucinous matrix than in haemangiopericytoma (Goldschmidt and Hendrick, 2002). Based on histopathological examination, the mass was diagnosed as haemangiopericytoma.

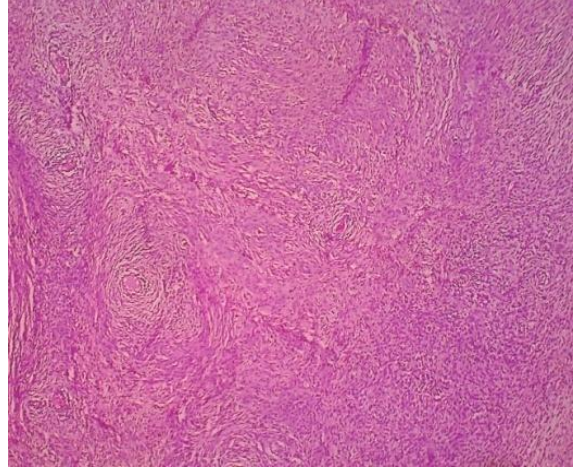
## Immunohistochemical investigation

A specific and conclusive immunohistochemistry panel for haemangiopericytoma is not available as no marker is fail-safe specific and sensitive to detect pericytes exclusively. However immunohistochemical studies of hemangiopericytoma have been reported by few authors with varied results (Espat *et al.*, 2002).

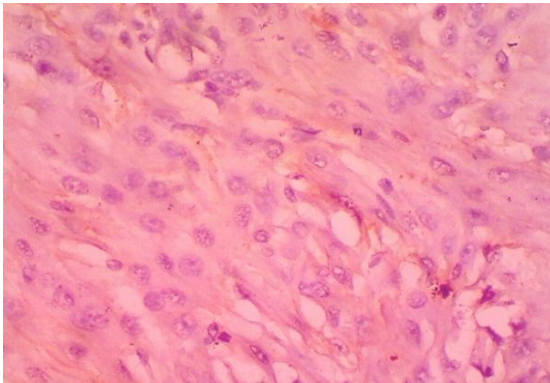
In our immunohistochemical study, we employed a panel of markers viz., Cytokeratin, Vimentin, Desmin, EMA, S100 and p53 and PCNA. Cytokeratin was not expressed and Vimentin was expressed immunohistochemically (Fig-3) which confirmed the mesenchymal origin of haemangiopericytoma is in agreement with the earlier reports (Nehls, and Dreckhahn 1991).



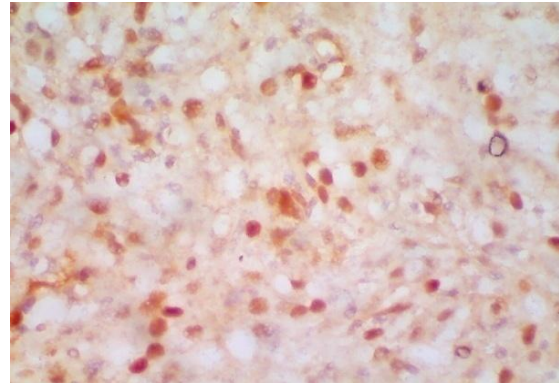
**Fig.1** Dog - Haemangiopericytoma – Umbilical region- Circumscribed, firm, non-ulcerated mass



**Fig.2** Dog – Haemangiopericytoma – Multiple whorls and fingerprint pattern – H&E 4x



**Fig-3** Dog – Haemangiopericytoma  
Immunohistochemistry – Vimentin  
Positive expression – 40x



**Fig-4** Dog – Haemangiopericytoma  
Immunohistochemistry – PCNA  
Positive expression – 40x

Desmin was not expressed in immunohistochemistry of paraffin embedded tissue sections is in agreement with the findings of Espat *et al.*, (2002). EMA was not expressed in immunohistochemistry of paraffin embedded tissue sections is also in accordance with the findings of Espat *et al.*, (2002). S100 was not expressed in immunohistochemical study which helped to rule out peripheral nerve sheath tumours (Chijiwa *et al.*, 2004). Enzinger *et al.*, (1995) stated that pericytes can be differentiated

from perineural fibroblasts immunohistochemically, as pericytes are positive to vimentin but negative to EMA marker in contrast to perineural fibroblasts which show expression of both vimentin and EMA markers.

In our study, immunostaining revealed expression of Proliferating Cell Nuclear Antigen PCNA (Fig-4). Santos *et al.*, (2009) stated that aggressiveness of haemangiopericytoma can be determined by

the quantification of cell proliferation. Accordingly the expression of PCNA in the present case indicated that the tumour is in aggressive pattern. In addition to these, few to stray population of cells showed expression of p53 gene. Thus in the present study, markers like PCNA, Vimentin and p53 were expressed in haemangiopericytoma and no expression was found for markers like EMA, Bcl2, S100 and Desmin.

Based on the above findings the mass was confirmed as Haemangiopericytoma. The present case was diagnosed in a five years old female Non-Descript dog which is in concordance with literature where hemangiopericytoma is reported principally a tumor of adult patients, typically diagnosed on middle-aged or older dogs with no predilection factor of sex of the animal (Goldschmidt & Hendrick, 2002 and GROSS *et al.*, 2005). However, Namazi *et al.*, 2014 has reported a case of haemangiopericytoma in a two year old male Great Dane dog in flank region.

Thus the confirmative diagnosis of canine hemangiopericytoma in the present case was based on the finding of gross appearance of a mass in the umbilical region, followed by cytological appearance, perivascular whorling and characteristic fingerprint pattern in histopathology and a panel of immunohistochemical markers.

Although histopathology is considered the gold standard for diagnosis of haemangiopericytoma, as even seen in our case, further immunohistochemical investigation was done for confirming hemangiopericytoma against tumours with similar histological features of haemangiopericytoma like the peripheral nerve sheath tumours.

## References

- Chijiwa, K., K. Uchida and Tateyama, S. 2004. Immunohisto-chemical evaluation of canine peripheral nerve sheath tumors and other soft tissue sarcomas. *Vet Pathol.*, 41(4): 307-318
- Enzinger, F.M., and Weiss, S.W.1995. *Soft tissue tumors*, 3rd ed. New York: Mosby; 713-733
- Espat, N.J., J.J. Lewis, D. Leung, J.M. Woodruff, C.R. Antonescu, J. Shia, and Brennan, M.F. 2002. Conventional hemangiopericytoma: modern analysis of outcome. *Cancer*. Oct 15; 95(8):1746-51
- Garbyal, R.S., N. Agarwal and Kumar, P. 2006. Leishman-Giemsa Cocktail, An Effective Romanowsky stain for air dried cytologic smears. *Acta Cytol.*, 50: 403-406.
- Goldschmidt, M.H., and Hendrick, M.J. 2002. Tumors of the skin and soft tissue. In: Meuten, D.J. (Ed.). *Tumors in domestic animals*. 4<sup>th</sup> edn.
- Mazzei, M., F.Milanta, S. Citi, D. Lorenzi and Poli, A. 2002. Hemangiopericytoma: Histological spectrum, immunohistochemical characterization and prognosis. *Vet Dermatol*, 13(1): 15-21
- Namazi, F., M.A. Hasiri, A. Oryan and Moshiri, A. 2014. Hemangiopericytoma in a young dog: Evaluation of histopathological and immunohistochemical features *Vet Res Forum*. Spring; 5(2): 157–160
- Nehls, V., and Dreckhahn, D. 1991. Heterogeneity of microvascular pericytes for smooth muscle type alpha-actin. *J Cell Biol.*, 113: 147–154
- Pulley, L. T., and Stannard, A. A. 1990. Tumors of the skin and soft tissue. In: Moulton, J. E., ed. *Tumors in Domestic Animals*, 3rd edn. Berkeley: University of California Press.

Santos, S.V., L.N. Torres, T.C. da Silva, L.R.M. de Sa., J.M. Matera and Dagli, M.L.Z. 2009. Canine hemangopericytomas: cell proliferation and apoptosis in the perivascular, storiform and epithelioid histological subtypes and their significance for

prognosis. *Brazilian Journal of Veterinary Pathology*. 2: 23-28

Sims, D.E., 2000. Diversity within pericytes. *Clin Exp Pharmacol Physiol.*, 27: 842–846

**How to cite this article:**

Subapriya S., S. Vairamuthu, N. Pazhanivel, Ravi Sundar George, K. Vijayarani and Mohamed Ali M. G. 2018. Histopathological and Immunohistochemical Diagnosis of Canine Haemangiopericytoma. *Int.J.Curr.Microbiol.App.Sci*. 7(06): 1344-1348.  
doi: <https://doi.org/10.20546/ijcmas.2018.706.158>