

Original Research Article

<https://doi.org/10.20546/ijcmas.2018.705.065>

Clinico Diagnostic Studies on Traumatic Reticulopericarditis in Cattle – A Review of 56 Cases

K. Sasikala¹, G. Vijayakumar^{1*}, S. Sivaraman¹ and G.A. Balasubramaniam²

¹Department of Veterinary Clinical Medicine, ²Department of Veterinary Pathology, Veterinary College and Research Institute, Namakkal 637 002, Tamilnadu Veterinary and Animal Sciences University, Chennai, Tamil Nadu, India

*Corresponding author

ABSTRACT

Forty one Jersey cross bred and fifteen Holstein Friesian cross bred cattles were presented with the history of anorexia, pyrexia and brisket /jowl /ventral edema for 3-5 days. On clinical examination animals had tachycardia, muffled heart sounds, brisket /jowl /ventral edema, positive venous stasis, abducted elbows and pyrexia. Leukocytosis with neutrophilia, significantly elevated aspartate aminotransferase and globulin values were noticed on haemato-biochemical examination. Radiography revealed loss of thoracic details and presence of radiopaque metallic foreign body piercing the heart through diaphragm. Anechoic fluid filled pericardial cavity with or without fibrinous strands extending between walls of pericardium was appreciated through ultrasonography. Video endoscopy was done by physical restrain and could not appreciate specific changes in reticulum. 10 cattle in the near term of pregnancy were administered with streptopenicillin, frusemide, flunixin meglumine and B complex along with fluid therapy for 5 days. The pericardial drainage and lavage was done by fixing a pericardial drainage catheter. Clinical improvement was noticed on 3rd day and were discharged on 5th day.

Keywords

Cattle,
 Radiography,
 Ultrasonography,
 Reticulopericarditis,
 Therapy

Article Info

Accepted:
 07 April 2018
 Available Online:
 10 May 2018

Introduction

Traumatic reticulopericarditis is one of the major problems encountered in cattle resulting in greater economic loss to the farming community and causes mortality. Pericarditis is usually caused by long, thin sharp foreign bodies like binding wire, needle and nails that penetrate the reticulum, diaphragm and pericardial sac resulting in traumatic reticulopericarditis (Braun, 2009). Traumatic

pericarditis is also recorded in the horse (Bertone and Dill, 1985) and in lamb (Abo-Shehada *et al.*, 1991). It is the most common pericardial disorder in cattle (Bexiga *et al.*, 2008) and it is associated with progressive disturbances in heart function and almost always results in death.

Pericarditis attributable to haematogenous spread of infectious diseases (such as colibacillosis, pasteurellosis, salmonellosis

and anaerobic infections) is much less common and is usually masked by signs of septicaemia (Grunder, 2002). Idiopathic pericarditis, which is seen in humans, dogs and horses, is rare in cattle (Jesty *et al.*, 2005).

Pericarditis presents in three general forms; effusive, fibrinous and constrictive, although combinations of one or more of the three forms can occur (Radostits *et al.*, 2007). In the early stages, inflammation of the pericardium is accompanied by hyperemia and the deposition of fibrinous exudate, which produces a friction sound when the pericardium and epicardium rub together during cardiac movement (Pekins *et al.*, 2004). As effusion develops the inflamed surfaces are separated, the friction sound is replaced by muffling of the heart sounds, and the accumulated fluid compresses the atria and right ventricle, preventing their complete filling. Congestive heart failure follows.

A severe toxemia is usually present in suppurative pericarditis because of the toxins produced by the bacteria in the pericardial sac. In the recovery stage of nonsuppurative pericarditis the fluid is reabsorbed and adhesions form between the pericardium and epicardium to cause an adhesive pericarditis, but the adhesions are usually not sufficiently strong to impair cardiac movement. In suppurative pericarditis the adhesions that form become organized, starting on day 4-6 (Leak *et al.*, 1987) and may cause complete attachment of the pericardium to the epicardium, or this may occur only in patches to leave some loculi which are filled with serous fluid (Roth and King, 1991). In either case restriction of cardiac movement will probably be followed by the appearance of congestive heart failure. Death after foreign body penetration of pericardium is usually caused by progressive fibrosive constrictive pericarditis and epicarditis, cardiac tamponade from perfora of the coronary artery has also

been found (Awadhiya *et al.*, 1974). The present paper describes clinico diagnostic studies and its management of traumatic reticulopericarditis in 56 cattle.

Materials and Methods

Study area and study period

The study was conducted in the Department of Veterinary Clinical Medicine, Veterinary College and Research Institute, Namakkal during the year 2015-16. Animals from Namakkal region and its surrounding areas were selected for the study.

Selection of cases

Forty one Jersey cross bred and fifteen Holstein Friesian cross bred cattle brought to Teaching Veterinary Clinical Complex (TVCC), Veterinary College and Research Institute, Namakkal with the history of anorexia, brisket /jowl /ventral edema and pyrexia were included in the study. Among these 56 cases all were female and were between 4 - 7 years old and weighed 250 to 350 kg. Twenty eight of them had calved recently, nineteen of them were pregnant and nine of them were non pregnant. Animals brought for routine checkup and deworming during this period served as a control group for clinical parameters, radiography, ultrasonography and endoscopic evaluation.

Clinical examination

Clinical examination of the animal was undertaken as per standard methods (Rosenberger, 1979).

Haematology

Five milliliters of venous blood was collected in vacutainer tubes containing ethylene diamine tetra acetate (EDTA K₃) as

anticoagulant for haematological investigation. The parameters including packed cell volume (PCV), haemoglobin (Hb), red blood cell (RBC), white blood cell (WBC) and differential counts (DC) were done as per standard methods (Jain, 1986).

Serum biochemistry

Five milliliters of venous blood was collected in vacutainer tubes without anticoagulant taking all precautions for avoiding haemolysis as suggested by Alleman (1990). Serum was separated and used for the estimation of aspartate aminotransferase by modified IFCC method (Bergmyer, 1986), total protein by modified Biuret method and albumin by Dumans method (Varley *et al.*, 1980) by using commercially available kits (Span diagnostics, Surat, Gujarat).

Rumen fluid analysis

All the animals under study were restrained in the chute and rumen fluid was collected by using rumen fluid extraction pump. The samples were analysed as described by Rosenberger (1979).

Radiography

All the animals under study were subjected to left lateral radiograph of caudoventral thorax and reticulum in standing posture as described by Krishnamurthy and Singh (2011) using Wipro GE 525 DX fixed X ray unit. The radiographic exposure of 90 – 110 kvp, 40 – 60 mAs and source image distance of 100 cm were employed. Cassette filled with 12x15 inch blue sensitive X ray film was used for radiography.

Ultrasonography

All the animals under study were subjected to ultrasonographic examination in standing

position by using Esoate Mylab 40 Vet Ultrasound system and the reticulum was examined with 2.0 – 3.5 MHz transducer as described by Braun and Gotz (1994).

Endoscopy

Reticuloscopy was performed using (Olympus™ GIF V70; Olympus Corporation, Japan) flexible video endoscope with a diameter of 8 mm and a usable length of 150 cm that featured a channel for instruments (diameter 4 mm) and navigation system allowing the endoscope to be moved in two directions (upward 180° and downwards 100°).

Every four centimeters of the endoscope was marked with fine white lines. The instrument was equipped with a halogen light source, an irrigation system, an insufflation system and recording devices.

The use of image and data archiving system allowed digital recording of the endoscopic findings during examination. Endoscopic procedure of passing the endoscope up to oesophagus as described by Franz and Baumgartner (2002) and up to reticulum as described by Sasikala *et al.*, (2017) was followed.

Endoscopic biopsy

Biopsy forceps was passed through the working channel of the video endoscope and the tissue sample was collected. It was stored in 10 per cent formalin and subjected to the histopathological examination as described by Bancroft and Gamble (2008).

Pericardiocentesis

A two cm long vertical nick was made on the skin at the fifth intercostal space on the left side at the level of point of elbow. Trocar catheter 28 FG (Romsons Scientific and

Surgical Industry Pvt. Ltd, India) with inflated balloon was passed through this nick and slowly advanced till the pericardial exudates were evident under ultrasound guidance and the trocar was withdrawn. The catheter was fixed to the skin using Chinese finger trap suture (Fossum, 2007) and the pericardial fluid was allowed to drain (Fig. 8). The catheter was maintained for five to seven days till cessation of pericardial exudation. Pericardial cavity was lavaged with normal saline as described by Jesty *et al.*, (2005) followed by metronidazole (1500 mg) for 5 days.

Statistical analysis

The data obtained were statistically analyzed as described by Snedecor and Cochran (1994).

Results and Discussion

Clinical examination

The clinical signs in cattle with traumatic reticulopericarditis are given in Table 1. The predominant clinical signs were tachycardia, tachypnoea, bruxism, brisket /jowl /ventral edema (Fig. 1), distended jugular vein, positive venous stasis (Fig. 2), pyrexia, grunting, abducted elbows and muffled heart sounds.

Haemato-biochemistry

The results of the haemato-biochemistry are given in Table 2. Leukocytosis with neutrophilia, significantly elevated aspartate aminotransferase and globulin values were predominant findings.

Rumen fluid examination

Rumen fluid examination results are given in Table 3. Sluggish rumen protozoal motility was predominant in all the cases.

Radiography

It revealed loss of thoracic details (Fig. 3) in 46.42 per cent (26/56) of cases and presence of radiopaque metallic foreign body piercing the heart through diaphragm (Fig. 4) in 44.64 per cent (25/56) of cases (Plate 20).

Ultrasonography

Anechoic fluid filled pericardial cavity with or without fibrinous strands extending between walls of pericardium was appreciated through ultrasonography in all the cases (56/56) (Fig. 5).

Endoscopy and biopsy

Reticuloscopy could not appreciate specific changes in reticulum (Fig. 6). On histopathological examination reticulum showed nodular hyperplasia of stratified squamous epithelium (Fig. 7).

Treatment

Of the 56 animals with traumatic reticulopericarditis only 10 owners of cattle in the near term of pregnancy accepted for treatment. These cases were administered with streptopenicillin (@5 g IM twice daily), frusemide (@2 mg/kg IM twice daily), flunixin meglumine (@2.2 mg/kg IM twice daily) and B complex (@10 ml IM twice daily) along with fluid therapy (DNS @5 ml/kg IV twice daily) for 5 days. Pericardial drainage catheter was fixed and lavaged.

The effusion reduced by 3rd day and the catheter was removed on 5th day. Clinical improvement was noticed on 3rd day and was discharged on 5th day. Then cattle were followed up to calving and six animals had calved normally but subsequently developed severe signs of congestive heart failure, while four animals died before calving.

Table.1 Clinical manifestations in cattle with traumatic reticulopericarditis (%)

Sl. No	Clinical signs	Number	Traumatic reticulopericarditis (n=56)
1.	Abducted elbows	38	67.85
2.	Anorexia	52	92.85
3.	Arched back	38	67.85
4.	Brisket / jowl edema	52	92.85
6.	Bruxism	54	96.42
7.	Diarrhoea	4	7.14
8.	Distended jugular veins	52	92.85
9.	Grunting	42	75.00
10.	Hypermotility of rumen	0	0.00
11.	Marked drop in milk yield	50	89.28
12.	Muffled heart sounds	34	60.71
13.	Positive venous stasis	52	92.85
14.	Pyrexia	52	92.85
15.	Recurrent tympany	12	21.42
16.	Recumbency	19	33.92
17.	Regurgitation	0	0.00
18.	Ruminal atony	52	92.85
19.	Scanty faeces	48	85.71
20.	Tachypnoea	54	96.42
21.	Tachycardia	56	100.00

Table.2 Haemato-biochemistry in apparently healthy cattle and cattle with traumatic reticulopericarditis

Sl. No	Parameters	Apparently healthy cattle (n=20) Mean ± SE	Traumatic reticulopericarditis (n=20) Mean ± SE	Indication
1.	Haemoglobin (g/dl)	11.20 ± 0.09	11.35 ± 0.19	Normal
2.	Packed cell volume (%)	34.35 ± 0.46	34.05 ± 0.58	Normal
3.	Red Blood cell count (10 ⁶ / cumm)	6.47 ± 0.08	6.48 ± 0.09	Normal
4.	White blood cell count (10 ³ / cumm)	6.58 ^a ± 0.11	18.19 ^b ± 0.50	Elevated
5.	Neutrophils (10 ³ / cumm)	2.24 ^a ± 0.05	13.73 ^b ± 0.43	Elevated
6.	Lymphocytes (10 ³ /cumm)	4.31 ± 0.07	4.48 ± 0.14	Normal
7.	Monocytes (10 ³ / cumm)	0.13 ± 0.06	0.09 ± 0.09	Normal
8.	Eosinophils (10 ³ / cumm)	0.07 ± 0.04	0.16 ± 0.51	Normal
9.	Aspartate amino transferase (AST) (units/L)	100.45 ^a ± 2.85	159.80 ^b ± 6.43	Elevated
10.	Total protein (g/dL)	6.28 ± 0.23	7.83 ± 0.22	Normal
11.	Albumin (g/dL)	2.98 ± 0.05	2.54 ± 0.07	Normal
12.	Globulin (g/dL)	3.30 ^a ± 0.22	5.29 ^c ± 0.22	Elevated

Note: Mean bearing same superscript in same row does not differ significantly

Table.3 Rumen fluid analysis in apparently healthy cattle and cattle with traumatic reticulopericarditis

Sl. No	Parameters		Apparently healthy cattle (n=20)	Traumatic reticulopericarditis (n=20)
1.	Colour		Yellowish to brown	Yellowish to brown
2.	Consistency		Slightly viscous	Watery
3.	Odour		Aromatic	Aromatic
4.	SAT (min)		4.33 ^b ± 0.21	2.83 ^a ± 0.54
5.	pH		6.48 ^b ± 0.11	6.58 ^b ± 0.11
6.	MBRT (min)		2.50 ^a ± 0.22	6.83 ^b ± 0.47
7.	Titratable acidity (units)		17.50 ^a ± 1.11	17.50 ^a ± 1.11
8.	Protozoa	Size	Medium and Small	Nil
		Density	++	Nil
9.	Iodophilic activity		+++	+

Note: Mean bearing same superscript in same row do not differ significantly



Fig.1 Brisket /jowl /ventral edema



Fig.2 Engorged jugular vein and positive venous stasis



Fig.3 Lateral Radiography - Loss of thoracic details



Fig.4 Lateral Radiography - Radiopaque metallic foreign body piercing the heart through diaphragm (arrow)

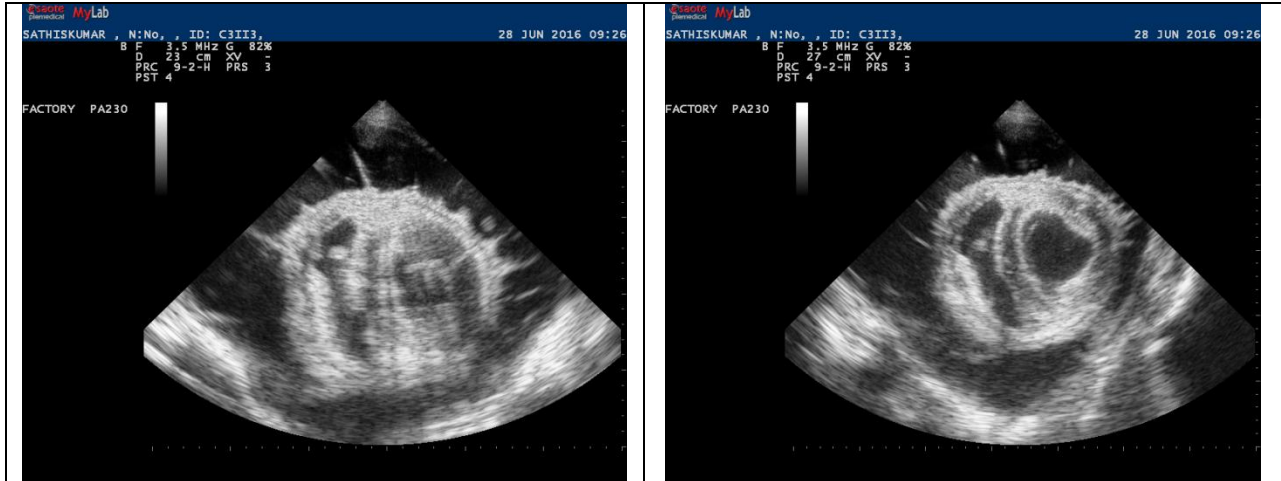


Fig.5 Anechoic fluid surrounding the myocardium with fibrinous strands extending between the pericardial walls

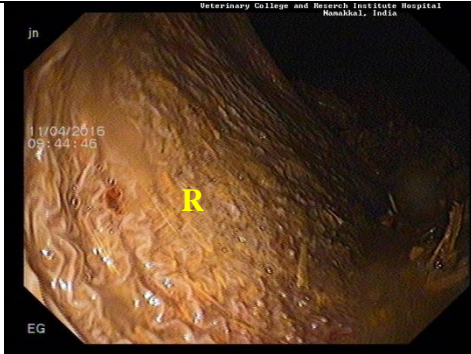


Fig.6 Endoscopic imaging of normal reticulum (R) in traumatic reticulopericarditis

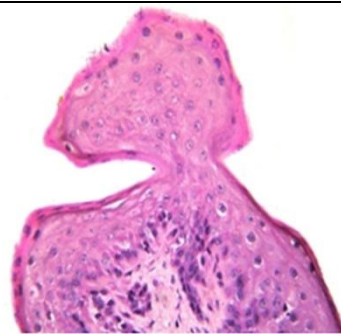


Fig.7 Nodular hyperplasia of stratified squamous epithelium of reticulum. H&E stain; 40x

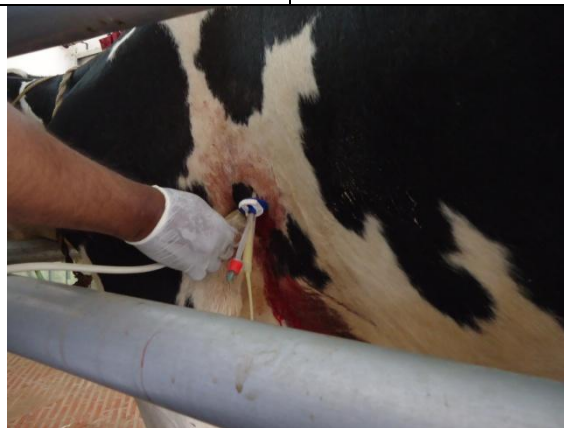

Fig.8 Ultrasound guided pericardial drainage by pericardial drainage catheter with inflated balloon

Cattle are more susceptible to foreign body syndrome, due to lack of oral discrimination. Pericarditis is the inflammation of both parietal and visceral surfaces of the pericardium with accumulation of serous or

fibrinous inflammatory products (Reef and McGuirk, 2009). It is associated with progressive disturbances in cardiac function and almost always results in death (Braun, 2009). Athar *et al.*, (2012) reported higher

incidence of traumatic pericarditis and hepatic congestion in female cattle and buffaloes which were in advanced stage of pregnancy and calved recently. Idiopathic fibrinous pericarditis in an eight years old Nili-Ravi buffalo was reported by Sharma *et al.*, (2012).

Clinical examination

Tachycardia, tachypnoea, muffled heart sounds, bruxism, distended jugular vein, positive venous stasis, brisket and / or ventral edema, abducted elbows, bruxism, pyrexia and grunting were observed in cattle with traumatic reticulopericarditis (Radostits *et al.*, 2007; Braun, 2009; Sharma *et al.*, 2012). Mohamed (2010) recorded presternal oedema, abnormal heart sounds, jugular, mammary vein distension and pulsation and positive for various pain tests in buffaloes with traumatic pericarditis. Tachycardia, muffled heart sounds, distended jugular veins, pericardial sounds like splashing, rubbing or squeaking sounds, brisket and ventral oedema were observed in cattle with traumatic reticulopericarditis (Ramin *et al.*, 2011). Tharwat (2011) observed anorexia, recurrent tympany, presternal and ventral oedema and diarrhoea in cattle with traumatic pericarditis. Similar clinical findings were observed in the present study.

Haemato-biochemistry

Leukocytosis with neutrophilia and elevated levels of aspartate aminotransferase and globulin values were in agreement with the previous studies (Sharma *et al.*, 2012; Habasha and Yassein, 2014). Marked leukocytosis with neutrophilia, as well as hyperglobulinemia are usually present in cattle with traumatic pericarditis (Radostits *et al.*, 2007). Increase in total leukocyte count with neutrophilic leukocytosis, lowered A/G ratio due to decreased albumin and increased globulin levels were noticed in animals with

traumatic pericarditis (Athar *et al.*, 2011). These changes were often a reflection of cellular destruction and inflammatory response to foreign bodies.

Rumen fluid examination

Reddy *et al.*, (2014) recorded viscous rumen fluid, pH 7.0 and 'single +' protozoal concentration with sluggish motility in cattle with traumatic reticuloperitonitis / pericarditis. Similar changes were noticed in the present study.

Radiography

In the present study, radio-opaque foreign bodies could be appreciated radiographically only in 44.64 per cent of animals. This could be due to the insufficient density of the foreign bodies to be visualized in the radiograph and owing to the increased thickness of the thorax / abdomen of the cattle. Khalphallah *et al.*, (2015) reported that radiography failed to identify inflammatory changes that occurred on the reticular serosa or failed to show any abnormalities in the heart / reticulum. Radiography was the best method for visualizing the metallic foreign bodies in and outside the reticulum and the position of the foreign body was not a reliable indicator of the condition (Braun *et al.*, 1993). Visualization of foreign body within the reticulum in some of the cases in the present study was in concurrence with reports of Braun *et al.*, (1993). Loss of details in radiography of cattle with traumatic pericarditis could be due to the presence of large amounts of fibrinous exudates in the pericardial sac.

Ultrasonography

Ultrasonographic findings in traumatic reticulopericarditis were represented as mixed echogenicities in the pericardial sac. This

might be due to the presence of turbid pericardial fluid, which in more progressive cases of pericarditis, appeared as extensive hyperechoic strands in the pericardial sac. Ultrasonographic examination revealed presence of large network representing fibrin, fibrinous exudates and fluid in pericardial sac in the traumatic pericarditis and affecting the basic cardiac function (Braun, 2009; Danjuma *et al.*, 2014).

Endoscopy and biopsy

Endoscopic imaging is highly useful for the diagnosis of intraluminal changes associated with diseases of reticulum in cattle. On histopathology reticulum showed nodular hyperplasia of stratified squamous epithelium. Similar changes were noticed by Maxie (2016) in cattle with traumatic reticulopericarditis.

Therapy

Broad spectrum antibiotics, pericardiocentesis, pericardial lavage and non-steroidal anti-inflammatory drugs were effectively used for the management of traumatic reticulopericarditis (Radostits *et al.*, 2007).

Reef and McGuirk (2009) reported that treatment of traumatic pericarditis was unrewarding in cattle and usually was addressed toward salvage or short term survival to calving.

The observations in the present study were supported by the reports of Radostits *et al.*, (2007) and Reef and McGuirk (2009).

Ultrasonography was able to diagnose traumatic reticulopericarditis effectively. It is complementary to clinical, radiographic and endoscopic evaluation in cattle with traumatic reticulopericarditis.

Acknowledgement

The authors are very thankful to the Dean, Veterinary College and Research Institute, Namakkal for the facilities provided during the study.

References

- Abo-Shehadeh, M.N.; Al-Rawashdeh, O., and Al-Natour, M. 1991. Traumatic pericarditis in an Awassi lamb. *Br. Vet. J.*, 147(1): 78-81.
- Alleman, A. R., 1990. The effects of haemolysis and lipemia on serum biochemical constituents. *Vet. Med.*, 89: 1272-1284.
- Athar, H., Mohindroo, J., Randhawa, C. S., Singh, K. and Saini, N. S. 2011. Clinical, haemato biochemical, radiographic and ultrasonographic findings in bovines suffering from pericarditis and pleural effusions. *Indian J. Anim. Sci.*, 81: 48.
- Athar, H., Parrah, J. D., Moulvi, B. A., Singh, M. and Dedmari, F. H. 2012. Pericarditis in bovines - A review. *Intern. J. Adv. Vet. Sci. Tech.*, 1: 19-27.
- Awadhiya, R.P., Kolte, G.N. and Vegad, J.L. 1974. Cardiac Tamponade: A Fatal Complication of Traumatic Reticulitis in Cattle. *Vet Rec.* 95: 260-262.
- Bancroft, J.D. and Gamble, M. 2008. Theory and practice of histological techniques. 6th edn., Churchill Livingstone, London. pp. 75-82.
- Bergmyer, H. U., 1986. Approved recommendation of IFCC method for measurement of catalytic concentration of enzymes. Part 2. IFCC methods for aspartate amino transferase. *J. Clin. Chem. Clin. Biochem*, 24: 497-510.
- Bertone, J.J. and Dill, S.G. 1985. Traumatic gastropericarditis in a horse. *J. Am. Vet. Med. Assoc. (USA)*. 187: 742-743.

- Bexiga, R., Mateus, A., Philbey, A.W., Ellis, K., Barrett, D.C., and Mellor, D.J. 2008. Clinicopathological Presentation of Cardiac Disease in Cattle and Its Impact on Decision Making. *Vet Rec.* 162: 575-80.
- Braun, U. and Gotz, M. 1994. Ultrasonography of the reticulum in cows. *Am. J. Vet. Res.*, 55: 325-332.
- Braun, U., Fluckiger, M. and Nageli, F. 1993. Radiography as an aid in the diagnosis of traumatic reticuloperitonitis in cattle. *Vet. Rec.*, 132: 103-109.
- Braun, U. 2009. Traumatic pericarditis in cattle: Clinical, radiographic and ultrasonographic findings. *Vet. J.*, 182: 176-186.
- Danjuma, F.A., Otolorin, G.R., Mshalbwala, P.P. and Abubakar, A. 2014. Acute traumatic pericarditis in a 4 – 8 years old Bunaji bull: A case report. *Res.*, 1: 960.
- Fossum, T.W., 2007. *Small Animal Surgery*, Mosby Elsevier, USA. pp. 103.
- Franz, S. and Baumgartner, W. 2002. A retrospective study of oesophageal endoscopy in cattle and oesophagoscopy for diagnosis of mucosal disease. *Vet. J.*, 163: 205-210.
- Grunder, H.D., 2002. Krankheiten des Herzens und des Herzbeutels. In: Dirksen, G., Grunder, H.D., Stober, M. (Eds.), *Innere Medizin und Chirurgie des Rindes*, fourth ed. Parey Buchverlag, Berlin, pp. 159–181.
- Habasha, F.G. and Yassein, S.N. 2014. Advance techniques in traumatic reticuloperitonitis diagnosis: A review. *Al-Qadisiya J. Vet. Med. Sci.*, 13: 50-57.
- Jain, N. S., 1986. Haematological techniques. In: Schalm's *Veterinary Haematology*. 4th edn., Lea and Febiger, Philadelphia. pp. 20-86.
- Jesty, S.A., Sweeney, R.W., Dolente, B.A. and Reef, V.B., 2005. Idiopathic pericarditis and cardiac tamponade in two cows. *Journal of the Am. Vet. Med. Assoc.*, 226, 1555–1558.
- Khalphallah, A.A., El-Sebaie, A.H. and Raghieb, M.F. 2015. Approach for diagnosis of complicated traumatic reticuloperitonitis in cattle using ultrasonography. *J. Adv. Vet. Res.*, 5: 157-164.
- Krishnamurthy, D. and Singh, A.P. 2011. Contrast techniques. In: Singh, J (ed): *Veterinary radiology. Basic principles and radiographic positioning*. CBC publishers, New Delhi. pp. 184-189.
- Leak, L.V., Ferrans, V.J., Cohen, S.R., Eidbo, E.E. and Jones, M. 1987. Animal model of acute pericarditis and its progression to pericardial fibrosis and adhesions: ultrastructural studies. *Am J Anat.*, 180: 373–90.
- Maxie, M.G. 2016. Jubb, Kennedy and Palmer's: *Pathology of domestic animals*. 6th edn, Elsevier, St. Louis, Missouri. pp. 35-43.
- Mohamed, T., 2010. Clinicopathological and ultrasonographic findings in 40 water buffaloes (*Bubalus bubalis*) with traumatic pericarditis. *Vet. Rec.*, 167: 819-824.
- Pekins, S.L., Magdesian, K. G., Thomas, W. P. and Spier, S. J. 2004. Pericarditis and Pleuritis Caused By *C. Pseudotuberculosis* in a Horse. *J Am Vet Med Assoc.*, 224: 1133-1138.
- Radostits, O.M., Gay, C.C., Hinchcliff, K.W. and Constable, P.D. 2007. *Veterinary Medicine. A textbook of the diseases of cattle, horses, sheep, pigs and goats*. 10th edn., W.B. Saunders Elsevier, Philadelphia. pp. 211-215.
- Ramin, A. G., Hashemi, A. M., Asri-Rezaie, S., Batebi, E., Tamadona, A. and Ramin, S. 2011. Prediction of traumatic pericarditis in cows using some serum biochemical and enzyme parameters. *Acta. Vet.*, 61: 383-390.

- Reddy, B. S., Reddy, L. S. S. V. Sivajothi, S. and Reddy, B. S. 2014. Traumatic reticuloperitonitis in cattle: A clinical study. *Intern. Sci. World.*, 2: 13-15.
- Reef, V.B., and McGuirk, S.M. 2009: Diseases of Cardiovascular System. In: Smith B.P. (Ed). *Large Animals Internal Medicine*, 4th Ed., Mosby Inc. Philadelphia, USA, 474-478.
- Rosenberger, G., 1979. Clinical examination of cattle. 2nd edn, Verlag Paul Parey, Berlin and Hamburg, Germany. pp. 184-212.
- Roth, L. and King, J.M. 1991. Traumatic reticulitis in cattle: a review of 60 fatal cases. *J. Vet. Diag. Invest.*, 3: 52.
- Sasikala, K., Vijayakumar, G., and Balasubramaniam, G.A., 2017. Endoscopic Evaluation of Reticulum in Cattle - A Preliminary Study. *Indian Vet. J.*, 94 (05): 79 – 80.
- Sharma, S., Gosal, N.S. and Varun. 2012. Idiopathic fibrinous pericarditis in a Nili-Ravi buffalo. *Buffalo Bulletin*, 31: 171-175.
- Snedecor, G. W. and W. G Cochran, 1994. *Statistical methods*. 8th edn., Iowa State University Press, Ames, Iowa.
- Tharwat, M., 2011. Traumatic pericarditis in cattle: Sonographic, echocardiographic and pathologic findings. *J. Agri. Vet. Sci.*, 4: 45-59.
- Varley, H., Grawlock, A. H. and Bell, M. 1980. *Practical Clinical Biochemistry*. Vol. I. 5th edn., William Heinmann Medical Books Ltd., London, pp. 186.

How to cite this article:

Sasikala, K., G. Vijayakumar, S. Sivaraman and Balasubramaniam, G.A. 2018. Clinico Diagnostic Studies on Traumatic Reticulopericarditis in Cattle – A Review of 56 Cases. *Int.J.Curr.Microbiol.App.Sci*. 7(05): 513-523. doi: <https://doi.org/10.20546/ijcmas.2018.705.065>