

Original Research Article

<https://doi.org/10.20546/ijcmas.2018.704.398>

Histological Alterations in the Hepatopancreas and Growth Performance of Pacific White Shrimp (*Litopenaeus vannamei*, Boone 1931) Reared in Potassium Fortified Inland Saline Ground Water

Madhuri S. Pathak^{1*}, Appidi K. Reddy¹, M.V. Kulkarni², V. Harikrishna³,
Prem P. Srivastava⁴, N.K. Chadha¹ and Wazir S. Lakra³

¹Aquaculture Division, Central Institute of Fisheries Education, Off Yari Road,
PanchMarg, Mumbai – 400 061, MS, India

²Soil and Land use Survey of India

³Central Institute of Fisheries Education, Off Yari Road, PanchMarg,
Mumbai – 400 061, MS, India

⁴Fish Nutrition, Biochemistry and Physiology Division, Central Institute of Fisheries
Education, Off Yari Road, PanchMarg, Mumbai – 400 061, MS, India

*Corresponding author

ABSTRACT

Study was conducted to determine the effect of potassium fortification on histological alterations of hepatopancreas and growth performance of pacific white shrimp, *Litopenaeus vannamei*, reared in different salinities of inland saline ground water (ISGW). Shrimps were subjected to different salinities (5 ppt, 10 ppt and 15 ppt) with potassium fortified to 25% (T1), 50% (T2), 75% (T3) and 100% (T4), ISGW without supplementation *i.e.* raw water (RW) and Artificial sea water (ASW). Significant increase in growth was observed with the enhanced salinity and K⁺ fortification during the experimental period of 60 days. Final weight and weight gain of shrimp reared at 15ppt was significantly higher in ISGW of 15 ppt, fortified with 100% K⁺ to the level of ASW. Distinct histological alterations were observed at 5ppt and 10ppt salinity and in less K⁺ levels. However, at 15 ppt ISGW there were insignificant changes in hepatopancreas and almost similar to that of the shrimps reared in ASW. Thus the results of this study suggests that K⁺ deficiency in ISGW has a negative effect on hepatopancreas histology and growth of *L. vannamei* post-larvae, augmenting importance of K⁺ fortification in ISGW to a similar level as in ASW for its culture.

Keywords

Pacific white shrimp,
Litopenaeus vannamei,
Inland saline ground
water, Hepatopancreas,
Histological alterations

Article Info

Accepted:
28 March 2018
Available Online:
10 April 2018

Introduction

Increasing problem of ground water salinity have become serious issues of concern as they affect productivity and threaten the sustainability of agriculture and environment.

Countries with notable salinity problems include Australia, China, Egypt, Iraq, Mexico, USA, Pakistan, Turkey and India. The ionic profile of Inland saline ground water (ISGW) is similar to sea water (SW) (Nulsen, 1997) but the concentration of potassium (K⁺) is

significantly lower than in SW (Fielder *et al.*, 2001; Prangnell and Fotedar, 2005). The deficient K^+ can be added through feed or by direct addition to the water as potash or potassium chloride (Fielder *et al.*, 2001, Boyd, 2002; Gong *et al.*, 2004; McNevin *et al.*, 2004; Davis *et al.*, 2005). K^+ is an obligatory requirement for Na^+/K^+ -ATPase activity, which plays an important role in whole body ion regulation and osmoregulation in crustaceans.

The penaeid hepatopancreas is a large, compact, paired glandular organ occupying a substantial portion of the cephalothoracic cavity. Five types of cells have been identified in the hepatopancreatic tubule epithelium, the E- (embryonic or Embryozellen) cells, F- (fibrillar) cells, B- (blister-like or Blastozellen) cells (Jacobs, 1992), R- (resorptive/ absorptive or Restzellen) cells and the more recently discovered M- (midget) cells (Al-Mohanna, 1983) play their individual roles in digestion, absorption and excretion. The hepatopancreas, being analogous to the liver and combining many of the functions of the liver, pancreas, and intestine of vertebrates, plays important roles in several metabolic processes in crustaceans (Caceci *et al.*, 1988; Bhavan and Geraldine, 2000). The organ undergoes histological modifications in response to different environmental changes such as salinity (Masson, 2001; Cuartas *et al.*, 2003). Histological studies provides information on the degree of stress, susceptibility and adaptive capability of the shrimps however, the histological alterations in hepatopancreatic tissues of *Litopenaeus vannamei* have never been examined when reared in K^+ fortified ISGW. The *L. vannamei* (Pacific white shrimp) is a euryhaline species so the ability to tolerate a wide range of salinities (0.5– 40.0 ppt) has made it a popular species for low salinity culture (Samocha *et al.*, 2002; McGraw and Scarpa, 2003). The aim of this study was to examine the histological

alterations in hepatopancreas and growth performance of *L. vannamei* reared at K^+ supplemented ISGW; this might provide cytological evidence in the adaptations of *L. vannamei* in ISGW.

Materials and Methods

Experimental Animals

L. vannamei post-larvae with mean body weight of 96.40 ± 0.32 mg, were procured from “Saranya Hatcheries”, Uppada, Kakinada, East Godavari District, Andhra Pradesh, India and acclimated in fish farm, Rohtak for three days, to different test salinities (5, 10 and 15 ppt) by gradually adding ISGW. After acclimatization to the respective test salinities, they were transferred to experimental tanks for initiation of experiment. The experimental animals were fed with *Artemia nauplii* for the first 15 days and then for rest of experiment they were fed ad libitum with commercial feed (C.P starter feed No. 5001, 38 % crude protein, 5% fat, 12% moisture and 4% fibre) twice a day (6:00 and 16:00).

Experimental set-up

The experiment was carried out in an indoor pilot hatchery at Lahli-Baniyani Fish Farm of the Central Institute of Fisheries Education, Rohtak, Haryana, India. The shrimps were reared in ISGW supplemented with K^+ for a period of 60 days during September-12 & October-12. Experiment was performed in FRP circular tanks of 60 cm diameter and 35.5 cm height with 100 L capacity. Each treatment and control groups was maintained in three replicates wherein each replication was stocked with 35 shrimps (a total of 105 shrimps for each treatment). In order to maintain optimum water quality, experimental tanks were cleaned manually once in 2 days to remove excess feed and fecal matter and 80 % of water was exchanged at 10 days interval.

During the experiment, water quality parameters such as dissolved oxygen, temperature, pH and salinity were recorded once in a week. Dissolved oxygen was above 7.5 mg/L, pH 8.2±0.2, water temperature was 27°C±0.5°C.

Treatments

ISGW of 17 ppt was obtained from well located near hatchery. The salinity of well water was reduced to three different test salinities (5, 10 and 15 ppt) using river water. The potassium concentration of ISGW of 5, 10 and 15 ppt was 8.4, 15.6 and 22.8 ppm respectively, which is very less for the survival of *L. vannamei*. Thus K⁺ supplementation was carried out with fertilizer-grade potassium chloride (Containing 50 % K⁺) to increase K⁺ concentration in ISGW to 25%, 50%, 75% and 100% of the artificial sea water (ASW) concentration (T1, T2, T3 and T4 respectively). ASW and ISGW without supplementation i.e. raw water (RW) were kept as control for each salinity in triplicate. ASW for each experimental salinities 5, 10 and 15 ppt were prepared following the method of (Valenti and Danaels, 2000). The K⁺ concentration of ISGW at different salinities before and after supplementation was analyzed by flame photometer (Table 1). The quantity of K⁺ required was calculated by using a protocol (Gong *et al.*, 2004).

Requirement of K⁺ in ISGW = (10.7 x desired salinity) - available K⁺ in ISGW

Growth performance

Growth performance was analyzed by determining weight gain obtained during the experimental period. Mean body weight of experimental animals was recorded at the beginning and at the end of the experimental period of 60 days. Before recording the body

weight, the animals were kept starved overnight.

Histological studies

Shrimps were collected after 60- days experiment to study the histological changes occurred as a result of salinity and different levels of potassium concentrations. Shrimps from each tank were selected at random, the anterior and posterior abdominal regions were injected with Bouin's solution (Li *et al.*, 2007) and the shrimps were left in the same solution to ensure tissue fixation. Shrimps were later transferred to 50% ethanol, the gill tissues were dissected, dehydrated in increasing ethanol concentrations, embedded in paraffin and 5 µm sections were obtained with a conventional microtome. The sections were re-hydrated, stained with hematoxylin-eosin (Yang *et al.*, 2007) Slides were examined under a light microscope (Model: Zeiss, Scope A1, Germany) and photographs were taken at 40X.

Statistical analysis

Statistical analysis of the data was carried out with Statistical Package used for the Social Sciences (SPSS), version 16.0. Two-way analysis of variance (ANOVA) was conducted to evaluate the significant difference between the treatments at different salinities and various potassium concentrations. One-way ANOVA followed by a Tukey's test was employed to compare the significant difference between treatments at a given point at 5 % level of significance.

Results and Discussion

Growth performance

Compared to the shrimp reared in RW all the four treatments i.e. T1, T2, T3 and T4 showed significant increase in body weight (Table 2).

Mean final weight and weight gain of *L.vannamei* in treatment T4 (100%) and 15ppt salinity was significantly higher (2.12 g and 2089 % respectively) than the other treatments and salinities. Treatments with lesser levels of K⁺ fortification, T1 (25%) and T2 (50%) reported lowest weight gain compared to treatment T4. All the three salinity groups (5 ppt, 10 ppt and 15 ppt) showed significant increase in shrimp body weight as the K⁺ concentration increased in ISGW. Among the different salinity groups as the salinity increased from 5 ppt to 15 ppt weight gain increased significantly in all treatment groups.

Histoarchitecture of the hepatopancreas of control shrimp

The hepatopancreas of shrimps reared in ASW exhibited the well-organized glandular tubular structure normally seen in *L.vannamei*. (Fig. 1A (5 ppt), Fig. 2G (10 ppt) and Fig. 3M (15 ppt). Shrimp hepatopancreas are composed of many hepatopancreas tubules dominating four kinds of cells namely E (“embryonalzellen” or embryonic) cells, R (“restzellen”) cells, F (“fibrillenzellen” or fibrous) cells, and B (“blasenzellen”) cells. The cells showed normal architectural differentiation into E (embryonic) cells at the narrow distal end of the tubule, young R (restzellen) cells and F (fibrillenzellen) cells a short distance away from the distal region, and B (blasenzellen) cells in the middle and proximal regions of the tubules.

The B-cells exhibited large apical secretory granules, the R-cells were found to contain large amounts of rough endoplasmic reticulum and lipid droplets, while the F-cells were found to be non-vacuolated and well stained. The tubule lumen was found to have a normal “star like” structure. A single layer of epithelial cells was observed as lining the tubules. The interstitial sinuses between tubules were normal (Fig. 1A, Fig. 2G and

Fig. 3M). The structure of hepatopancreas was not normal in ISGW control as in ASW control due to the deficiency of K⁺ (Fig. 1B, Fig. 2H and Fig. 3N).

Histoarchitecture of the hepatopancreas of shrimp exposed to different salinity and fortified potassium

Abnormal lumen (ALU) and hemocytic infiltration (HI) in the interstitial sinus (IS) were observed in the hepatopancreas of *L.vannamei* exposed to 5 ppt and 75%, 100% (Fig. 1E & F) K⁺ fortification. In shrimp exposed to the higher concentration of salinity (10ppt), the distinct alterations observed were not observed as in case of 5 ppt and 25%, 50% i.e. separation of necrotic cells of hepatopancreas (NCH) from basal laminae (BL); thickened basal laminae (TBL); necrotic tubules (NT) of the hepatopancreas containing tissue debris (TD) in the lumen; occurrence of melanization (MZ) and coagulation (CO) in the thickened basal laminae; walling off of the tubules by hemocytes (HC) around the thickened basal laminae (Fig. 2 I and J).

Vacuolation features were observed in hepatopancreas tissue of the shrimp in all treatments. The cells showed normal architectural differentiation into E cells at the narrow distal end of the tubule, young R cells and F cells a short distance away from the distal region, and B cells in the middle and proximal regions of the tubules in 10 ‰ salinity, with the distinct and clear architects of the cellular structures with 75% and 100% (Fig. 2K and L) K⁺ fortifications. The shrimps exposed to the salinity 15 ppt with 75% and 100% K⁺ fortification were observed to be normal structure, the tubule lumen was found to have a normal “star like” structure. A single layer of epithelial cells was observed as lining the tubules. The interstitial sinuses between tubules were normal (Fig. 3Q and R) and were similar to the control (Fig. 3M).

Fig.1 Hepatopancreas of *Litopenaeus vannamei* in different potassium fortification levels in ISGW of 5 ppt salinity; A: ASW, B: RW, C: T1, D: T2, E: T3 and F: T4 (Nuc - Nucleus, Lum - Lumen, Vac - Vacuoles, Alu - Abnormal lumen, TD - Tissue debris, Hi - Hemocytin filtration, Hpb - Hepatopancreatic Blaszellen or B cells, Hpr-, Is - Interstitial sinuses, Mfn - Myoepithelial cells, Sin-Hemal sinuses, Hpf - Hepatopancreatic Fibrillenzellen or F cells)

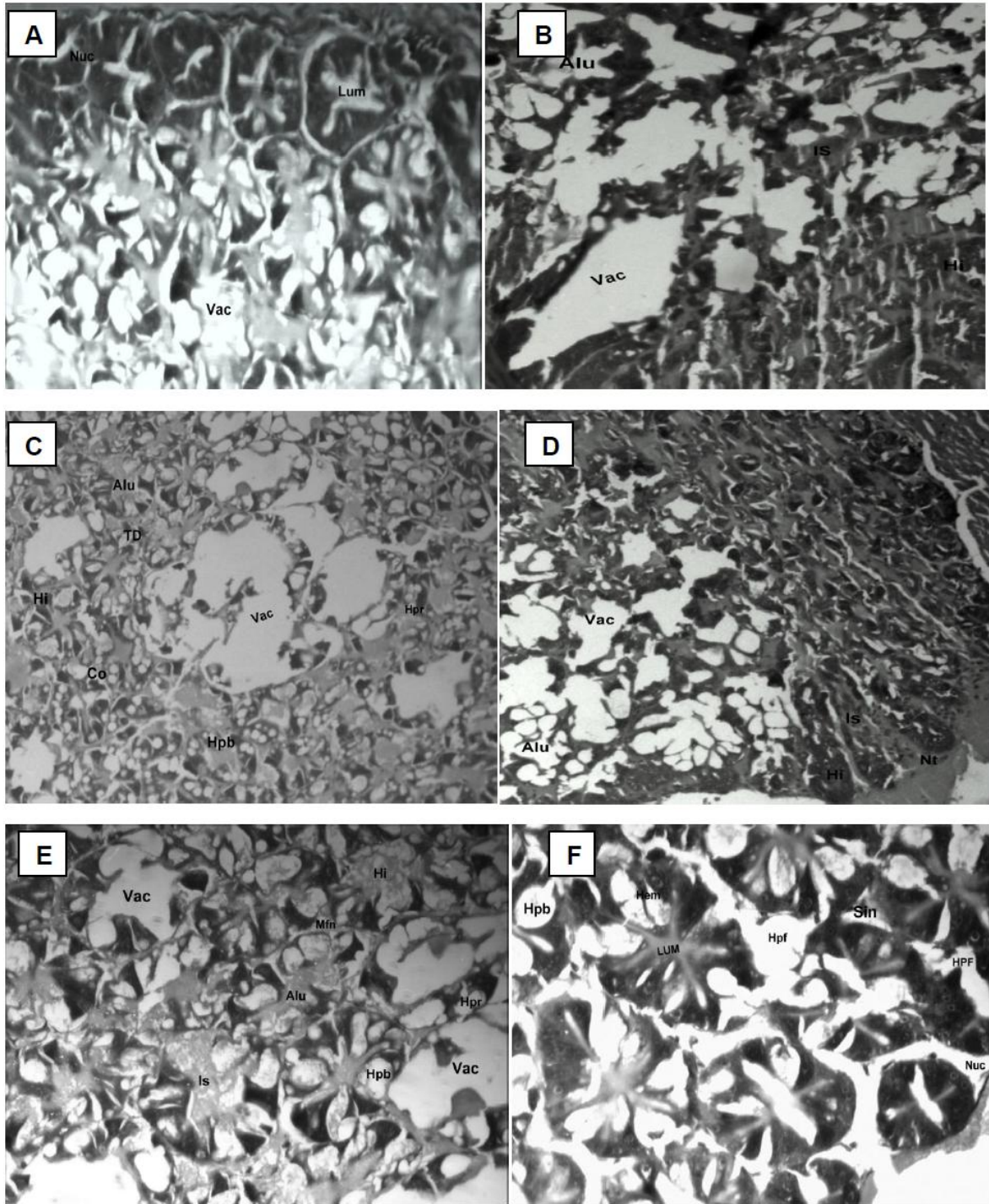


Fig.2 Hepatopancreas of *Litopenaeus vannamei* in different potassium fortification levels in ISGW of 10ppt salinity; G: ASW, H: RW, I: T1, J: T2, K: T3 and L: T4 (Lum- Lumen, Vac- Vacuoles, Alu - Abnormal lumen, TD - Tissue debris, Hi – Hemocytic infiltration, Hpb- Hepatopancreatic Blasenzellen or B cells, Hpr- R cells, Is - Interstitial sinus, Mfn - Myoepithelial cells, Sin - Hemal sinuses, Mef - Myoepithelial fibers, Hpf – Hepatopancreatic Fibrillenzellen or F cells, Hem - Hemocyte, NCH- Necrotic cells of hepatopancreas, NT- necrotic tubules, Brb- Brush border

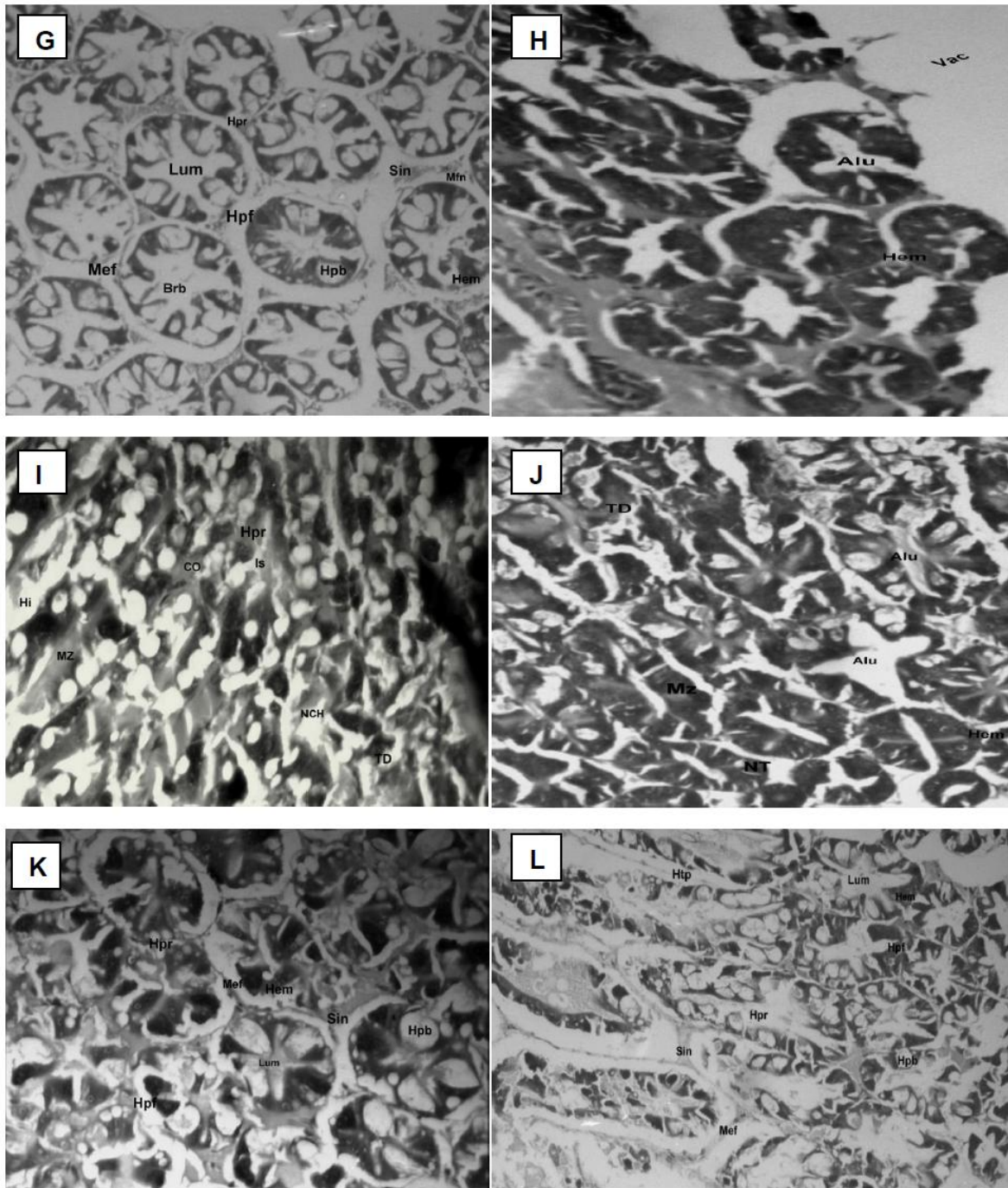


Fig.3 Hepatopancreas of *Litopenaeus vannamei* in different potassium fortification levels in ISGW of 10 ppt salinity; M: ASW, N: RW, O: T1, P: T2, Q: T3 and R: T4 (Lum - Lumen, Vac - Vacuoles, Alu - Abnormal lumen, TD - Tissue debris, Hi - Hemocytic infiltration, Hpb - Hepatopancreatic Blasenzellen or B cells, Hpr- R cells, Is - Interstitial sinus, Mfn - Myoepithelial cells, Sin - Hemal sinuses, Mef - Myoepithelial fibers, Hpf - Hepatopancreatic Fibrillenzellen or F cells, Hem - Hemocyte, NCH - Necrotic cells of hepatopancreas, NT - Necrotic tubules, Brb - Brush border)

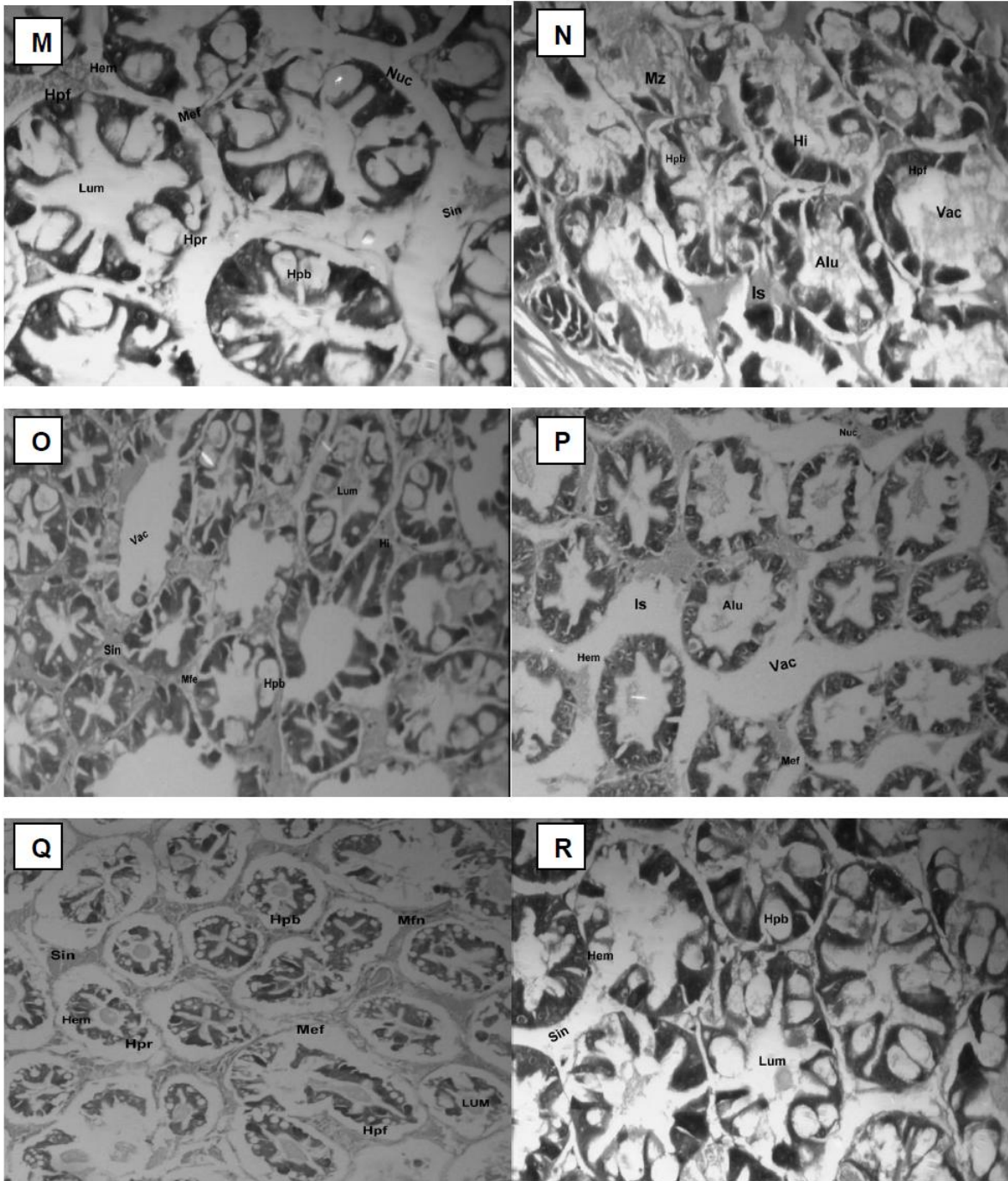


Table.1 Potassium (K⁺) concentration of inland saline ground water (ISGW) at different salinities before and after supplementation

Salinity (ppt)	K ⁺ concentration before fortification (ppm)		Quantity of Potassium chloride(KCl) added per litre (ppm) to get respective level of K ⁺				K ⁺ concentration after fortification (ppm)			
	RW	ASW	T1	T2	T3	T4	T1	T2	T3	T4
5	8.4	52.0	21.66	44.16	65.83	89.16	13	26	40	53
10	15.6	103.0	45.00	90.83	135.8	182.5	26	53	80	107
15	22.8	155.0	69.16	13.5	205.83	275	40	80	120	160

RW- Raw water (ISGW without potassium fortification); ASW- Artificial sea water; Treatments - T1- 25%, T2- 50%, T3- 75% and T4- 100% K⁺ of artificial sea water

Table.2 Effect of different treatments on growth of *Litopenaeus vannamei* during the experimental period of 60 days

Treatment groups	Salinity (ppt)								
	5	10	15	5	10	15	5	10	15
	Initial weight (g)			Final weight (g)			Weight gain (%)		
ASW	0.094±0.2 9	0.097±0.1 5	0.091±0.4 3	1.98±0.27 ^{eA}	2.03±0.12 ^{eB}	2.16±0.24 ^{eB}	1987.63±68.47 ^{de} A	1900.90±17.10 ^c B	2021.87±34.23 ^d B
RW	0.096±0.2 1	0.097±0.3 2	0.096±0.2 1	0.84±0.18 ^{aA}	1.38±0.12 ^{aB}	1.37±0.25 ^{aB}	435±11.86 ^{aA}	545.28±32.10 ^{aAB}	685.23±11.86 ^a B
T1	0.097±0.2 3	0.094±0.2 1	0.097±0.1 2	1.61±0.06 ^{bA}	1.19±0.15 ^{bB}	1.52±0.22 ^{bC}	984.65±15.35 ^{bA}	869.20±37.53 ^{bB}	953.40±22.58 ^{bC}
T2	0.094±0.4 4	0.097±0.3 7	0.097±0.2 1	1.75±0.17 ^{bc} A	1.69±0.17 ^{cB}	1.94±0.27 ^{bc} B	1696.70±29.62 ^{bc} A	1641.93±26.73 ^c B	1891.80±21.39 ^c B
T3	0.097±0.2 6	0.095±0.0 9	0.095±0.3 8	1.88±0.21 ^{dA}	1.75±0.12 ^{dB}	2.05±0.15 ^{dB}	1838.90±16.02 ^{cd} A	1703.57±29.23 ^c B	2018.43±32.65 ^d C
T4	0.095±0.2 6	0.092±0.1 2	0.097±0.2 3	2.16±0.35 ^{de} A	1.95±0.20 ^{de} B	2.12±0.14 ^{eB}	2124.50±90.54 ^e A	1911.00±29.77 ^d B	2089.30±35.21 ^d B

Superscripts in lower case letters indicate significant differences within the treatments for given salinity (p < 0.05)
Superscripts in upper case indicate significant differences within the treatments at different salinities (p < 0.05)

Low K^+ concentration in inland saline water is a primary factor for poor growth of pacific white shrimp (*L. vannamei*), (Saoud *et al.*, 2003; Rahman *et al.*, 2005; Prangnell and Fotedar, 2005). In the present study, increase in weight gain of experimental animals concurrent with increased fortification of ISGW with K^+ suggests that *L. vannamei* is able to grow in potassium-fortified ISGW. The fact that there was no significant difference between the weight of shrimps from the experimental group T4 raised in ISGW fortified with K^+ to a concentration of 100% of that in ASW indicates the usefulness of ISGW as an alternative culture medium when it is fortified with K^+ at 100% level of that in ASW. (Teruel *et al.*, 2003) observed that 100% K^+ fortified ISGW was sufficient to support the growth of *Penaeus monodon*. (Prangnell and Fotedar, 2005) observed that the growth of *L. vannamei* increased when ISGW was fortified with K^+ to a concentration between 60% and 100% of that in sea water.

Numerous studies have focused on the optimal salinity for the growth of *L. vannamei*. Shrimps at 17 ppt salinity had best growth performance, when compared with shrimps at either 3 ppt or 32 ppt salinity levels (Chen and Lin, 1998), suggesting that the optimal salinity for growth of the *L. vannamei* is around 17.0 ppt. (Huong *et al.*, 2010) reported that *L. vannamei* grew best at about 20 ppt and poorest at 5 and 45 ppt respectively. These results coincide with the present study indicating the maximum growth at 15 ppt salinity.

The exposure of aquatic organisms to even very low levels of chemicals, salinity or mineral concentration in their environment may result in various physiological, biochemical and histological changes in vital organs and/ or tissues (Hinton *et al.*, 1973; Mathur *et al.*, 1981; Gupta and Singh, 1982; Rao *et al.*, 1983; Virk and Kaur, 1987; Anbu

and Ramaswamy, 1991; Geraldine *et al.*, 1999). Similarly, histological alterations have been characterized in crustaceans such as *Palaemonetes pugio* and various species of *Macrobrachium* exposed to various chemicals such as copper, pentachlorophenol, dithiocarbamates, mercury, cadmium and zinc (Ghate and Mulherkar, 1979; Rao *et al.*, 1982; Doughtie and Rao, 1983; Rao and Doughtie, 1984; Victor *et al.*, 1990; Vijayaraman, 1993). Surprisingly, however, there is a paucity of information in relation to salinity and K^+ fortification induced histological alterations in hepatopancreatic tissues of the *L. vannamei*. The crustacean hepatopancreas, which is analogous to the liver of higher organisms, is a sensitive organ and liable to injury by pesticides and other water-born pollutants (Baticados *et al.*, 1987; Vogt, 1987; Baticados and Tendencia, 1991). The hepatopancreas is essentially composed of branched tubules and of different types of epithelial cells (E-cells, R-cells, F-cells and B-cells) lining the tubules. Therefore, it is likely that exposure to different salinity and K^+ fortification, would be reflected in alterations in the structure of the tubules and epithelial cells. Several such structural alterations were noted in the hepatopancreatic tubules of shrimps that had been exposed to salinities 5ppt, 10ppt and 15ppt and K^+ at 25%, 50%, 75% and 100% in the present study. To conclude, the lesions observed in the hepatopancreas of shrimp exposed to different salinities fortified with K^+ concentrations are likely to have been structural manifestations of disruptions in the absorptive, storage and secretory functions of the hepatopancreas. Since, rearing of shrimp to even low levels of salinity (5ppt) and higher K^+ (75% and 100%) can result in deleterious changes in hepatopancreas, whereas, in case of medium and higher salinity of 10ppt and 15ppt with 75% and 100% K^+ fortification yield better results and therefore it is suggested that, to utilize the

ISGW for the culture of *L. vannamei*, it must be fortified with K⁺ to a minimum of 75% to the level of sea water. The histological studies examining the effects of ISGW on *L. vannamei* needs to be investigated over a wider range of salinities and different ions (other than K⁺) to better determine how efficient it is at regulating various ions in comparison with other penaeid species.

References

- Al-Mohanna SY (1983) The hepatopancreas of *Penaeus sernisulcatus* DeHaan (Crustacea: Decapoda) during the digestive and moult cycle. PH. D. Thesis, University of Wales (not referred to in original).
- Anbu RB, and Ramaswamy M (1991) Adaptive changes in respiratory movements of an air breathing fish, *Channa striatus* (Bleeker) exposed to carbamate pesticide, Sevin. *J. Ecobiol.* 3, 11–16.
- Baticados MCL, and Tendencia EA (1991) Effect of gusathion A on the survival and shell quality of juvenile *Penaeus monodon*. *Aquacul.* 93, 9–19.
- Baticados MCL, Coloso RM, Duremdez RC (1987) Histopathology of the chronic soft syndrome in tiger prawn, *Penaeus monodon*. *Dis. Aquat. Org.* 3, 13–28.
- Bhavan PS, and Geraldine P (2000) Histopathology of the hepatopancreas and gills of the prawn *Macrobrachium malcolmsonii* exposed to endosulfan. *Aquat.Toxicol.* 50, 331–339.
- Boyd CE (2002) Inland Shrimp Farming. Book of Abstracts-*World Aquaculture*. 83 pp.
- Caceci T, Neck KF, Lewis DH, Sis RF (1988) Ultrastructure of the hepatopancreas of the Pacific white shrimp, *Penaeus vannamei* (Crustacea: Decapoda). *J. Mar. Biol. Assoc. U. K.* 68, 323–327.
- Chen JC, and Lin JN (1998) Osmotic concentration and tissue water of *Penaeus chinensis* juveniles reared at different salinity and temperature levels. *Aquaculture*, 164:173–181.
- Cuartas EI, Diaz AC, Petriella AM (2003) Modificaciones del hepatopáncreas dellangostino *Pleoticus muelleri* (Crustacea, Penaeoidea) porefecto de la salinidad. *Biociencias* (Brasil), 11, 53–59.
- Davis DA, Saoud IP, Boyd CE, Rouse DB (2005) Effects of potassium, magnesium, and age on growth and survival of *Litopenaeus vannamei* post-larvae reared in inland low salinity well waters in west Alabama. *J. World Aquac. Soc.* 36, 403–406.
- Doughtie DG, and Rao KR (1983) Ultrastructural and histological study of degenerative changes in the antennal glands hepatopancreas and midgut of grass shrimp exposed to two dithiocarbamate biocides. *J. Invert. Pathol.* 43, 89–108.
- Fielder DS, Bardsley WJ, Allan GL (2001) Survival and growth of Australian snapper, *Pagrus auratus*, in inland saline groundwater from inland New South Wales, Australia. *Aquaculture* 201, 73–90.
- Geraldine P, Bhavan PS, Kaliamurthy J, Zayapragassarazan Z (1999) Effects of dichlorvos intoxication in the freshwater prawn *Macrobrachium malcolmsonii*. *J. Environ. Biol.* 20, 141–148.
- Ghate HV, and Mulherkar L (1979) Histological changes in the gills of two freshwater prawn species exposed to copper sulphate. *Indian J. Exp. Biol.* 17, 838–840.
- Gong H, Jiang DH, Lightner DVCC, Brock D (2004) A dietary modification approach to improve the osmoregulatory capacity of *Litopenaeus vannamei* cultured in the

- Arizona desert. *Aquac.Nutr.* 10, 227–236.
- Gupta A, and Singh CP (1982) Histopathological changes in different tissues of *Trichogaster fasciatus* under the acute impact of BHC. *Toxicol.letter.* 14, 151–156.
- Hinton DE, Kemdall MW, Silver BB (1973) Biological Methods for the Assessment of Water Quality. ASTM STP 528. *American Society for Testing and Materials.* 194.
- Huong DTT, Jasmani S, Jaysankar V, Wilder M (2010) Na/K-ATPase activity and osmo-ionic regulation in adult white leg shrimp *Litopenaeus vannamei* exposed to low salinities. *Aquaculture*, 304:88–94.
- Jacobs W (1992) Untersuchungen über die Cytologieder Seretbildung in der mitteldarmdrüse von *Astacus leptodactylus*. 1928. In: Harrison, F. W. (Ed.), *Microscopic Anatomy of Invertebrates*, Volume 10. New York, Wiley-Liss,
- Li EC, Chen LQ, Zeng C, Chen XM, Yu N, Lai QM, Qin JG (2007) Growth, body composition, respiration and ambient ammonia nitrogen tolerance of the juvenile white shrimp, *Litopenaeus vannamei*, at different Salinities. *Aquaculture* 265, 385–390.
- Masson I (2001) Efecto del estrés osmótico sobre la Smorfología funcional del hepatopáncreas de *Artemesia longinaris* Bate (Crustacea, Decapoda). Tesis de Grado. Fac. Ciencias Exactas y Naturales, Univ. Nac. Mar del Plata, Argentina.
- Mathur DS, Agarwal MD, Rane PD (1981) Histopathological changes in liver and intestine of *Ranacyanoplyctis* induced by aldrin. *J. Environ. Biol.* 2, 105–107.
- Mcgraw WJ, and Scarpa J (2003) Minimum environmental potassium for survival of Pacific white shrimp *Litopenaeus vannamei* (Boone) in freshwater. *J. Shellfish Res.* 22, 263–267.
- McNevin AA, Boyd CE, Silapajarn O, Silapajarn K (2004) Ionic supplementation of pond waters for inland culture of marine shrimp. *J. World Aquac. Soc.* 35, 460–467.
- Nulsen B (1997) Inland saline waters in Australia. In: Smith, B., Barlow, C. (Eds.), *Inland Saline Aquaculture*. ACIAR Fisheries Department of Western Australia Fisheries Research and Development Corporation Rural Industries Research and Development Corporation, Perth, pp. 6 -11.
- Prangnell DI, and Fotedar R (2005) The effect of potassium concentration in inland saline water on the growth and survival of the western king shrimp, *Penaeus latisulcatus*, Kishinouye, 1896. *J. Appl. Aquac.* 17, 19–33.
- Rahman SU, Jain AK, Reddy AK, Kumar G, Raju KD (2005) Ionic manipulation of inland saline groundwater for enhancing survival and growth of *Penaeus monodon* (Fabricius) *Aquac. Res.* 36 (12):1149–1156.
- Rao KJ, Madhu C, Murthy VSR (1983) Histopathology of malathion on gills of a freshwater teleost, *Tilapia mossambica* (Peters). *J. Environ. Biol.* 4, 9–13.
- Rao KR, and Doughtie DG (1984) Histopathological changes in grass shrimp exposed to chromium, pentachlorophenyl and dithiocarbamates. *Mar. Environ. Res.* 14, 371–395.
- Rao KR, Doughtie DG, Conklin PJ (1982) Physiological and histopathological evaluation of dithiocarbamate toxicity to the grass shrimp, *Palaemonetes pugio*. In: Vernberg, W.B., Calabrese, A., Thurberg, F.P., Vernberg, F.J. (Eds.), *Physiological Mechanisms of Marine*

- Pollutant Toxicity. Academic Press, New York, pp. 413–445.
- Samocha TM, Hamper L, Emberson CR, Davis DA, McIntosh D, Lawrence AL, Van Wyk P (2002) Review of some recent developments in sustainable shrimp farming practices in Texas, Arizona, and Florida. *J. Appl. Aquac.* 12, 1–30.
- Samocha TM, Lawrence AL, Pooser D (1998) Growth and survival of juvenile *Penaeus vannamei* in low salinity water in a semi-closed recirculating system. *Isr. J. Aquac.* 50, 55–59.
- Saoud IP, Davis DA, Rouse DB (2003) Suitability studies of inland well waters for *Litopenaeus vannamei* culture. *Aquaculture*, 217:373-383.
- Teruel MNB, Eusebio PS, Welsh TP (2003) Utilization of feed pea, *Pisum sativum*, meal as a protein source in practical diets for juvenile tiger shrimp *Penaeus monodon*. *Aquaculture*, 225:121–131.
- Valenti WC, and Daniels WH (2000) Recirculation hatchery systems and management In: Freshwater prawn culture: The farming of *Macrobrachium rosenbergii* (ed. by M.B. New & W.C. Valenti), pp. 69-90. Blackwell Science, Oxford, UK.
- Victor B, Narayanan M, Nelson DJ (1990) Gills pathology and hemocyte response in mercury exposed *Macrobrachium* (Heller). *J. Environ. Biol.* 11, 61–65.
- Vijayaraman K (1993) Physiological responses on the freshwater prawn, *Macrobrachium malcolmsonii* (Milne Edwards) to the heavy metals, cadmium, copper, chromium and Zinc. Ph.D. Thesis. Bharathidasan University, Tiruchirappalli, India.
- Virk S, and Kaur KS (1987) Histopathological and biochemical changes induced by endrin and carbaryl in the stomach intestine and liver of *Mystus tengara*. *Indian J. Ecol.* 14, 14–20.
- Vogt G (1987) Monitoring of environmental pollutants such as pesticides in prawn aquaculture by histopathological diagnosis. *Aquaculture* 67, 157–164.
- Yang ZB, Zhao YL, Li N, Yang J (2007) Effect of waterborne copper on the microstructure of gill and hepatopancreas in *Eriocheirsinensis* and its induction of metallothionein synthesis. *Arch. Environ. Contam. Toxicol.* 52, 222–228.

How to cite this article:

Madhuri S. Pathak, Appidi K. Reddy, M.V. Kulkarni, V. Harikrishna, Prem P. Srivastava, N. K. Chadha and Wazir S. Lakra. 2018. Histological Alterations in the Hepatopancreas and Growth Performance of Pacific White Shrimp (*Litopenaeus vannamei*, Boone 1931) Reared in Potassium Fortified Inland Saline Ground Water. *Int.J.Curr.Microbiol.App.Sci.* 7(04): 3531-3542. doi: <https://doi.org/10.20546/ijcmas.2018.704.398>