

Original Research Article

<https://doi.org/10.20546/ijcmas.2018.702.249>

Effect of *Moringa oleifera* Leaf Extract on Histopathology of Heart Tissues on Silk Dye Waste Effluent Induced Swiss Albino Male Mice *Mus musculus*

Serina Khatun*

University Department of Zoology, T. M. Bhagalpur University, Bhagalpur-812007, India

*Corresponding author

ABSTRACT

Keywords

Moringa oleifera
Leaf powder, Silk
dye waste effluent,
Histopathology,
Heart tissue, Swiss
albino male mice
Mus musculus

Article Info

Accepted:

17 January 2018

Available Online:

10 February 2018

The present work was designed to investigate the toxic impacts of silk dye waste effluent induced on the histopathology of the heart tissue in the Swiss albino male mice *Mus musculus* and their mitigation using by *Moringa oleifera* leaf extract. Five sets of animals i.e. Group-I (Control), Group-II (fed with 50% silk dye), Group-III (fed with 100% silk dye), Group-IV (mice fed with 50% dye treated with *M. oleifera* leaves powder), Group-V (mice fed with 100% dye treated with *M. oleifera* leaves powder) have been taken for experiment. The dose of silk dye was 2ml/day to both groups-II and III and *M. oleifera* leaf is given as per the standard dose (300mg/kg b.w) to both animals of group IV and V. The result was demonstrated when treated with silk dye waste showed some changes including blood vessels degeneration, disrupted endocardium, myocardium, epicardium and collagenous fibers thickness but their mitigation using *Moringa oleifera* leaf powder. These results, along with previous observation, suggest that *M. oleifera* may be useful in cardiac tissues damage that is a result of silk dye waste effluent toxicity.

Introduction

Moringa oleifera leaf extract is from *Moringa oleifera* Lamark tree. It is considered one of the world's most useful trees, as almost every part of the tree can be used for food, or has some other beneficial medicinal properties. It is commonly known as 'drumstick' and is being used as antiulcer, diuretic, anti-inflammatory, anti-microbial, potent-antioxidant and wound healing agent (Caceres *et al.*, 1991; Udupa *et al.*, 1994; Kurma and Mishra, 1998; Saalu *et al.*, 2011 Bassey *et al.*, 2013), pharmacological properties (Oliveira *et al.*, 1999), it's an exceptional nutritious

vegetable (Ram,1994). Its leaves are used as nutritional supplement and growth promoter because of significant presence of protein, selenium, calcium, phosphorus, β -carotene and γ -tocopherol in it (Nambiar and Seshadri, 2001; Lakshminarayana *et al.*, 2005; Sanchez-Machado *et al.*, 2006).

The human are exposed to various type of environmental contaminants at different stage of their life span, widely held of them are harmful. Silk dye waste is one of the major sources of hazardous pollutants. Industrialization is a godsend of independent India but that is allied with hazardous

effluents and discharges polluting the environment. Silk industry as textile provides an important economic stand to the artisans but the dye waste or spent wash arising from the manufacturing unit cause great menace, if released in the open. Silk dye waste effluents are more toxic to environment than the domestic sewage. Bhagalpur (25°17'N latitude and 86°83'E longitude) is endowed with age old silk fabric and yarn production units. Here, the manufacturers use mostly synthetic dye such as azo dyes as colorant for their products. Azo dye forms the largest and most important silk industry provides an important economic group of synthetic dyes (Mathur *et al.*, 2005).

The heart is a major component of the body parts, which maintains blood flow in different part of body. The heart contain of four chambers through which the blood is pumped. The wall of the heart includes the cardiac muscle, a fibrous skeleton for attachment of the valves, and a specialized internal conducting system involved in the regulation of heart rate.

This study was therefore designed to investigation the effect of *Moringa oleifera* on silk dye waste effluent induced heart in male mice *Mus musculus*.

Materials and Methods

Animals

Experiment was performed on 6 to 8 weeks old healthy laboratory inbreed mice *Mus musculus* weighing about 30-35 grams. The animals were obtained from University Department of Zoology, Bhagalpur. Mice were reared and maintained at the animal house of University Dept. of Zoology, T.M. Bhagalpur University, and Bhagalpur under standard conditions and fed with nutritional diet and water.

Collection of plant material

Moringa oleifera leaf powder has been procured from own home product (with the help of ECHO Technical Note, By Beth Doerr and Lindsay Cameron, 2005, North Fort Myer, FL 33917, USA) Bhagalpur, Bihar, India.

Collection of silk dye waste

Silk dye waste effluents were collected directly from discharge point of silk dye industries of Nathnagar, Bhagalpur at regular interval.

Experimental design

The mice were divided into 5 groups of 8 animals each. Gr-I (control mice), Gr-II (mice treated with 50% silk dye waste), Gr-III (mice treated with 100% silk dye waste), Gr-IV (mice fed with 50% dye treated with *M. oleifera* leaves powder), Gr-V (mice fed with 100% dye treated with *M. oleifera* leaves powder).

Dosage

The control group was given normal food and water. Silk dye waste was administered orally 2ml/day (Chaurasia *et al.*, 2005) group II and III for 30 and 60 days duration. *M. oleifera* leaf powder was also fed orally 300mg/kg b.w to both the group IV and V for 30 and 60 days exposure as per the method suggested by Chatterjee *et al.*, 2013.

Biological assays

Histopathological study of heart tissue.

Tissue processing and staining

After 30 and 60 days of experiment, mice were sacrificed and their organs were

removed, were fixed in fixative and paraffinised, Haematoxylin-Eosin stained section of heart tissue were observed under light microscope (Pears, 1985) on 40X magnification.

Results and Discussion

Histopathological observation on heart tissue

Histopathological study on the heart tissue of control (Group-I) mice showed normal layer of epicardium, myocardium, endocardium and connective tissues in blood vessels (Fig. 1). In case of Group-II treated with 50% silk dye waste at 30 days show that the decrease of myocardium thickness, disrupted connective tissue of cardiac muscle (Fig. 2). Group-IV treated with *Moringa oleifera* leaves powder at 30 days showed improvement in myocardium layer and connective tissue of cardiac muscle (Fig. 3). Group-III treated with 100% silk dye waste at 30 days showed the disrupted of epicardium and myocardium

layer and also seen degenerated of connective tissue in blood vessels (Fig. 4). Group-V treated with *M. oleifera* leaf extract at 30 days showed connective tissue in blood vessels regeneration, also seen mitigation the layer of endocardium and myocardium (Fig. 5). In case of Group-II treated with 50% silk dye waste at 60 days showed endothelial cells and collagenous fibers were disrupted (Fig. 6). Group-IV treated with *Moringa oleifera* leaf extract at 60 days showed; more or less repair the endothelial cell and collagenous fibers of endocardium (Fig. 7). In case of Group-IV treated with 100% silk dye waste at 60 days showed disrupted epicardium and myocardium layer, also seen damage of subendocardial layer and thickness of collagenous fibers (Fig. 8). In case of Group-V treated with *M. oleifera* leaf extract at 60 days showed the repair mechanism in epicardium and myocardium but not completely look like of normal tissue architecture, mitigation also seen in subendocardial layer and thickness of collagenous fibers (Fig. 9).

Figure.1 Photomicrograph of heart tissue section of mice showed, normal histoarchitecture (x40, H&E)

Control Mice (Fig. 1)

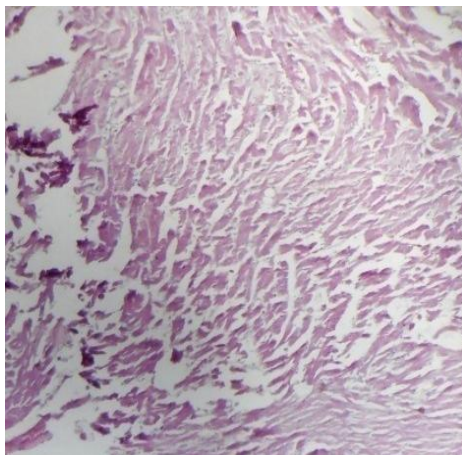


Fig.2 Photomicrograph of heart tissue section of mice showed, disrupted myocardium layer and connective tissue (x40, H&E). **Fig.3** Photomicrograph of heart section of mice showed, regeneration of myocardium and connective tissue (x40, H&E). **Fig.4** Photomicrograph of heart section of mice showed degenerated connective tissue and disrupted endocardium (x40, H&E). **Fig.5** Photomicrograph of heart section of mice showed, mitigation of endocardium and myocardium (x40, H&E)

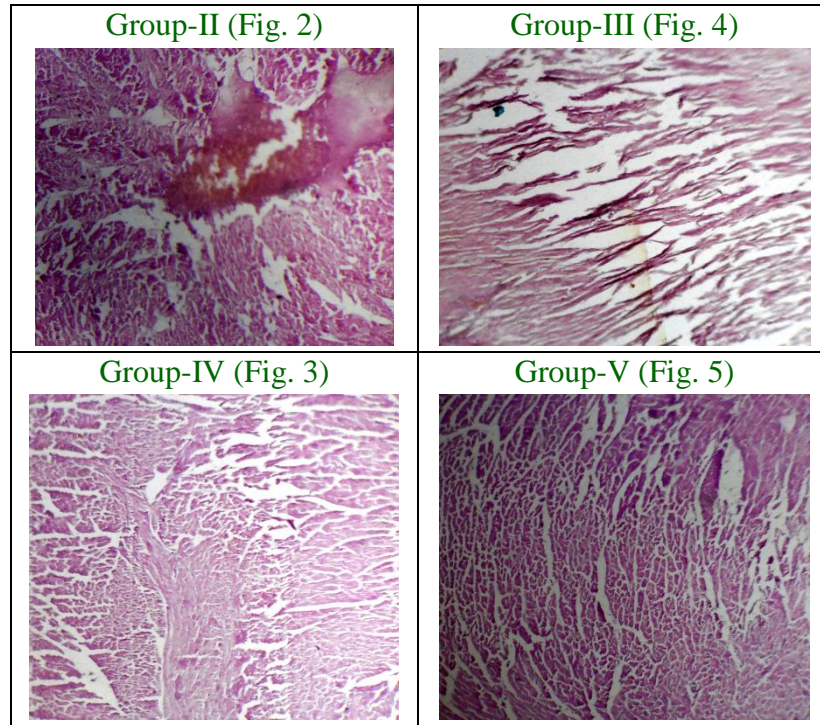
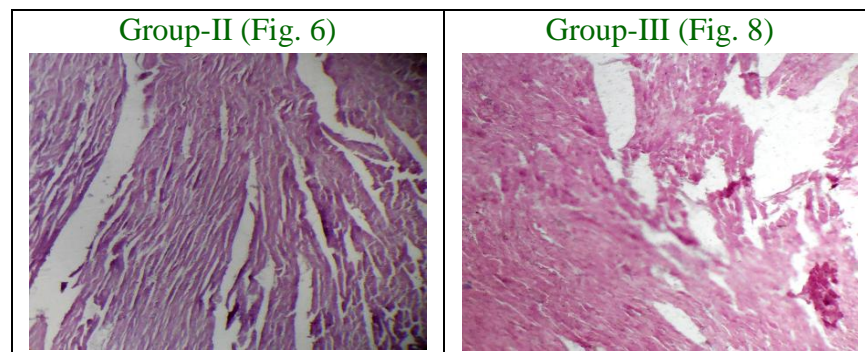
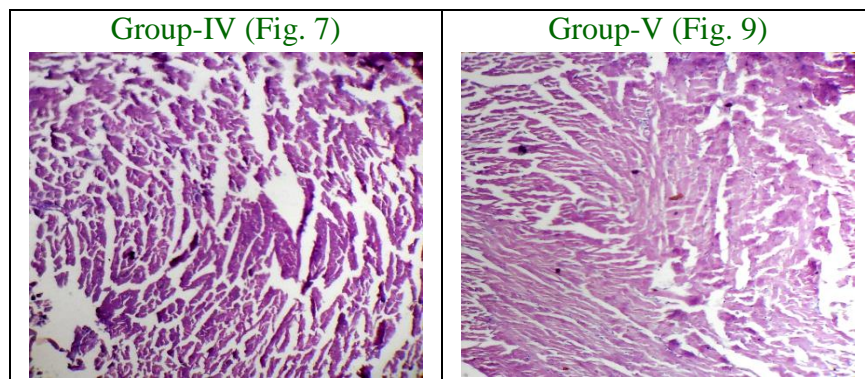


Fig.6 Photomicrograph of heart section of mice showed, endothelial cells and collagenous fibers also disrupted (x40, H&E). **Fig.7** Photomicrograph of heart section of mice showed, repair the endothelial cell and collagenous fibers of endocardium (x40, H&E). **Fig.8** Photomicrograph of heart section showed, disrupted of myocardium and epicardium, and damaged collagenous fibers thickness (x40, H&E). **Fig.9** Photomicrograph of heart tissue section of mice showed, more or less normal architecture of heart tissue, mitigation in subendocardial layer and thickness of collagenous fibers (x40, H&E)





In the present experimental study were investigated, the histopathological effects of silk dye waste effluent on mice heart tissue and their significant mitigation using *Moringa oleifera* leaf extract. Some scientist provides that the triggering mechanism of macrophage accumulation is the result of cardiac afadin deficiency that increased the expression of the macrophage attracting cytokine MCP-1 (Kuwahara *et al.*, 2004 and Sawaya *et al.*, 2009). Ligation of the left anterior descending coronary artery in mice induces a large myocardial infarction that comprises 50% to 60% of the left ventricle (Jacob *et al.*, 2012 and Gordts *et al.*, 2013). The occurrence of ventricular rupture in the first 2 weeks after myocardial infarction in mice in frequent (Dart *et al.*, 2005 and Muthuramu *et al.*, 2013). Kiriazis *et al* in 2005 reported that the complication of myocardial infarction is strain dependent and occur significantly more often in male mice than in female. Serina, K in 2017 reported that toxicity of silk dye wastes on lung of Swiss albino male mice *Mus musculus* and its mitigation by using *Moringa oleifera* leaf extract. The thinking of disproportionate and dilation of the infarct segment not only induces myocardial rupture but is also a trigger for cardiac remodeling and for congestive heart failure (Eaton *et al.*, 1979; Erlebacher *et al.*, 1982; Bulkley *et al.*, 1979 and Jugdutt *et al.*, 1987). Excessive amount of collagen fibers in cardiac interstitial space impede coronary vasodilation, oxygen diffusion and

electromechanical coordination between cardiomyocytes, causing contractile abnormalities (Rohr *et al.*, 2009). Kasner *et al.*, in 2011 and Lopez *et al.*, in 2012, reported that the increase of collagen and its cross linking stiffen the left ventricle, impairing ventricular relaxation and filling. Toxicity impact of Silk dye waste effluent induced Histopathological changes in the Stomach and Intestine of Swiss albino mice *Mus musculus* and their mitigation using *Moringa oleifera* leaf powder (Khatun, 2017). Toxicity of silk dye waste on Swiss albino male mice of different histopathological section as stomach and intestine, lung, testis, liver and mitigation using *M. oleifera* leaf extract (Serina *et al.*, 2017).

On the basis of above discussion histopathological observations and facts it can be concluded that the *M. oleifera* leaf powder significantly reduce the alteration arisen in damage of heart tissue section and associated structures in the toxicity impact of silk dyes waste effluent induced mice *Mus musculus*.

References

- Rohr, S (2009): Myofibroblasts in diseased heart: new players in cardiac arrhythmias? *Heart Rhythm* 6, 848-856.
- Kasner, M (2011): Diastolic tissue Doppler indexes correlate with the degree of collagen expression and cross-linking in heart failure and normal ejection

- fraction. *J. Am. Coll. Cardiol.* 57, 977-985.
- Lopez, B., Querejeta, R., Gonzalez, A., Larman, M. and Diez, J (2012): Collagen cross-linking but not collagen amount associates with elevated filling pressures in hypertensive patients with stage C heart failure: potential role of lysyl oxidase. *Hypertension* 60, 677-683.
- Kuwahara, F (2004): Hypertensive myocardial fibrosis and diastolic dysfunction: another model of inflammation. *Hypertension* 43, 739-745.
- Deshmane, S. I., Kremlev, S., Amini, S and Sawaya, B. E (2009): Monocyte chemoattractant protein-1: an overview. *J. Interferon Cytokine Res*, 29, 313-326.
- Van Creayveld, E; Jacobs, F; Godts, S.C & De Geest, B (2012): Low-density lipoprotein receptor gene transfer in hypercholesterolemic mice improves cardiac function after myocardial infarction. *Gene Ther.* 19, 860-871.
- Godts, S.C (2013): Beneficial effects of selective HDL-raising gene transfer on survival, cardiac function after myocardial infarction in mice. *Gene Ther.* 20, 1053-1061.
- Khatun, S (2017): Toxicity impact of Silk dye waste effluent induced Histo pathological changes in the Stomach and Intestine of Swiss albino mice *Mus musculus* and their mitigation using *Moringa oleifera* leaf powder. *Journal of Medical Science and Clinical Research*, 5(3), pp-19306-19313.
- Serina, K (2017): Toxicity of silk dye waste on lung of Swiss albino male mice *Mus musculus* and its mitigation by using *Moringa oleifera* leaf extract. *International Journal of Current Advanced Research*, 6(1): pp-2657-2660.
- Caceres, A; Cabrera, O; Morales, O; Mollinedo, P. and Mendia, P (1991): Pharmacological properties of *M. oleifera*. 1: preliminary screening for antimicrobial activity. *Journal of Ethnopharmacology*, 33(3):213-216.
- Jahn, S.A.A. (1988): Using *Moringa oleifera* seeds as coagulant in developing countries. *J Amer Water Works Assoc*, 6:43-50.
- Khatun, S. and Varma, M.C. (2017): Toxicity impact of silk dye waste effluent on reproductive system of Swiss albino male mice *Mus musculus* and mitigation of *M. oleifera* leaf extract. *World J. Pharmacy and Pharmaceutic Sciences*, 6(1):1621-1629.
- Khatun, S. and Varma, M.C. (2017): Role of *Moringa oleifera* leaf extract on silk dye waste effluent induced histopathotoxicity on liver and testis of Swiss albino male mice *Mus musculus*. *IOSR Journal of Pharmacy*, 7(4): 1-7.
- Kumar, N.A and Pari, L (2003): Antioxidant Action of *Moringa oleifera* Lam. against peroxidation in rats. *J Med Food*, 6(3):255-259.
- Lakshminarayana, R; Raju, M; Krishnakantha, T.P and Baskaran, V. (2005): Determination of major carotenoids in a few Indian leafy vegetables by high-performance liquid chromatography. *Journal of Agricultural and Food Chemistry*, 53(8):2838-2842.
- Mathur, N; Mehta, M; Chaudhry, V (2005): Sperm abnormality Induction by Food colour metanil yellow. *J. Ecolphysiol. Occup. Hlth*; 5:157-160.
- Meyer, U. (1981): Biodegradation of synthetic organic colorants. *FEMS Symp*, 12:371-385.
- Mishra, R. K; Singh, S.K (2007): effect of aqueous leaf extract of *A. indica* on the reproductive organs in male mice. *Ind. Jol. Of Exptl. Biol.* 43:1093-1103.
- Nambiar, V.S and Seshadri, S (2001):

Bioavailability trials of β -carotene from fresh and dehydrated drumstick leaves (*M. oleifera*) in a rat model. *Plant Food for Human Nutrition*, 56(1):83-95.

Sanchez-Machado DL, Lopez-Cervantes J, Vazquez NJ, 2006. High-performance liquid chromatography method to measure α and γ -tocopherol in leaves flowers and fresh beans from *M. oleifera*. *Journal of Chromatography A*, 1105(1-2):111-114.

Serina, K. and Varma, M. C. (2016): Effect of

M. oleifera leaf extract on silk dye effluent affected haematological and biochemical parameter on Swiss albino male mice. *Amer. Inter. J. Form, Appli and Natu. Sci*, 14(1), pp.50-55.

Udupa, S.L; Udupa. A.L and Kulkarni, D.R. (1994): Study on the anti-inflammatory and healing properties of *M. oleifera* and marmelos. *Fitoterapia*, 65(2):119-123.

How to cite this article:

Serina Khatun. 2018. Effect of *Moringa oleifera* Leaf Extract on Histopathology of Heart Tissues on Silk Dye Waste Effluent Induced Swiss Albino Male Mice *Mus musculus*. *Int.J.Curr.Microbiol.App.Sci*. 7(02): 2094-2100. doi: <https://doi.org/10.20546/ijcmas.2018.702.249>