

Case Study

<https://doi.org/10.20546/ijcmas.2018.702.277>

***Serratia marcescens* as a Pathogen in a Case of Diabetic Foot: A Case Report**

**K. Sharanya \*, K. Lakshmi and S. Chitralkha**

Department of Microbiology, Sree Balaji Medical College and Hospital (Bharath University),  
Chennai, Tamil Nadu, India

*\*Corresponding author*

**A B S T R A C T**

**Keywords**

*Serratia marcescens*,  
Diabetes mellitus,  
Soft tissue infection

**Article Info**

**Accepted:**  
20 January 2018  
**Available Online:**  
10 February 2018

*Serratia marcescens* causing a soft tissue infection is very rare. But, among the immunocompromised patients it is becoming an important pathogen causing infection. Here we report a case of an elderly male with type 2 diabetes mellitus presenting with severe soft tissue infection due to *S. marcescens*. The diagnosis and antibiotic susceptibility pattern are discussed.

**Introduction**

A 61 year old male with history of Type 2 diabetes mellitus for the past 6 years with irregular treatment was admitted with a one-week history of worsening lower right limb pain, ulcer with discharge of pus, erythema and reduced mobility. The patient was initially stable on admission but rapidly deteriorated. He was febrile at 38°C and blood pressure dropped to 100/50 mmHg. He was tachycardic and tachypnoeic. His right foot was ulcerated, warm and tender with significant swelling in the right leg.

Blood examination results revealed Serum urea 25mg/dl, Serum creatinine 0.9 mg/dl,

total white cell count of 12300 cells/cumm, platelet count of 3.56 lakhs/cumm, C-reactive protein 192 mg/L, ESR of 100mm. Blood glucose Fasting showed 230mg/dl and post prandial showed 316 mg/dl with HBA1C of 8.32%. Wound debridement was done. Pus was collected and sent to Microbiology laboratory for culture and sensitivity. Patient was started on broad spectrum antibiotics.

Direct Gram stain from the pus showed occasional pus cells and occasional Gram-negative coccobacilli. The pus was inoculated into Nutrient agar, 5% sheep Blood agar, Chocolate agar, Mac-Conkey agar and Thioglycolate broth, After 12 hours of incubation, Nutrient agar showed large red

moist colonies (Fig. 1), 5% sheep Blood agar (Fig. 3) and Chocolate agar showed growth of red, opaque moist colonies. Meanwhile Mac-Conkey agar grew Red late lactose fermenting colonies (Fig. 2). Gram staining from colonies was confirmed as Gram-negative coccobacilli. The Gram-negative bacteria was identified as *Serratia marcescens* by standard microbiological methods as well as using Vitek 2 Compact along with antibiotic susceptibility pattern.

The organism was found to be susceptible to Cotrimoxazole, Piperacillin+tazobactam, Gentamycin, Tobramycin, Imipenem, Meropenem, Ceftriaxone, Tetracycline, Aztreonam, Chloramphenicol and Resistant to Ciprofloxacin, Cefixime, Ampicillin, Amoxicillin+clavulanate and Cefazolin.

The patient was continued with IV Antibiotics based on the sensitivity report and blood sugars were closely monitored. Inflammatory markers like CRP & ESR were also monitored regularly. The patient's general condition improved and was shifted to oral antibiotics. Patient was discharged later as his CRP returned to normal.

## Results and Discussion

*Serratia marcescens* is an emerging opportunistic pathogen which has gained global importance in the recent years. It is commonly recognized as hospital acquired infection. However, it has also been reported that 47% of *Serratia bacteremias* could be community acquired (Rehman *et al.*, 2012).

*S. marcescens* is a gram negative bacteria belonging to the genus *Serratia*, member of Enterobacteriaceae family. The characteristic feature of this bacterium is its distinctive pigmentation, which was used as a biological marker in the olden days (Gaughran, 1969).

*Serratia* usually inhabits respiratory and urinary tracts where it may cause opportunistic infections. But the organism has also been implicated in various other infections like osteomyelitis, endocarditis, cellulitis, necrotizing fasciitis, blood stream infections, wound infections, etc (Herra and Falkiner, 2015; Anía, 2015).

Colonisation and infection may be aggravated by hospitalisations, increased usage of antibiotics, etc. In the recent years, *Serratia* has been increasingly reported as opportunistic pathogen. Various predisposing factors for *Serratia* bacteremia include surgery, antibiotic usage, steroids, diabetes (Crowder *et al.*, 1971).

*Serratia* is ubiquitous, found in sewage, soil and water. Predisposing factors for *Serratia* soft tissue injuries could be skin ulcers, biopsy, vascular injuries compromising the skin integrity, prior surgery, etc (Crowder *et al.*, 1971; Bennett *et al.*, 1995).

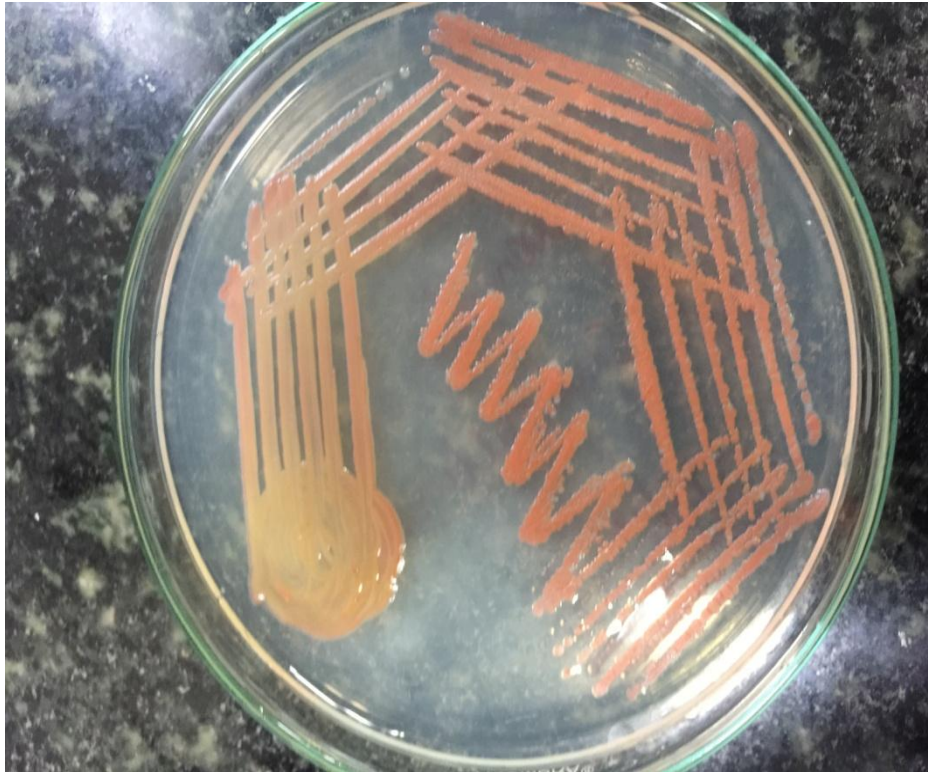
In our case, patient has developed cellulitis in his leg.

The risk factors included recent hospitalization, antibiotic usage, and immunocompromised state due to diabetes. Huang *et al.*, reported *Serratia marcescens* causing necrotizing fasciitis in patients on steroid therapy (Huang *et al.*, 1999).

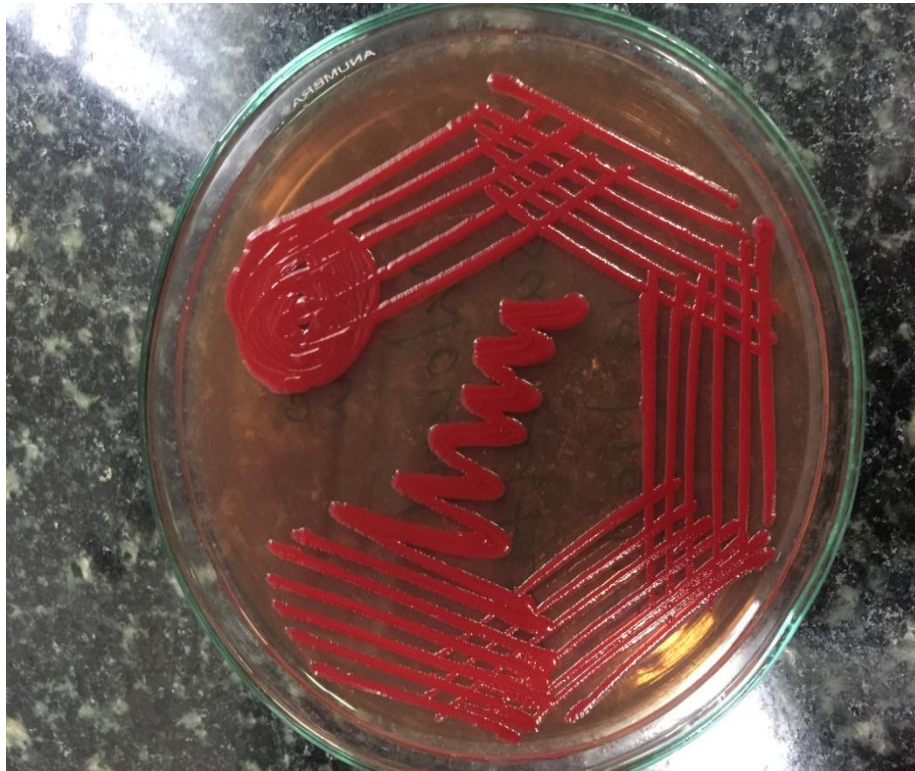
Brenner *et al.*, reported *Serratia* cellulitis due to infected intravenous catheter in a patient with bacteremia (Brenner DE and Lookingbill DP, 1977).

Literature reveals that *Serratia* often produce bullae in patients with soft tissue infections similar to beta hemolytic streptococci and *Staphylococcus aureus* (Huang, 1999; Bornstein, 1992; Zipper, 1996; Cooper, 1998).

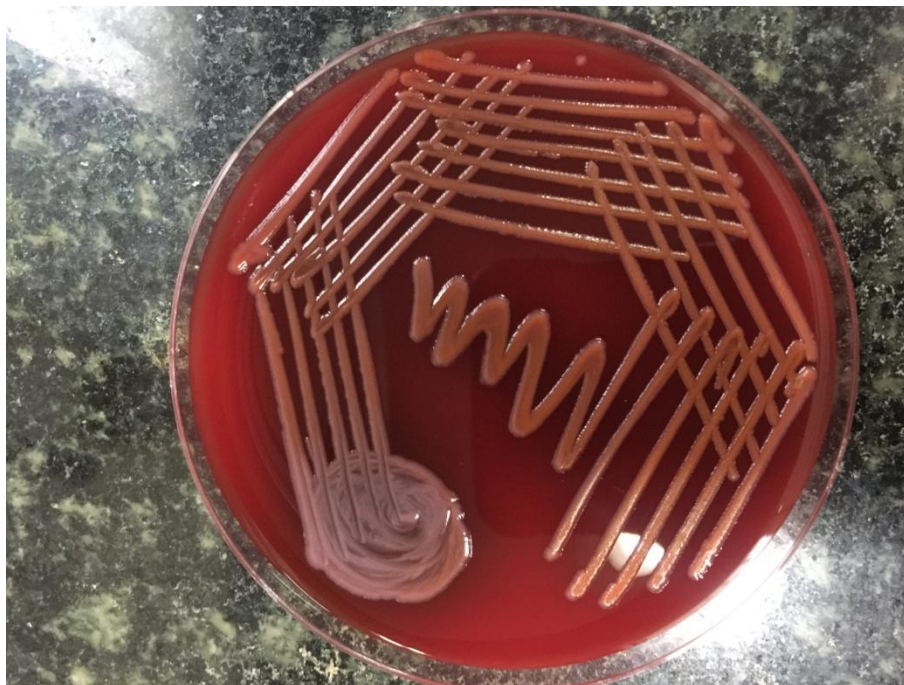
**Fig.1** Nutrient agar showing large red moist colonies



**Fig.2** Mac-Conkey agar showing Red late lactose fermenting colonies



**Fig.3** Blood agar showing Red, opaque moist colonies



*Serratia* has been reported rarely from soft tissue infections. In few of the reported cases, diabetes has been found to be the underlying precipitating factor (Zipper, 1996; Kaplan, 1988). Since there are no specific clinical signs and symptoms, the clinicians should be more suspicious to diagnose *Serratia* in patients with underlying risk factors like diabetes, immunosuppression, etc.

Conventionally, *Serratia* was diagnosed using Analytical Profile Index (API) 20E (bio-Merieux) phenotypic microbial identification system (Hejazi and Falkiner, 1997). With the widespread usage of automated systems, the laboratory diagnosis of *Serratia* is commonly done with Vitek 2 (bio-Merieux), BD Phoenix (BD Diagnostics, Sparks), etc (Menozzi *et al.*, 2006). Species level identification of *Serratia* isolates can be done by MALDI-TOF MS (matrix-assisted laser desorption/ionization time-of-flight mass spectrometry) which is an automated identification system. The common empirical drug regimen for soft tissue infections is flucloxacillin and

benzylpenicillin. However, in cases with suspicion of *Serratia*, antibiotics with gram negative coverage should also be included. *Serratia* is commonly resistant to macrolides, ampicillin and first generation cephalosporins (Anía, 2015). Increasing resistance has been reported to gentamicin (Herra and Falkiner, 2015). In our case, the organism has been found to be resistant to cefazolin, but susceptible to gentamicin.

Third generation cephalosporins may be used along with aminoglycosides in treating the cases of *Serratia*. In this case, the organism was found to be susceptible to ceftriaxone as well as carbapenem group of drugs. Few ESBL strains of *Serratia* has been reported to be resistant to third generation cephalosporins (Anía *et al.*, 2015). In such cases, fourth generation cephalosporins or piperacillin tazobactam antibiotics may be tried. Carbapenem group of drugs have also been shown to be effective in resistant cases. However, in carbapenemase producing strains this drug may be ineffective.

In conclusion, in immunocompromised patients, the cellulitis should be diagnosed and treated with high index of suspicion. Rare pathogens like *Serratia* require prompt identification and proper management. Further, multidrug resistant strains are becoming common with *Serratia* infection. Hence, the definitive treatment should be initiated based on antibiotic susceptibility testing. Since the mortality rates are high with *Serratia* soft tissue infections, early debridement and appropriate antibiotic therapy is the treatment of choice.

## References

- Anía BJ. *Serratia* medication. Cited 8 June 2015. Available at: <http://emedicine.medscape.com/article/28495-medication#1>.
- Bennett SN, McNeil MM, Bland LA, *et al.*, Postoperative infections traced to contamination of an intravenous anesthetic, propofol. *N Engl J Med* 1995; 333:147–154.
- Bornstein PF, Ditto AM, Noskin GA. *Serratia marcescens* cellulitis in a patient on hemodialysis. *Am J Nephrol* 1992; 12:374–376.
- Brenner DE, Lookingbill DP. *Serratia marcescens* cellulitis. *Arch Dermatol* 1977; 113:1599–1600.
- Cooper CL, Wiseman M, Brunham R. Bullous cellulitis caused by *Serratia marcescens*. *Int J Infect Dis* 1998; 3:36–38.
- Crowder JG, Gilkey GH, White AC. *Serratia marcescens* bacteremia. *Arch Intern Med* 1971; 128:247–253.
- Gaughran ER. From superstition to science: the history of a bacterium. *Trans NY Acad Sci.*, 1969; 31: 3-24.
- Hejazi A, Falkiner FR. *Serratia marcescens*. *J. Med. Microbiol.*, 1997; 46: 903-912
- Herra C, Falkiner FR. *Serratia marcescens*. Cited 8 June 2015. Available at: <http://www.antimicrobe.org/b26.asp>.
- Huang JW, Fang CT, Hung KY, *et al.*, Necrotizing fasciitis caused by *Serratia marcescens* in two patients receiving corticosteroid therapy. *J Formos Med Assoc* 1999; 98: 851–854
- Kaplan H, Sehtman L, Ricover N, Slatkis D, Lacentre E. *Serratia marcescens*: cutaneous involvement. Preliminary report. *Med CutanIberoLat Am* 1988; 16:305-08.
- Menozzi MG, Eigner U, Covan S, Rossi S, Somenzi P, Dettori G, Chezzi C, Fahr AM. Two-center collaborative evaluation of performance of the BD phoenix automated microbiology system for identification and antimicrobial susceptibility testing of gram-negative bacteria. *J Clin Microbiol* 2006; 44: 4085-4094.
- Rehman T, Moore TA, Seoane L. *Serratia marcescens* necrotizing fasciitis presenting as bilateral breast necrosis. *J Clin Microbiol* 2012; 50:3406-08. <http://dx.doi.org/10.1128/JCM.00843-12>
- Zipper RP, Bustamante MA, Khatib R. *Serratia marcescens*: a single pathogen in necrotizing fasciitis. *Clin Infect Dis* 1996; 23:648–649.

### How to cite this article:

Sharanya, K., K. Lakshmi and Chitralkha, S. 2018. *Serratia marcescens* as a Pathogen in a Case of Diabetic Foot: A Case Report. *Int.J.Curr.Microbiol.App.Sci.* 7(02): 2293-2297. doi: <https://doi.org/10.20546/ijcmas.2018.702.277>