

Original Research Article

<https://doi.org/10.20546/ijcmas.2018.702.033>

Cross Sectional Study Comparing Peripheral Blood Smear and Rapid Antigen Detection Test in Diagnosis of Malaria Conducted During Monsoon and Post Monsoon Period at Ballari, India

B. Vishalakshi*, J. Mariraj, S. Liba and S. Krishna

¹Department of Microbiology, Vijayanagar Institute of Medical Sciences, Ballari, Karnataka, India

*Corresponding author

ABSTRACT

Malaria is major public health issue and Ballari is an endemic area. Peripheral blood smear examination (PBS) is done routinely. However, PBS during febrile period is essential for demonstration of parasite. In most cases, sample collection during afebrile period or at inappropriate timings results in smear negative reports. Hence, rapid antigen detection tests would be ideal or can be a supportive test to early diagnosis of malaria. To compare PBS examination with rapid antigen detection tests (RDT) and estimate prevalence of malaria. Patients with PUO attending VIMS, June-October 2016 were included in cross sectional study. 1 ml venous blood collected into EDTA bulbs and subjected to antigen detection using commercially available kits (SD Bioline) and then PBS was prepared and stained using Leishman stain. Among the 2979 samples, 1616 (54.24%) and 1363 (45.75%) were tested during Monsoon and post-monsoon period respectively. Among the 1616 samples, 12 (0.74%) were positive, of which 12 (100%) were tested positive by RDT, while 3(25%) samples were positive by PBS, while all 1363 samples were negative. The age group affected was 20-40 years (75%) with sex ratio of 3:1 (M: F) showing male preponderances (75%). Geographic prevalence showed high positive trend in urban Ballari (50%). The sensitivity (75%) and specificity (100%) was with RDT compared with PBS. Study revealed declining trend of malaria in 2016. Rapid antigen detection kits are more specific and sensitive in detection of the malarial parasites especially in endemic areas even with low parasitaemia.

Keywords

Peripheral blood smear, Rapid antigen, Detection test

Article Info

Accepted:
04 January 2018
Available Online:
10 February 2018

Introduction

Malaria is the parasitic disease caused by an obligate intracellular protozoan belonging to genus *Plasmodium*. Malaria is the 5th most common cause of death due to infectious disease worldwide. World Malaria Report

2015, estimated 214 million cases of malaria globally and 4.38 lakh malaria deaths, representing a decrease in malaria cases and deaths of 37% and 60% since 2000, respectively. The early symptoms of Malaria are very non-specific and variable (World Malaria Report, 2015). According to WHO,

malaria is endemic in 108 countries including India. Karnataka being a vast semi-urban state with rich irrigated lands and good monsoon has promoted growth of mosquitoes and disease transmission. Malaria is very common during monsoon and post-monsoon period (Anirudh R. Acharya, 2013).

Parasite based diagnosis is increasing, most suspected cases of malaria are still not properly identified, but the treatment has to be started immediately in order to avoid complications. This has resulted in poor disease diagnosis and overuse of anti-malarial drugs (Deepika Verma *et al.*, 2014). The commonly employed method for diagnosis of malaria involves the microscopic examination of Leishman stained blood films (Anirudh R. Acharya, 2013). An expert microscopist can detect 20-40 parasites/ μ l on standard blood films. Although a thick peripheral blood smear (PBS) allows identification of the plasmodial parasite and stages, the technique is laborious, time consuming and requires a well-trained microscopist for accurate identification (Bruce-Chwatt, 1984; Pinto *et al.*, 2001; Manjunatha *et al.*, 2011).

Since 2010 WHO has recommended that all persons with suspected malaria in all settings should undergo malaria diagnostic testing by either microscopy or Rapid diagnostic tests (RDT) (Yasmeen Khatib *et al.*, 2016; World Health Organization, 2011). Peripheral blood smear examination (PBS) is done routinely. However, PBS during febrile period is essential for demonstration of parasite.

In most cases, sample collection during afebrile period or at inappropriate timings results in smear negative reports. PBS has limitation like it detects only when 40-60 parasites/ μ l of blood are present. Hence, antigen detection tests or others would be ideal for early diagnosis or to confirm malaria (Pinto *et al.*, 2001).

In recent years, numerous quick and new techniques for malaria diagnosis have been developed, one such being the rapid diagnostic test. The antigen detected is histidine rich protien-2 (HRP-2) and enzymes detected are plasmodium lactate dehydrogenase (pLDH) and pan-specific aldolase. All these techniques vary in their sensitivity, specificity, positive and negative predictive values. The objective of the study was to estimate the prevalence of malaria and compare Leishman stained thick and thin PBS with that of Rapid diagnostic test in the diagnosis of malaria.

Materials and Methods

This Cross sectional study was conducted in the Department of Microbiology, VIMS Ballari during monsoon and post monsoon period during June 2016 to October 2016. The study group comprised of patients with pyrexia of Unknown origin (PUO) referred from outpatient/inpatient departments to the Microbiology laboratory for the diagnosis of malaria. The study included patients of either gender age varied between 1-80 years. And patients diagnosed with dengue fever, rickettsial fever were excluded.

Sample collection

1 ml venous blood collected into EDTA bulbs and subjected to antigen detection using commercially available kits (SD Bioline) and then PBS was prepared and stained using Leishman stain.

Thick and thin blood smears

Thick and thin blood smears were prepared as per the standard method. The smears were stained with Leishman's stain. Approximately 80-100 fields were examined over 8-10 minutes by an experienced microscopist. (Manjunatha *et al.*, 2011) Negatives should not be reported until 200 oil immersion fields

have been examined and Additional specimens should be examined at 12-hour intervals for a subsequent 36 hours.

Antigen detection using

HRP II Ag of Pf and pLDH of Pv: Commercially available antigen detection kit (SD Bioline) was used. The test was done using EDTA anticoagulated blood as per standard operating procedure (SOP) given by manufactures. Interpretation of the test result was done as below:

When only one pink- purple band appears in the control window marked as “C” the test - Considered to be negative.

When one control band and another one bands appear only at region of “P.f” the test considered to be positive for *P. falciparum*.

When one control band and one pink purple band appear only at region “P.v” the test considered to be positive for *P. vivax*.

When one control band and another two bands appear at regions “P.f” and “P.v” the test considered to be mixed infection of P.f and P.v.

When no control band appears on device the test should be considered invalid.

Statistical Analysis

The data is expressed in descriptive statistics as frequency and percentage.

Results and Discussion

2979 samples were screened for malaria parasite by thick and thin Leishman stained peripheral blood smear method and RDT antigen detection test. The study flow chart is depicted in Figure 1. The Month wise Trend of sample outflow during Monsoon & Post-

Monsoon Periods is shown in table 1. During monsoon period 1616 (54.24%) samples were tested whereas in the post monsoon 1363 (45.75%) samples were tested. The Age-wise distribution of positive cases is shown in table 2. The age group commonly affected was 20-40 years (75%) with gender ratio of 3:1(M: F) showing male preponderances (75%). The gender-wise distribution of positive cases is shown in Table 3. Geographic prevalence estimated Ballari distict (urban) was 0.74%.

Malarial parasite was detected in 12 (0.74%) cases during the monsoon period. Out of a total of 12 positive cases, while 3(25%) samples were positive by peripheral smear and 12(100) were detected positive by RDT. In the Post monsoon period none of the patients have shown positivity either by slide method or Rapid diagnostic methods.

Rapid detection and early treatment are pre requisite in the management of malaria. Peripheral blood smear method is simple, least expensive, labor intensive, time consuming and therefore delay the diagnosis. PBS smears are considered to be the 'gold standard' in diagnosis. However, the accurate species differentiation and quantification of parasitemia is possible only when performed by skilled microscopist. (Jafar Ebrahim *et al.*, 2013) Apart from clinical and microscopic examination, many rapid diagnostic tests have been developed which are rapid, simple and easy to interpret. Most frequently, they deploy a dipstick or antigen card tests.

Prompt and accurate diagnosis of malaria is a key to effective management because it helps in early start of appropriate antimalarial drug to prevent complications In view of this, new rapid diagnostic techniques have been developed and evaluated in recent years. In the present study, the prevalence of malaria in Ballari was assessed using simple microscopic and rapid diagnostic methods.

Fig.1 Study flow chart

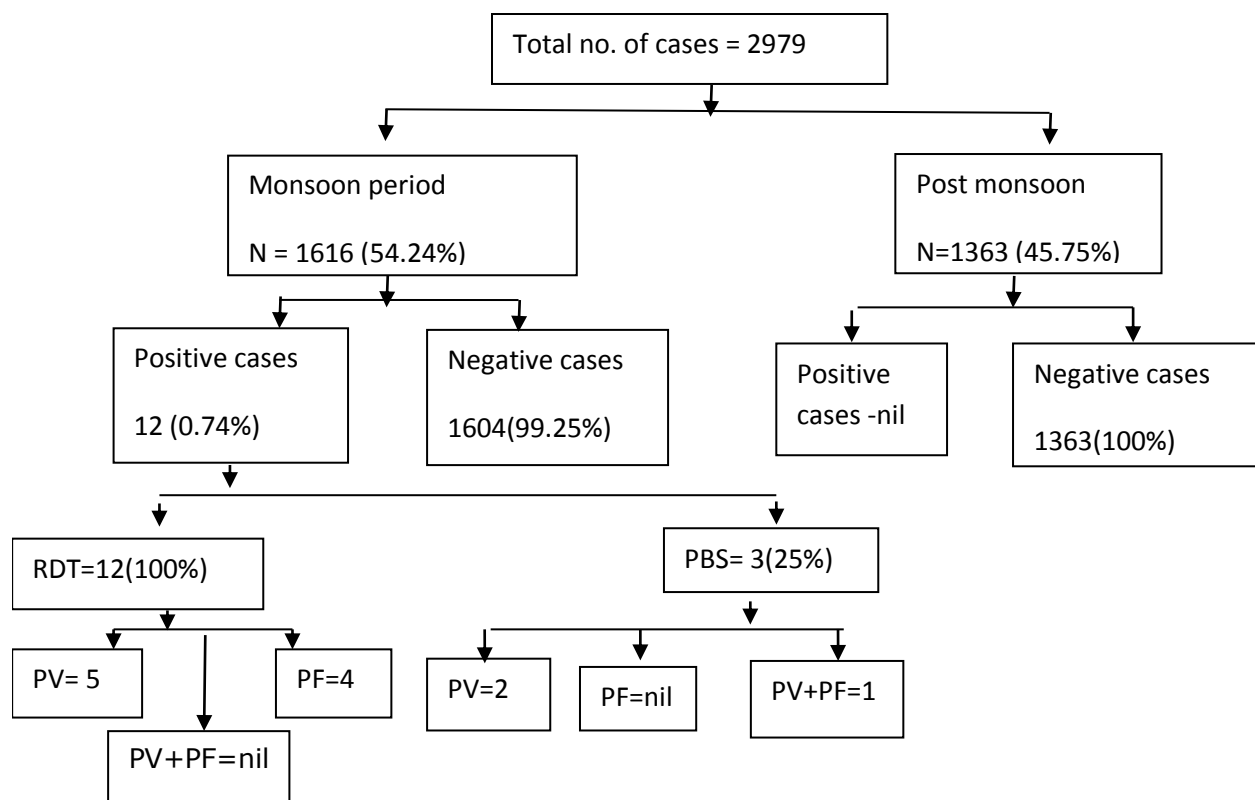


Table.1 Month wise Trend of sample outflow during monsoon and post-monsoon periods

	Months	Total cases	Positives	Negative
Monsoon period (n=1616)	June	370	04	366
	July	566	05	561
	August	680	03	677
Post Monsoon period (n=1363)	September	662	Nil	662
	October	701	Nil	701
Total		2979	12	2967

Table.2 Age-wise distribution of positive cases

Age groups (yrs)	RDT		PBS	
	<i>P. vivax</i>	<i>P. falciparum</i>	<i>P. vivax</i>	<i>P. falciparum</i>
1-10	--	--	--	--
11-20	02	01	--	--
21-40	03	03	02	01
41-60	--	--	--	--
61-80	--	--	--	--
Total	05	04	02	01

Table.3 Gender-wise distribution of Positive cases

Gender	RDT		PBS		Total
	<i>P. vivax</i>	<i>P. falciparum</i>	<i>P. vivax</i>	<i>P. falciparum</i>	
Male	04	03	02	--	09(75%)
Female	01	01		01	03(25%)
Total	05	04	02	01	12

The Rapid Antigen Detection Assay results indicated a prevalence of 12 (100%) while microscopy indicated the total prevalence of 3 (25%) out of the 100 persons that were examined (Moody, 2002; Singh *et al.*, 2013). The sensitivity of thin smear found to be lowest (25%) which may be because of the undefined ring stage of the parasite. While (Parija and Praharaj, 2011) reported a very low sensitivity of (54.8%) leishman stained thin smear. Leishman stained thin blood smear detects malarial parasite only when there are 50 parasite/ ml of blood. Even though this method can be used for species identification of malarial parasite, Still the limitation of rapid diagnostic methods like failure of the parasites to express the antigen due to deletion of the gene *pfhrp2* (Koita *et al.*, 2012), anti Pf-HRP2 antibodies in humans or storage conditions remained (Koita *et al.*, 2012)

There was an increase in trend of fever of unknown origin during monsoon and post monsoon period. However, the results of positive cases are lower during this monsoon and post monsoon seasons. The geographic prevalence was nil during the post monsoon period. This may be attributed to the fact that the present study was carried out during dry season when stagnant water bodies have been dried up and the breeding sites of mosquitoes interrupted or progress in the control of malaria through the use of insecticide by Municipal Corporation. The result clearly indicated that Rapid antigen detection test had higher sensitivity and specificity compared to PBS. Our study results contradict with study

by (Moody, 2002; Singh *et al.*, 2013). The prevalence of malaria parasite by both methods showed that, age group 21-40 years had the greatest risk of infection followed by 11-20 years (Table 2). The prevalence of malaria parasite by gender as shown in both methods was higher in males than in females (See Table 3). This sex distribution showed that males are more prone to the infection which is in accordance with the Nwaorgu and Orajika (2011) and Okafor and Oko-Ose, (2012) who reported higher prevalence in males in different parts of the country.

This study revealed declining trend of malaria in 2016. Rapid antigen detection kits are more specific and sensitive in detection of the malarial parasites especially in endemic areas even with low parasitaemia. Thus RDT can be a promising alternative to microscopy. But still microscopy remains the gold standard method for malaria diagnosis considering the cost and availability.

Acknowledgements

All the staff members of Microbiology Department, VIMS.

References

Anirudh R Acharya, Jhansi Lakshmi Magisetty, Adarsha Chandra VR. Chaithra BS, Taiyaba Khanum and Vijayan VA. Trend of malaria incidence in the state of Karnataka, India for 2001 to 2011. Archives of Applied Science Research 2013; 5(3):104-111.

- Bruce-Chwatt LJ. DNA probes for malaria diagnosis. *Lancet* 1984; 1:795.
- Deepika Verma, Sachin Kishore, Siddie ME. Comparative evaluation of various tests for diagnosis of concurrent malaria and typhoid fever in a tertiary care hospital of northern India. *Journal of Clinical and Diagnostic Research*. 2014; 8(5):41-44.
- Jafar Ebrahim, J., I. Al-Ghonaim Mohammed, Maghram Al-Amri, H. Abdel-Ghaffar Mamdouh¹, N. Ramprasad, R. Farhan Khan. Comparative Study of Thick Smear, Thin Smear, QBC and Antigen Card Test in Diagnosis of Malaria. *Int. J. Pure Appl. Sci. Technol* 2013; 17(1): 54-59.
- Koita OA, Doumbo OK, Ouattara A, Tall LK, Konaré A. False-negative rapid diagnostic tests for malaria and deletion of the histidine-rich repeat region of the *hrp2* gene. *Am J Trop Med Hyg* 2012; 86: 194-198.
- Manjunatha S, Preeti BM, Basavaraj VP. Comparative Study of Peripheral Blood Smear, QBC and Antigen Detection in Malaria Diagnosis. *Journal of Clinical and Diagnostic Research* 2011; 5(5):967-969.
- Moody, A. Rapid Diagnostic Tests for Malaria Parasites. *Clinical Microbiology Reviews* 2002; 15(1): 66 - 78.
- Nwaorgu, O.C. and Orajaka, B. N. Prevalence of malaria among Children 1-10 years old in Communities in Awka North Local Government Area, Anambra State, South East Nigeria. *International Multidisciplinary Journal Ethiopia* 2011. 5(5): 264 -281.
- Okafor, F. U. and Oko-Ose, J. N. Prevalence of malaria infections among children aged six months to eleven years (6 months-11 years) in a tertiary institution in Benin City, Nigeria. *Global Advanced Journal and Medical Sciences* 2012; 1(10): 273 - 279.
- Parija SC, Praharaj I. Drug resistance in malaria. *Indian J Med Microbiol* 2011; 29: 243-8.
- Pinto MJW, Rodrigues SR, Desouza R, Verenkar MP. Usefulness of quantitative buffy coat blood parasite detection system in diagnosis of malaria. *Indian J Med Microbiol* 2001; 19:219-21.
- Singh, R., Abdullahi, K., Mohammad, D. A., Bunza, M. D. A., Njoku, C. N., Singh, S., Usman, N. S., and Kaitholia, K. Comparative Diagnosis of Falciparum Malaria Infections by Microscopy, Two RDTs and Nested PCR in the Three States of North- western Nigeria. *Journal Biology Agriculture and Healthcare* 2013; 3(5): 31- 38.
- World Health Organization, *Universal Access to Malaria Diagnostic Testing: an Operational Manual*, WHO, Geneva Switzerland, 2011.
- World Malaria Report, Geneva Switzerland: WHO Press; 2015
- Yasmeen Khatib, Sanjay Gulhane, Karen Sequeira. Correlation and comparative evaluation of Thick smear, thin smear and Antigen detection test in the diagnosis of Malaria. *Sch. J. App. Med. Sci* 2016; 4(5):1770-1773.

How to cite this article:

Vishalakshi, B., J. Mariraj, S. Liba and Krishna, S. 2018. Cross Sectional Study Comparing Peripheral Blood Smear and Rapid Antigen Detection Test in Diagnosis of Malaria Conducted During Monsoon and Post Monsoon Period at Ballari, India. *Int.J.Curr.Microbiol.App.Sci*. 7(02): 255-260. doi: <https://doi.org/10.20546/ijemas.2018.702.033>