

Original Research Article

<https://doi.org/10.20546/ijcmas.2018.711.049>

Gross Morphological and Sex wise Morphometrical Studies on the Third to Fifteenth Coccygeal Vertebrae of Blue Bull (*Boselaphus tragocamelus*)

S. Sathapathy^{1*}, B.S. Dhote², D. Mahanta², S. Tamilselvan², I. Singh²,
M. Mrigesh² and S.K. Joshi³

¹Department of Veterinary Anatomy & Histology, CVSc. & A.H., Bhubaneswar-751 003, India

²Department of Veterinary Anatomy, CVASc., GBPUAT, Pantnagar – 263 145, India

³(KVK, Jharsuguda), OUAT, Bhubaneswar – 751 003, India

*Corresponding author

ABSTRACT

The present study was carried out on the third to fifteenth coccygeal vertebrae of six specimens of adult Blue bull (*Boselaphus tragocamelus*) of either sex. The Cy₃-Cy₆ presented complete arches and spinous processes. The transverse processes and cranial non-articular processes were present in Cy₃-Cy₆ and then reduced in caudal part of the series. The transverse processes were found to be plate like that were directed downward, backward and exceeded beyond the level of the posterior articular surface of the body in Cy₃. They were reduced to tubercles in were reduced to tubercles in Cy₄-Cy₇ and disappeared beyond Cy₇. The neural rings were found to be complete in Cy₃-Cy₄ and then became reduced in Blue bull. The dorsal supraspinous processes were found to be thin and flat in Cy₃-Cy₄. The summits of the dorsal supraspinous processes were thick, tuberos and bifid. A foramen having 0.09±0.001 cm diameter was located 0.64±0.012 cm away from the dorsal spine in Cy₃ in the Blue bull. The cranial processes were present in Cy₃-Cy₅ and they disappeared after Cy₅. The caudal processes were absent. The extremities of bodies were rounded anteriorly and flattened posteriorly. The ventral spine was prominent up to Cy₇ and thereafter persisted as the ventral tubercle. The fifteenth coccygeal vertebra was represented by cylindrical body with reduced processes. The Biometrical observations on different parameters of third to fifteenth coccygeal vertebrae reflected significance (P<0.05) differences between the sexes of this species.

Keywords

Coccygeal vertebrae, Blue bull, Morphology, Morphometry

Article Info

Accepted:

04 October 2018

Available Online:

10 November 2018

Introduction

The Blue bull (*Boselaphus tragocamelus*) is known to be one of the biggest antelopes in Asia and is widely found in both the forests and adjoining villages with enough green grass (Sathapathy *et al.*, 2017). Blue bull is considered sacred as per Hindu religion since Vedic period (1500-500 BC) and it is

considered as religious. The Blue bull belongs to the family Bovidae and comes under the genus *Boselaphus* (Sathapathy *et al.*, 2018a). The German Zoologist Scientist Peter Simon Pallas explained this species for the first time in 1766. English Zoologist Scientist Philips for the first time in 1833 narrated the binomial combination of the Blue bull. It is quite prevalent in northern and central parts of India

especially in the foothills of Himalayas, eastern part of Pakistan and southern part of Nepal, but has vanished from Bangladesh (Sathapathy *et al.*, 2018b). The adult male appears like ox and so called as Blue bull. They are usually seen in day times in the meadow pasture, timberland areas and agricultural land area. It prefers mostly plain or grassy plain and low hilly areas with shrubs, small bushes, scrub forests with scattered trees and does not usually found in dense forest areas, dense compact wood, etc. The Blue bulls are safeguarded beneath the IUCN since 2003 and also under safeguard of 'Schedule III' of the Indian Wildlife Protection Act, 1972 (Bagchi *et al.*, 2004). The Blue bull is safeguarded in various parts of India such as Gir National Park (Gujarat), Kumbhalgarh Sanctuary (Rajasthan) and Panchamarahi Biosphere Reserve, India. The massive body of the Blue bull can be attributed to the large skeleton of the antelope. Further, the skeleton comprises of large and massive bones of axial and appendicular skeleton that not only protects the viscera, but also provides shape and support to the heavy musculature of the Blue bull (Sathapathy *et al.*, 2018c). The present osteo-morphological study developed a baseline data on the third to fifteenth coccygeal vertebrae of adult Blue bull that would immensely help the wild life anatomists and Veterinarians in species identification and solving forensic and vetero-legal cases as no previous work has been done in this field on the Blue bull.

Materials and Methods

The present study was carried out on the third to fifteenth coccygeal vertebrae of six specimens of adult Blue bulls (*Boselaphus tragocamelus*) of either sex. The permission for the collection of bones was acquired from the Principal Chief Conservator of Forests (PCCF), Government of Rajasthan. The bones were possessed from the Jodhpur zoo,

Rajasthan getting authentic confirmation from the Principal Chief Conservator of Forests (PCCF), Government of Rajasthan. The skeletons were taken out from the burial ground that was located in the premises of the office of the Deputy Conservator of Forest Wildlife (WL), Jodhpur. Afterwards, the specimens were processed as per standard technique given by Snedecor and Cochran (1994). The gross study was conducted under the supervision of the Zoo Authority, Jodhpur, India. The different parameters of third to fifteenth coccygeal vertebrae of Blue bull were measured and subjected to routine statistical analysis and independent samples t-Test with Systat Software Inc, USA and SPSS 16.0 version software.

Results and Discussion

The skeleton of tail of Blue bull was formed by 15 to 21 in numbers of coccygeal vertebrae (Fig. 1), but Getty *et al.*, (1930) recorded 18 to 20 coccygeal vertebrae in ox and 15 to 21 in horse, Brelend (1943) found 20 to 23 vertebrae in cat, but in the Manx cat usually 3 to 4 coccygeal vertebrae were found, Miller *et al.*, (1964) observed 6 to 23 coccygeal vertebrae in dog, Raghavan (1964) recorded 15 to 20 coccygeal vertebrae in ox, Smuts and Bezuidenhout (1987) studied 15 to 17 coccygeal vertebrae in camel, Yilmaz (1998) described 12 coccygeal vertebrae in porcupine, Yilmaz *et al.*, (2000) found 18 coccygeal vertebrae in otters, Ozkan (2007) mentioned five coccygeal vertebrae in mole-rats and Meena (2012) observed 12 to 18 coccygeal vertebrae in chital. The Cy₃-Cy₆ presented complete arches and spinous processes. The transverse processes and cranial non-articular processes were present in Cy₃-Cy₆ and then reduced in caudal part of the series. The transverse processes were found to be plate like that were directed downward, backward and exceeded beyond the level of the posterior articular surface of the body in

Cy₃. They were reduced to tubercles in were reduced to tubercles in Cy₄ - Cy₇ and disappeared beyond Cy₇. The neural rings were found to be complete in Cy₃-Cy₄ and then became reduced in Blue bull. The dorsal supraspinous processes were found to be thin and flat in Cy₃-Cy₄. The summits of the dorsal supraspinous processes were thick, tuberous and bifid in Blue bull (Fig. 2 and Fig. 4). A foramen having 0.09±0.001 cm diameter was located 0.64±0.012 cm away from the dorsal spine in Cy₃ in the Blue bull. The cranial processes were present in Cy₃-Cy₅ and they disappeared after Cy₅. The caudal processes were absent.

The extremities of bodies were rounded anteriorly and flattened posteriorly in coccygeal vertebrae, which simulated the findings of Getty *et al.*, (1930) in horse and ox, Raghavan (1964) in ox, Smuts and Bezuidenhout (1987) in camel and Konig and Liebich (2005) in horse. The ventral surfaces of the bodies of coccygeal vertebrae were concave in Blue bull. The ventral spine was bifid forming a groove known as sulcus vasculosus that provided the passage for the middle coccygeal artery (Fig. 3). This artery is usually approached for recording pulse rate in the Blue bull. Further, the ventral spine was prominent up to Cy₇ and thereafter persisted as the ventral tubercle. The fifteenth coccygeal vertebra was represented by cylindrical body with reduced processes in Blue bull (Fig. 5).

Biometrical observation

The biometrical observations revealed characteristic differences between the sexes of the Blue bull.

Third coccygeal vertebra

Biometrical studies revealed that the average weight was found to be 19.72±0.45 gm in adult Blue bull. Further, it was measured as

18.85±0.20 gm in females that was significantly lesser (P<0.05) than that of males, where it was found to be 20.58±0.46 gm. The average length of the body was found to be 4.02±0.06 cm in adult Blue bull. Further, it was measured as 3.90±0.06 cm in females that was significantly lesser (P<0.05) than that of males, where it was found to be 4.13±0.03 cm (Table 1). Similarly, the average width of the body at the middle was found to be 1.22±0.06 cm in adult Blue bull. Further, it was measured as 1.10±0.06 cm in females that was significantly lesser (P<0.05) than that of males, where it was found to be 1.33±0.03 cm.

The average cranial diameter of vertebral canal was found to be 0.15±0.01 cm in adult Blue bull. Further, it was measured as 0.12±0.01 cm in females that was significantly lesser (P<0.05) than that of males, where it was found to be 0.18±0.01 cm. The average caudal diameter of vertebral canal was found to be 0.09±0.01 cm in adult Blue bull. Further, it was measured as 0.07±0.01 cm and 0.11±0.01 cm in females and males respectively. The average length of vertebral canal was found to be 2.83±0.03 cm in adult Blue bull. Further, it was measured as 2.78±0.03 cm and 2.88±0.02 cm in females and males respectively. The average distance between the vertebral canal of Cy₃ and Cy₄ was found to be 1.18±0.07 cm in adult Blue bull. Further, it was measured as 1.07±0.03 cm and 1.30±0.12 cm in females and males respectively.

The average length of dorsal spine was found to be 0.66±0.02 cm in adult Blue bull. Further, it was measured as 0.62±0.02 cm in females that was significantly lesser (P<0.05) than that of males, where it was found to be 0.70±0.01 cm. The average height of dorsal spine at the cranial aspect was found to be 0.15±0.01 cm in adult Blue bull. Further, it was measured as 0.13±0.01 cm in females that was significantly lesser (P<0.05) than that of males, where it

was found to be 0.18 ± 0.01 cm. Similarly, the average height of dorsal spine at the middle was found to be 0.24 ± 0.01 cm in adult Blue bull.

Further, it was measured as 0.22 ± 0.01 cm in females that was significantly lesser ($P<0.05$) than that of males, where it was found to be 0.27 ± 0.01 cm. The average height of dorsal spine at the caudal aspect was found to be 0.15 ± 0.01 cm in adult Blue bull. Further, it was measured as 0.13 ± 0.01 cm in females that was significantly lesser ($P<0.05$) than that of males, where it was found to be 0.17 ± 0.01 cm. The average thickness of dorsal spine at the cranial aspect was found to be 0.11 ± 0.01 cm in adult Blue bull. Further, it was measured as 0.10 ± 0.01 cm in females that was significantly lesser ($P<0.05$) than that of males, where it was found to be 0.13 ± 0.01 cm. Similarly, the average thickness of dorsal spine at the middle was found to be 0.18 ± 0.01 cm in adult Blue bull. Further, it was measured as 0.17 ± 0.02 cm in females that was significantly lesser ($P<0.05$) than that of males, where it was found to be 0.20 ± 0.02 cm. The average thickness of dorsal spine at the caudal aspect was found to be 0.20 ± 0.01 cm in adult Blue bull. Further, it was measured as 0.18 ± 0.01 cm and 0.22 ± 0.01 cm in females and males respectively.

The average distance between the two parts of dorsal spine at the cranial aspect was found to be 0.35 ± 0.02 cm in adult Blue bull. Further, it was measured as 0.32 ± 0.01 cm in females that was significantly lesser ($P<0.05$) than that of males, where it was found to be 0.39 ± 0.01 cm. The average distance between the two parts of dorsal spine at the middle was found to be 0.24 ± 0.01 cm in adult Blue bull. Further, it was measured as 0.22 ± 0.01 cm and 0.25 ± 0.01 cm in females and males respectively. Similarly, the average distance between the two parts of dorsal spine at the caudal aspect was found to be 0.31 ± 0.01 cm in adult Blue

bull. Further, it was measured as 0.31 ± 0.01 cm and 0.32 ± 0.01 cm in females and males respectively. The average length of transverse process was found to be 1.40 ± 0.07 cm in adult Blue bull. Further, it was measured as 1.23 ± 0.07 cm in females that was significantly lesser ($P<0.05$) than that of males, where it was found to be 1.57 ± 0.09 cm.

The average width of transverse process at the cranial aspect was found to be 0.93 ± 0.04 cm in adult Blue bull. Further, it was measured as 0.88 ± 0.06 cm and 0.99 ± 0.05 cm in females and males respectively. Similarly, the average width of transverse process at the middle was found to be 0.98 ± 0.04 cm in adult Blue bull. Further, it was measured as 0.95 ± 0.06 cm and 1.02 ± 0.05 cm in females and males respectively. The average width of transverse process at the caudal aspect was found to be 0.62 ± 0.03 cm in adult Blue bull. Further, it was measured as 0.58 ± 0.04 cm and 0.66 ± 0.05 cm in females and males respectively. The average distance between the transverse processes of Cy_3 and Cy_4 was found to be 3.25 ± 0.04 cm in adult Blue bull. Further, it was measured as 3.22 ± 0.06 cm and 3.29 ± 0.05 cm in females and males respectively. The average length of cranial non-articular process was found to be 1.19 ± 0.06 cm in adult Blue bull. Further, it was measured as 1.05 ± 0.04 cm in females that was significantly lesser ($P<0.05$) than that of males, where it was found to be 1.33 ± 0.07 cm. The average width of cranial non-articular process at the cranial aspect was found to be 0.46 ± 0.03 cm in adult Blue bull. Further, it was measured as 0.42 ± 0.04 cm and 0.50 ± 0.04 cm in females and males respectively. Similarly, the average width of cranial non-articular process at the middle was found to be 0.51 ± 0.02 cm in adult Blue bull. Further, it was measured as 0.48 ± 0.03 cm and 0.54 ± 0.03 cm in females and males respectively. The average width of cranial non-articular process at the caudal aspect was found to be 0.43 ± 0.01 cm in adult

Blue bull. Further, it was measured as 0.40 ± 0.01 cm in females that was significantly lesser ($P<0.05$) than that of males, where it was found to be 0.46 ± 0.01 cm.

The average minimum distance between the two cranial non-articular processes was found to be 1.32 ± 0.01 cm in adult Blue bull. Further, it was measured as 1.30 ± 0.01 cm in females that was significantly lesser ($P<0.05$) than that of males, where it was found to be 1.35 ± 0.01 cm. The average distance between the cranial non-articular process and transverse process was found to be 1.41 ± 0.03 cm in adult Blue bull. Further, it was measured as 1.39 ± 0.04 cm and 1.44 ± 0.03 cm in females and males respectively.

The average distance between the cranial non-articular processes of Cy_3 and Cy_4 was found to be 3.30 ± 0.06 cm in adult Blue bull. Further, it was measured as 3.28 ± 0.09 cm and 3.33 ± 0.09 cm in females and males respectively. The average length of ventral spine was found to be 1.37 ± 0.05 cm in adult Blue bull. Further, it was measured as 1.34 ± 0.07 cm and 1.39 ± 0.07 cm in females and males respectively. Similarly, the average height of ventral spine at the cranial aspect was found to be 0.41 ± 0.02 cm in adult Blue bull. Further, it was measured as 0.38 ± 0.02 cm and 0.43 ± 0.02 cm in females and males respectively. The average height of ventral spine at the middle was found to be 0.46 ± 0.01 cm in adult Blue bull. Further, it was measured as 0.44 ± 0.01 cm in females that was significantly lesser ($P<0.05$) than that of males, where it was found to be 0.48 ± 0.01 cm. Similarly, the average height of ventral spine at the caudal aspect was found to be 0.43 ± 0.01 cm in adult Blue bull. Further, it was measured as 0.41 ± 0.01 cm in females that was significantly lesser ($P<0.05$) than that of males, where it was found to be 0.46 ± 0.01 cm. The average distance between the ventral spines of Cy_3 and Cy_4 was found to be

2.86 ± 0.03 cm in adult Blue bull. Further, it was measured as 2.78 ± 0.02 cm in females that was significantly lesser ($P<0.05$) than that of males, where it was found to be 2.95 ± 0.02 cm.

The average length of sulcus vasculosus was found to be 1.34 ± 0.02 cm in adult Blue bull. Further, it was measured as 1.30 ± 0.01 cm in females that was significantly lesser ($P<0.05$) than that of males, where it was found to be 1.38 ± 0.02 cm. The average width of sulcus vasculosus at the cranial aspect was found to be 0.22 ± 0.02 cm in adult Blue bull. Further, it was measured as 0.20 ± 0.01 cm and 0.24 ± 0.03 cm in females and males respectively. Similarly, the average width of sulcus vasculosus at the middle was found to be 0.17 ± 0.01 cm in adult Blue bull. Further, it was measured as 0.15 ± 0.01 cm and 0.18 ± 0.01 cm in females and males respectively. The average width of sulcus vasculosus at the caudal aspect was found to be 0.14 ± 0.01 cm in adult Blue bull. Further, it was measured as 0.11 ± 0.01 cm and 0.17 ± 0.02 cm in females and males respectively. The average distance between the sulcus vasculosus of Cy_3 and Cy_4 was found to be 3.27 ± 0.06 cm in adult Blue bull. Further, it was measured as 3.17 ± 0.09 cm and 3.37 ± 0.03 cm in females and males respectively.

Fourth to fifteenth coccygeal vertebrae

Biometrical observations revealed that the average weight of Cy_4 was found to be 8.47 ± 0.29 gm in adult Blue bull. Further, it was measured as 7.95 ± 0.04 gm and 8.98 ± 0.39 gm in females and males respectively. The average weight of Cy_5 was found to be 6.81 ± 0.09 gm in adult Blue bull. Further, it was measured as 6.66 ± 0.05 gm and 6.96 ± 0.12 gm in females and males respectively. Similarly, the average weight of Cy_6 was found to be 5.31 ± 0.06 gm in adult Blue bull. Further, it was measured as 5.23 ± 0.04 gm and 5.39 ± 0.09 gm in females and males

respectively. The average weight of Cy₇ was found to be 4.15±0.08 gm in adult Blue bull. Further, it was measured as 4.00±0.07 gm in females that was significantly lesser (P<0.05) than that of males, where it was found to be 4.30±0.05 gm. The average weight of Cy₈ was found to be 3.87±0.05 gm in adult Blue bull. Further, it was measured as 3.78±0.03 gm in females that was significantly lesser (P<0.05) than that of males, where it was found to be 3.95±0.05 gm. Similarly, the average weight of Cy₉ was found to be 3.27±0.06 gm in adult Blue bull.

Further, it was measured as 3.16±0.03 gm in females that was significantly lesser (P<0.05) than that of males, where it was found to be 3.38±0.06 gm. The average weight of Cy₁₀ was found to be 3.19±0.06 gm in adult Blue bull. Further, it was measured as 3.09±0.02 gm in females that was significantly lesser (P<0.05) than that of males, where it was found to be 3.29±0.07 gm. Similarly, the average weight of Cy₁₁ was found to be 3.10±0.05 gm in adult Blue bull. Further, it was measured as 3.01±0.01 gm in females that was significantly lesser (P<0.05) than that of males, where it was found to be 3.18±0.06 gm.

The average weight of Cy₁₂ was found to be 2.89±0.04 gm in adult Blue bull. Further, it was measured as 2.81±0.01 gm in females that was significantly lesser (P<0.05) than that of males, where it was found to be 2.96±0.03 gm. The average weight of Cy₁₃ was found to be 2.81±0.03 gm in adult Blue bull. Further, it was measured as 2.75±0.02 gm and 2.87±0.04 gm in females and males respectively.

The average weight of Cy₁₄ was found to be 2.28±0.03 gm in adult Blue bull. Further, it was measured as 2.22±0.02 gm in females that was significantly lesser (P<0.05) than that of males, where it was found to be 2.34±0.02 gm. Similarly, the average weight of Cy₁₅ was found to be 1.98±0.05 gm in adult Blue bull.

Further, it was measured as 1.88±0.03 gm in females that was significantly lesser (P<0.05) than that of males, where it was found to be 2.08±0.04 gm.

The average length of the body of Cy₄ was found to be 3.33±0.09 cm in adult Blue bull. Further, it was measured as 3.17±0.09 cm in females that was significantly lesser (P<0.05) than that of males, where it was found to be 3.50±0.06 cm. Similarly, the average length of the body of Cy₅ was found to be 3.70±0.07 cm in adult Blue bull. Further, it was measured as 3.57±0.09 cm in females that was significantly lesser (P<0.05) than that of males, where it was found to be 3.83±0.03 cm. The average length of the body of Cy₆ was found to be 3.52±0.05 cm in adult Blue bull. Further, it was measured as 3.43±0.03 cm and 3.60±0.06 cm in females and males respectively. The average length of the body of Cy₇ was found to be 3.12±0.07 cm in adult Blue bull. Further, it was measured as 3.00±0.06 cm and 3.23±0.09 cm in females and males respectively. Similarly, the average length of the body of Cy₈ was found to be 3.30±0.09 cm in adult Blue bull.

Further, it was measured as 3.17±0.12 cm and 3.43±0.09 cm in females and males respectively. The average length of the body of Cy₉ was found to be 3.35±0.08 cm in adult Blue bull. Further, it was measured as 3.20±0.06 cm in females that was significantly lesser (P<0.05) than that of males, where it was found to be 3.50±0.06 cm. The average length of the body of Cy₁₀ was found to be 3.03±0.07 cm in adult Blue bull.

Further, it was measured as 2.93±0.09 cm and 3.13±0.09 cm in females and males respectively. Similarly, the average length of the body of Cy₁₁ was found to be 2.78±0.07 cm in adult Blue bull. Further, it was measured as 2.67±0.09 cm and 2.90±0.06 cm in females and males respectively.

Table.1 Measurements of third coccygeal vertebra of Blue bull in cm

Parameters		Range	Mean	SD	SE	Female (Mean±SE)	Male (Mean±SE)	
Body	Length	3.8-4.2	4.02	0.15	0.06	3.90*±0.06	4.13±0.03	
	Width at the middle	1.0-1.4	1.22	0.15	0.06	1.10*±0.06	1.33±0.03	
Dorsal spine	Length	0.57-0.75	0.66	0.05	0.02	0.62*±0.02	0.70±0.01	
	Height	Cranial	0.09-0.20	0.15	0.03	0.01	0.13*±0.01	0.18±0.01
		Middle	0.18-0.29	0.24	0.03	0.01	0.22*±0.01	0.27±0.01
		Caudal	0.11-0.20	0.15	0.03	0.01	0.13*±0.01	0.17±0.01
	Thickness	Cranial	0.09-0.15	0.11	0.02	0.01	0.10*±0.01	0.13±0.01
		Middle	0.11-0.26	0.18	0.05	0.01	0.17±0.02	0.20±0.02
Caudal		0.13-0.26	0.20	0.04	0.01	0.18±0.01	0.22±0.01	
Transverse process	Length	1.0-1.9	1.40	0.25	0.07	1.23*±0.07	1.57±0.09	
	Width	Cranial	0.70-1.11	0.93	0.13	0.04	0.88±0.06	0.99±0.05
		Middle	0.79-1.16	0.98	0.13	0.04	0.95±0.06	1.02±0.05
		Caudal	0.46-0.81	0.62	0.12	0.03	0.58±0.04	0.66±0.05
Cranial non-articular process	Length	0.9-1.5	1.19	0.20	0.06	1.05*±0.04	1.33±0.07	
	Width	Cranial	0.30-0.62	0.46	0.10	0.03	0.42±0.04	0.50±0.04
		Middle	0.40-0.64	0.51	0.08	0.02	0.48±0.03	0.54±0.03
		Caudal	0.37-0.49	0.43	0.04	0.01	0.40*±0.01	0.46±0.01
Ventral spine	Length	1.18-1.61	1.37	0.16	0.05	1.34±0.07	1.39±0.07	
	Height	Cranial	0.32-0.51	0.41	0.06	0.02	0.38±0.02	0.43±0.02
		Middle	0.41-0.50	0.46	0.03	0.01	0.44*±0.01	0.48±0.01
		Caudal	0.37-0.48	0.43	0.03	0.01	0.41*±0.01	0.46±0.01
Distance between cranial non-articular process and transverse process		1.29-1.55	1.41	0.09	0.03	1.39±0.04	1.44±0.03	
Sulcus vasculosus	Length	1.28-1.41	1.34	0.05	0.02	1.30*±0.01	1.38±0.02	
	Width	Cranial	0.17-0.29	0.22	0.04	0.02	0.20±0.01	0.24±0.03
		Middle	0.13-0.19	0.17	0.02	0.01	0.15±0.01	0.18±0.01
		Caudal	0.10-0.20	0.14	0.04	0.01	0.11±0.01	0.17±0.02
Diameter of vertebral canal	Cranial	0.10-0.19	0.15	0.03	0.01	0.12*±0.01	0.18±0.01	
	Caudal	0.05-0.13	0.09	0.03	0.01	0.07±0.01	0.11±0.01	
Distance between two parts of dorsal spine	Cranial	0.30-0.40	0.35	0.04	0.02	0.32*±0.01	0.39±0.01	
	Middle	0.21-0.27	0.24	0.02	0.01	0.22±0.01	0.25±0.01	
	Caudal	0.29-0.34	0.31	0.02	0.01	0.31±0.01	0.32±0.01	
Length of vertebral canal		2.72-2.92	2.83	0.07	0.03	2.78±0.03	2.88±0.02	
Minimum distance between two cranial non-articular processes		1.28-1.36	1.32	0.03	0.01	1.30*±0.01	1.35±0.01	

Values bearing superscript (*) differ significantly in column P < 0.05

Table.2 Different measurements of coccygeal vertebra of Blue bull in cm

Parameters		Range	Mean	SD	SE	Female (Mean±SE)	Male (Mean±SE)	
Length of body	Cy ₄	3.0-3.6	3.33	0.22	0.09	3.17*±0.09	3.50±0.06	
	Cy ₅	3.4-3.9	3.70	0.18	0.07	3.57*±0.09	3.83±0.03	
	Cy ₆	3.4-3.7	3.52	0.12	0.05	3.43±0.03	3.60±0.06	
	Cy ₇	2.9-3.4	3.12	0.17	0.07	3.00±0.06	3.23±0.09	
	Cy ₈	3.0-3.6	3.30	0.22	0.09	3.17±0.12	3.43±0.09	
	Cy ₉	3.1-3.6	3.35	0.19	0.08	3.20*±0.06	3.50±0.06	
	Cy ₁₀	2.8-3.3	3.03	0.18	0.07	2.93±0.09	3.13±0.09	
	Cy ₁₁	2.5-3.0	2.78	0.17	0.07	2.67±0.09	2.90±0.06	
	Cy ₁₂	2.4-2.8	2.62	0.15	0.06	2.57±0.09	2.67±0.09	
	Cy ₁₃	1.9-2.2	2.10	0.18	0.07	1.97*±0.03	2.23±0.09	
	Cy ₁₄	1.3-1.8	1.60	0.18	0.07	1.47*±0.09	1.73±0.03	
	Cy ₁₅	1.0-1.4	1.20	0.14	0.06	1.10±0.06	1.30±0.06	
	Length of transverse process	Cy ₄	0.67-0.92	0.81	0.07	0.02	0.75*±0.02	0.86±0.02
		Cy ₅	0.51-0.79	0.67	0.09	0.02	0.63±0.03	0.71±0.03
		Cy ₆	0.64-0.94	0.84	0.09	0.03	0.79±0.04	0.89±0.02
Cy ₇		0.40-0.60	0.51	0.06	0.02	0.47*±0.02	0.55±0.01	
Distance between transverse processes of adjacent vertebrae	Cy ₁ -Cy ₂	3.18-3.71	3.47	0.18	0.05	3.39±0.08	3.55±0.06	
	Cy ₂ -Cy ₃	3.08-3.28	3.17	0.06	0.02	3.14±0.02	3.20±0.03	
	Cy ₃ -Cy ₄	3.02-3.42	3.25	0.14	0.04	3.22±0.06	3.29±0.05	
	Cy ₄ -Cy ₅	3.28-3.62	3.48	0.11	0.03	3.43±0.05	3.53±0.03	
	Cy ₅ -Cy ₆	3.09-3.56	3.31	0.19	0.05	3.27±0.08	3.34±0.08	
	Cy ₆ -Cy ₇	2.56-3.14	2.84	0.27	0.08	2.81±0.12	2.87±0.11	
Distance between cranial non-articular processes of adjacent vertebrae	Cy ₁ -Cy ₂	3.19-3.50	3.36	0.10	0.03	3.31±0.04	3.41±0.04	
	Cy ₂ -Cy ₃	3.19-3.40	3.29	0.06	0.02	3.25*±0.02	3.33±0.02	
	Cy ₃ -Cy ₄	3.05-3.56	3.30	0.21	0.06	3.28±0.09	3.33±0.09	
	Cy ₄ -Cy ₅	2.99-3.35	3.17	0.13	0.04	3.14±0.05	3.20±0.06	
Distance between sulcus vasculosus of adjacent vertebrae	Cy ₁ -Cy ₂	2.2-2.6	2.45	0.14	0.06	2.37±0.09	2.53±0.03	
	Cy ₂ -Cy ₃	2.6-2.8	2.72	0.08	0.03	2.67±0.03	2.77±0.03	
	Cy ₃ -Cy ₄	3.0-3.4	3.27	0.15	0.06	3.17±0.09	3.37±0.03	
	Cy ₄ -Cy ₅	2.9-3.4	3.10	0.18	0.07	3.00±0.06	3.20±0.12	
	Cy ₅ -Cy ₆	2.9-3.3	3.10	0.14	0.06	3.00±0.06	3.20±0.06	
	Cy ₆ -Cy ₇	2.8-3.3	3.05	0.16	0.07	2.97±0.09	3.13±0.09	
Distance between ventral spines of adjacent vertebrae	Cy ₁ -Cy ₂	2.09-2.45	2.27	0.13	0.04	2.24±0.06	2.30±0.05	
	Cy ₂ -Cy ₃	2.48-3.22	2.86	0.32	0.09	2.82±0.13	2.90±0.14	
	Cy ₃ -Cy ₄	2.70-3.01	2.86	0.10	0.03	2.78*±0.02	2.95±0.02	
	Cy ₄ -Cy ₅	3.08-3.28	3.17	0.06	0.02	3.14±0.02	3.21±0.02	
	Cy ₅ -Cy ₆	3.11-3.33	3.21	0.08	0.02	3.17±0.03	3.25±0.03	
	Cy ₆ -Cy ₇	3.07-3.42	3.21	0.13	0.04	3.16±0.04	3.26±0.05	
Distance between vertebral canal of adjacent vertebrae	Cy ₁ -Cy ₂	1.8-2.3	2.02	0.17	0.07	1.90±0.06	2.13±0.09	
	Cy ₂ -Cy ₃	1.8-2.4	2.05	0.23	0.10	1.87*±0.07	2.23±0.09	
	Cy ₃ -Cy ₄	1.0-1.5	1.18	0.18	0.07	1.07±0.03	1.30±0.12	
Sulcus vasculosus	Length	Cy ₄	0.64-0.91	0.79	0.09	0.04	0.73±0.05	0.85±0.04
		Cy ₅	0.58-0.72	0.66	0.05	0.02	0.62*±0.02	0.69±0.01
		Cy ₆	0.99-1.11	1.06	0.04	0.02	1.03*±0.02	1.09±0.01
		Cy ₇	0.59-0.69	0.64	0.03	0.01	0.62±0.02	0.65±0.02

	Width	Cranial	Cy ₄	0.29-0.43	0.36	0.06	0.02	0.34±0.03	0.38±0.04		
			Cy ₅	0.17-0.25	0.21	0.03	0.01	0.19*±0.01	0.23±0.01		
			Cy ₆	0.18-0.28	0.23	0.03	0.01	0.20±0.01	0.25±0.02		
			Cy ₇	0.05-0.11	0.08	0.02	0.01	0.06*±0.01	0.09±0.01		
		Middle	Cy ₄	0.27-0.34	0.31	0.02	0.01	0.29±0.01	0.33±0.01		
			Cy ₅	0.10-0.16	0.13	0.02	0.01	0.12±0.01	0.14±0.02		
			Cy ₆	0.07-0.14	0.11	0.03	0.01	0.09*±0.01	0.13±0.01		
			Cy ₇	0.03-0.08	0.05	0.02	0.01	0.04±0.01	0.06±0.01		
		Caudal	Cy ₄	0.13-0.19	0.15	0.03	0.01	0.13±0.01	0.17±0.01		
			Cy ₅	0.05-0.13	0.09	0.03	0.01	0.07±0.01	0.11±0.01		
			Cy ₆	0.04-0.09	0.06	0.02	0.01	0.04±0.001	0.07±0.01		
			Cy ₇	0.03-0.08	0.05	0.02	0.01	0.04±0.01	0.05±0.01		
Cranial non-articular process	Length		Cy ₄	1.01-1.17	1.11	0.05	0.01	1.08*±0.02	1.13±0.01		
			Cy ₅	0.73-0.95	0.85	0.07	0.02	0.83±0.03	0.88±0.03		
	Width	Cranial	Cy ₄	0.28-0.52	0.39	0.08	0.02	0.36±0.03	0.41±0.04		
			Cy ₅	0.29-0.51	0.39	0.07	0.02	0.36±0.02	0.42±0.03		
		Middle	Cy ₄	0.33-0.59	0.45	0.08	0.02	0.42±0.03	0.48±0.04		
			Cy ₅	0.42-0.64	0.52	0.07	0.02	0.49±0.02	0.55±0.03		
		Caudal	Cy ₄	0.19-0.42	0.31	0.08	0.02	0.28±0.03	0.35±0.03		
			Cy ₅	0.27-0.37	0.32	0.04	0.01	0.30*±0.01	0.35±0.01		
Ventral spine	Length		Cy ₄	0.83-1.11	0.99	0.08	0.02	0.95±0.04	1.03±0.02		
			Cy ₅	1.08-1.24	1.16	0.05	0.01	1.12*±0.01	1.19±0.01		
			Cy ₆	1.10-1.29	1.20	0.05	0.02	1.18±0.02	1.23±0.02		
			Cy ₇	0.59-0.85	0.73	0.09	0.03	0.71±0.04	0.76±0.03		
	Height	Cranial	Cy ₄	0.29-0.37	0.34	0.03	0.01	0.32*±0.01	0.36±0.01		
			Cy ₅	0.31-0.54	0.41	0.07	0.02	0.38±0.03	0.44±0.03		
			Cy ₆	0.32-0.42	0.37	0.03	0.01	0.35*±0.01	0.39±0.01		
			Cy ₇	0.18-0.27	0.22	0.03	0.01	0.20*±0.01	0.24±0.01		
		Middle	Cy ₄	0.37-0.51	0.43	0.04	0.01	0.40*±0.01	0.46±0.01		
			Cy ₅	0.41-0.59	0.49	0.05	0.02	0.47±0.01	0.52±0.03		
			Cy ₆	0.30-0.49	0.40	0.06	0.02	0.38±0.02	0.43±0.02		
			Cy ₇	0.26-0.38	0.33	0.04	0.01	0.30*±0.01	0.35±0.01		
		Caudal	Cy ₄	0.37-0.46	0.42	0.03	0.01	0.40*±0.01	0.44±0.01		
			Cy ₅	0.30-0.47	0.38	0.05	0.02	0.35*±0.02	0.42±0.02		
			Cy ₆	0.31-0.45	0.38	0.04	0.01	0.36±0.01	0.40±0.02		
			Cy ₇	0.16-0.26	0.21	0.03	0.01	0.20±0.01	0.23±0.01		
		Length of dorsal spine of Cy ₄ (not bifid)				0.22-0.39	0.32	0.06	0.03	0.27*±0.03	0.37±0.01
		Height of dorsal spine of Cy ₄		Cranial	0.09-0.18	0.14	0.03	0.01	0.11±0.01	0.16±0.01	
Middle	0.20-0.29			0.25	0.03	0.01	0.22±0.02	0.27±0.01			
Caudal	0.11-0.19			0.15	0.03	0.01	0.14±0.02	0.16±0.02			
Thickness of dorsal spine of Cy ₄		Cranial	0.03-0.11	0.07	0.03	0.01	0.05±0.01	0.09±0.01			
		Middle	0.04-0.10	0.07	0.02	0.01	0.05*±0.01	0.09±0.01			
		Caudal	0.03-0.08	0.06	0.02	0.01	0.05±0.01	0.06±0.01			
Minimum distance between two cranial non-articular processes		Cy ₄	0.89-1.02	0.97	0.05	0.02	0.94±0.03	1.00±0.01			
		Cy ₅	0.28-0.40	0.35	0.05	0.02	0.31*±0.02	0.39±0.01			
Distance between cranial non-articular process and transverse process		Cy ₄	1.61-2.21	1.91	0.24	0.07	1.86±0.10	1.95±0.10			
		Cy ₅	2.15-2.34	2.24	0.06	0.02	2.20*±0.02	2.29±0.02			

Values bearing superscript (*) differ significantly in column P< 0.05

Fig.1 Ventral view of coccygeal vertebrae (Cy₁ – Cy₁₅) of adult male Blue bull (*Boselaphus tragocamelus*)

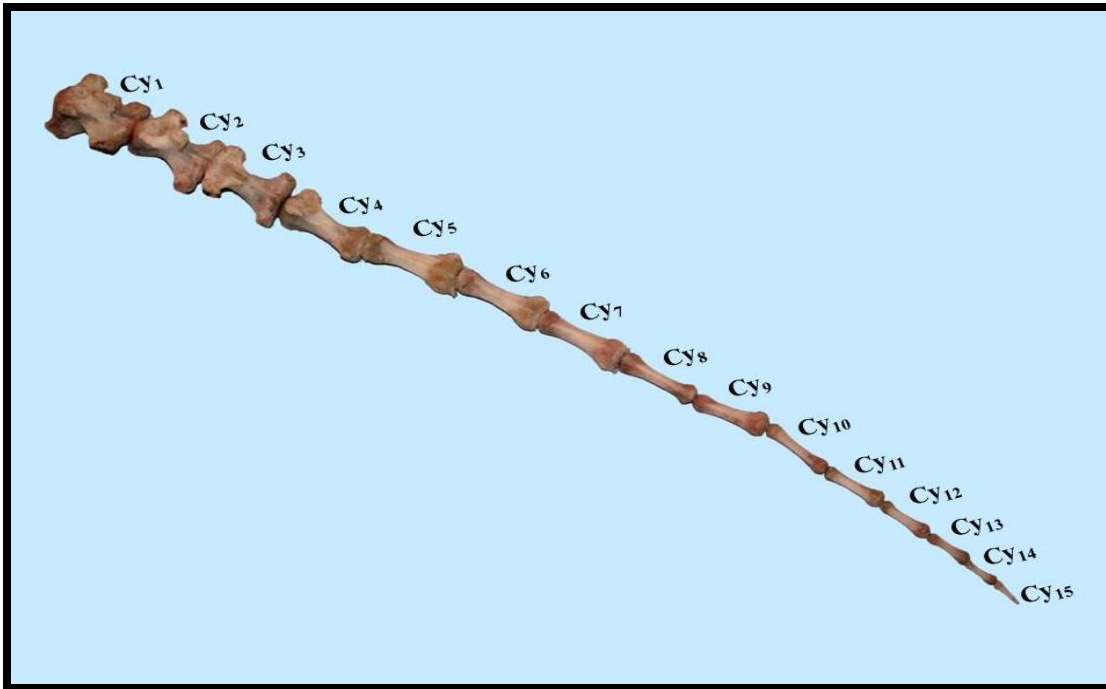


Fig.2 Dorsal view of third coccygeal vertebra of adult female Blue bull (*Boselaphus tragocamelus*) showing a) Anterior surface of body, b) Anterior non-articular process, c) Pedicle, d) Dorsal supraspinous process, e) Transverse process, f) Anterior surface of body, g) Groove, h) Laminae and i) Vertebral foramen

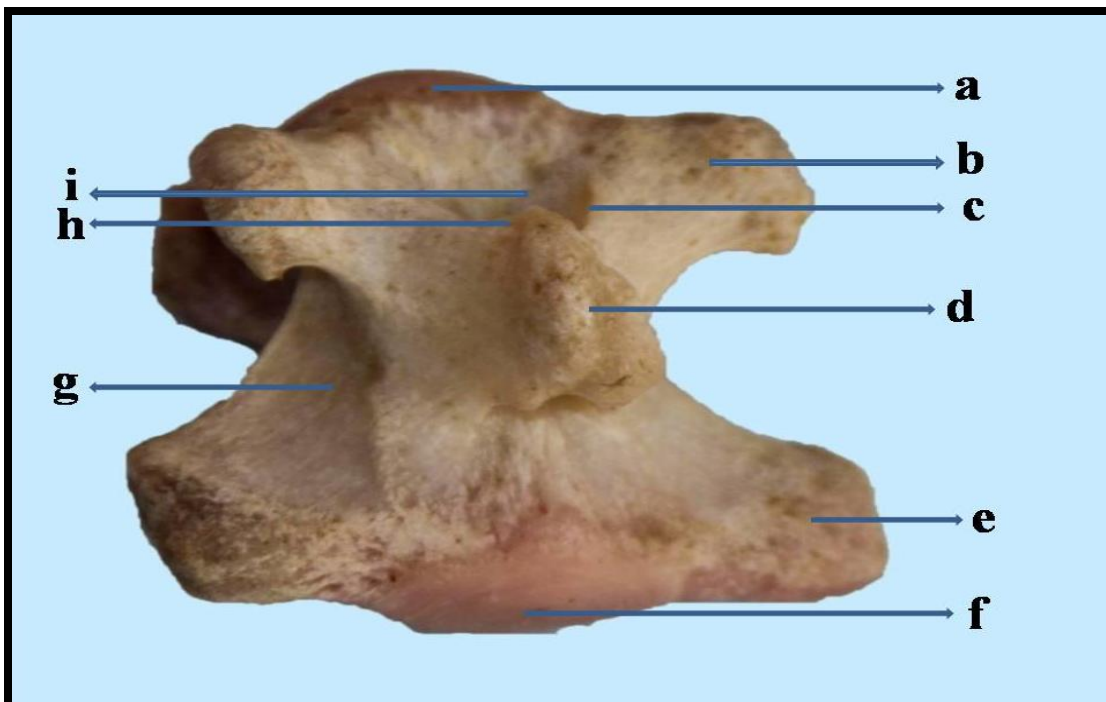


Fig.3 Ventral view of third coccygeal vertebra of adult female Blue bull (*Boselaphus tragocamelus*) showing a) Cranial non-articular process, b) Ventral spines, c) Anterior surface of body, d) Groove, e) Posterior surface of body, f) Ventral foramen, g) Sulcus vasculosus and h) Transverse process

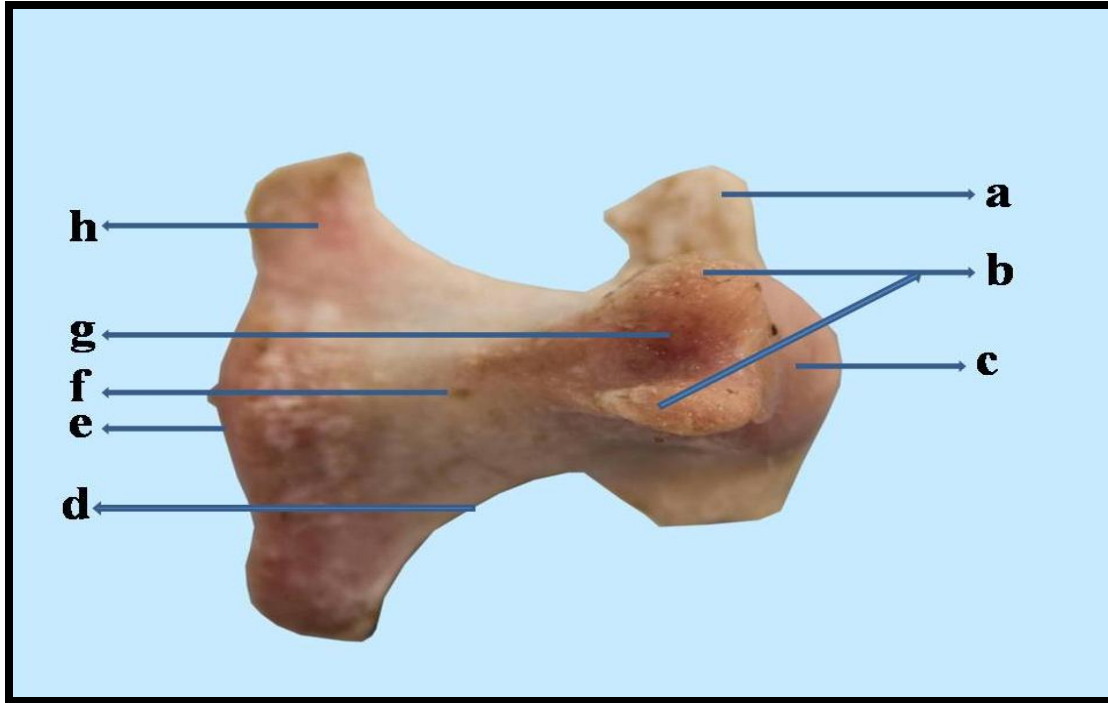
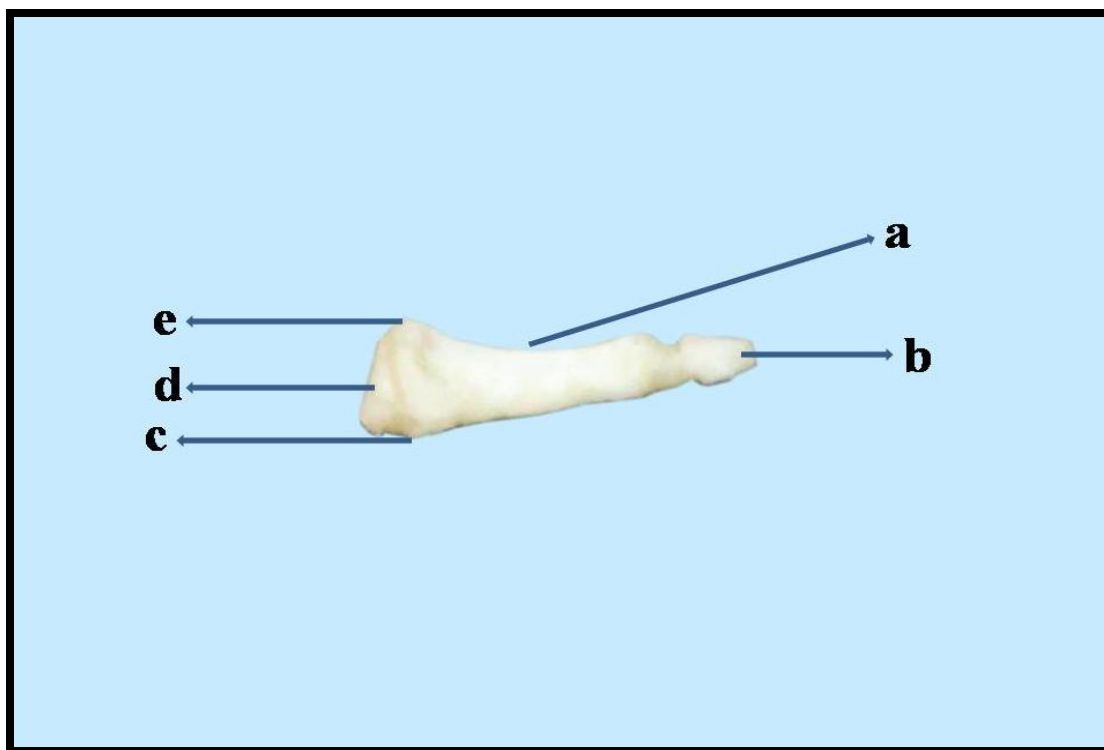


Fig.4 Ventral view of coccygeal vertebrae (Cy₂ – Cy₄) of adult male Blue bull (*Boselaphus tragocamelus*)

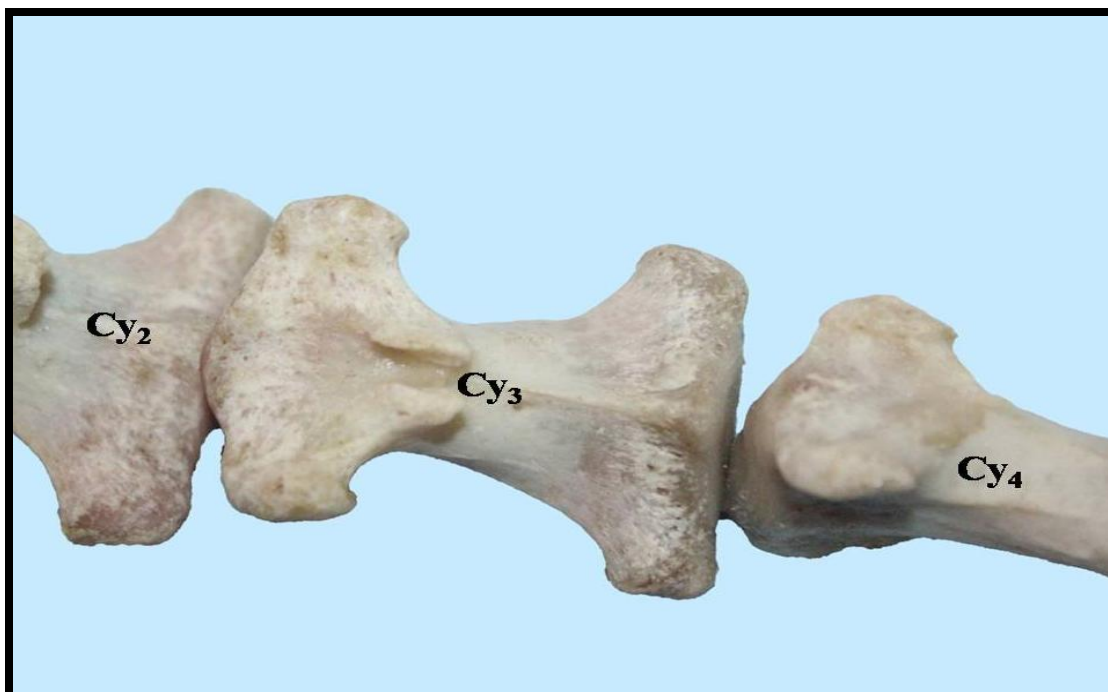

Fig.5 Ventro-lateral view of fifteenth coccygeal vertebra of adult male Blue bull (*Boselaphus tragocamelus*) showing a) Groove, b) Posterior surface of body, c) Ventral tubercle, d) Anterior surface of body and e) Dorsal tubercle



The average length of the body of Cy₁₂ was found to be 2.62±0.06 cm in adult Blue bull. Further, it was measured as 2.57±0.09 cm and 2.67±0.09 cm in females and males respectively. The average length of the body of Cy₁₃ was found to be 2.10±0.07 cm in adult Blue bull. Further, it was measured as 1.97±0.03 cm in females that was significantly lesser (P<0.05) than that of males, where it was found to be 2.23±0.09 cm. Similarly, the average length of the body of Cy₁₄ was found to be 1.60±0.07 cm in adult Blue bull. Further, it was measured as 1.47±0.09 cm in females that was significantly lesser (P<0.05) than that of males, where it was found to be 1.73±0.03 cm. The average length of the body of Cy₁₅ was found to be 1.20±0.06 cm in adult Blue bull. Further, it was measured as 1.10±0.06 cm and 1.30±0.06 cm in females and males respectively.

The average length of dorsal spine of Cy₄ was found to be 0.32±0.03 cm in adult Blue bull. Further, it was measured as 0.27±0.03 cm in females that was significantly lesser (P<0.05) than that of males, where it was found to be 0.37±0.01 cm. The average thickness of dorsal spine of Cy₄ at the cranial aspect was found to be 0.07±0.01 cm in adult Blue bull. Further, it was measured as 0.05±0.01 cm and 0.09±0.01 cm in females and males respectively. The average thickness of dorsal spine of Cy₄ at the middle was found to be 0.07±0.01 cm in adult Blue bull. Further, it was measured as 0.05±0.01 cm in females that was significantly lesser (P<0.05) than that of males, where it was found to be 0.09±0.01 cm. The average thickness of dorsal spine of Cy₄ at the caudal aspect was found to be 0.06±0.01 cm in adult Blue bull. Further, it was measured as 0.05±0.01 cm and 0.06±0.01 cm in females and males respectively. The

average height of dorsal spine of Cy₄ at the cranial aspect was found to be 0.14±0.01 cm in adult Blue bull. Further, it was measured as 0.11±0.01 cm and 0.16±0.01 cm in females and males respectively. Similarly, the average height of dorsal spine of Cy₄ at the middle was found to be 0.25±0.01 cm in adult Blue bull. Further, it was measured as 0.22±0.02 cm and 0.27±0.01 cm in females and males respectively. The average height of dorsal spine of Cy₄ at the caudal aspect was found to be 0.15±0.01 cm in adult Blue bull. Further, it was measured as 0.14±0.02 cm and 0.16±0.02 cm in females and males respectively.

The average length of transverse process of Cy₄ was found to be 0.81±0.02 cm in adult Blue bull. Further, it was measured as 0.75±0.02 cm in females that was significantly lesser (P<0.05) than that of males, where it was found to be 0.86±0.02 cm. The average length of transverse process of Cy₅ was found to be 0.67±0.02 cm in adult Blue bull. Further, it was measured as 0.63±0.03 cm and 0.71±0.03 cm in females and males respectively. Similarly, the average length of transverse process of Cy₆ was found to be 0.84±0.03 cm in adult Blue bull. Further, it was measured as 0.79±0.04 cm and 0.89±0.02 cm in females and males respectively. The average length of transverse process of Cy₇ was found to be 0.51±0.02 cm in adult Blue bull. Further, it was measured as 0.47±0.02 cm in females that was significantly lesser (P<0.05) than that of males, where it was found to be 0.55±0.01 cm. The average distance between the transverse processes of Cy₄ and Cy₅ was found to be 3.48±0.03 cm in adult Blue bull. Further, it was measured as 3.43±0.05 cm and 3.53±0.03 cm in females and males respectively. Similarly, the average distance between the transverse processes of Cy₅ and Cy₆ was found to be 3.31±0.05 cm in adult Blue bull. Further, it was measured as 3.27±0.08 cm and 3.34±0.08 cm in females

and males respectively. The average distance between the transverse processes of Cy₆ and Cy₇ was found to be 2.84±0.08 cm in adult Blue bull. Further, it was measured as 2.81±0.12 cm and 2.87±0.11 cm in females and males respectively.

The average length of cranial non-articular process of Cy₄ was found to be 1.11±0.01 cm in adult Blue bull. Further, it was measured as 1.08±0.02 cm in females that was significantly lesser (P<0.05) than that of males, where it was found to be 1.13±0.01 cm. The average length of cranial non-articular process of Cy₅ was found to be 0.85±0.02 cm in adult Blue bull. Further, it was measured as 0.83±0.03 cm and 0.88±0.03 cm in females and males respectively. The average width of cranial non-articular process at the cranial aspect of Cy₄ was found to be 0.39±0.02 cm in adult Blue bull. Further, it was measured as 0.36±0.03 cm and 0.41±0.04 cm in females and males respectively. Similarly, the average width of cranial non-articular process at the cranial aspect of Cy₅ was found to be 0.39±0.02 cm in adult Blue bull. Further, it was measured as 0.36±0.02 cm and 0.42±0.03 cm in females and males respectively. The average width of cranial non-articular process at the middle of Cy₄ was found to be 0.45±0.02 cm in adult Blue bull. Further, it was measured as 0.42±0.03 cm and 0.48±0.04 cm in females and males respectively. Similarly, the average width of cranial non-articular process at the middle of Cy₅ was found to be 0.52±0.02 cm in adult Blue bull. Further, it was measured as 0.49±0.02 cm and 0.55±0.03 cm in females and males respectively.

The average width of cranial non-articular process at the caudal aspect of Cy₄ was found to be 0.31±0.02 cm in adult Blue bull. Further, it was measured as 0.28±0.03 cm and 0.35±0.03 cm in females and males respectively. Similarly, the average width of

cranial non-articular process at the caudal aspect of Cy₅ was found to be 0.32±0.01 cm in adult Blue bull. Further, it was measured as 0.30±0.01 cm and 0.35±0.01 cm in females and males respectively. The average distance between the cranial non-articular process of Cy₄ and Cy₅ was found to be 3.17±0.04 cm in adult Blue bull. Further, it was measured as 3.14±0.05 cm and 3.20±0.06 cm in females and males respectively.

The average minimum distance between the two cranial non-articular processes of Cy₄ was found to be 0.97±0.02 cm in adult Blue bull. Further, it was measured as 0.94±0.03 cm and 1.00±0.01 cm in females and males respectively. The average minimum distance between the two cranial non-articular processes of Cy₅ was found to be 0.35±0.02 cm in adult Blue bull. Further, it was measured as 0.31±0.02 cm in females that was significantly lesser (P<0.05) than that of males, where it was found to be 0.39±0.01 cm. The average distance between the cranial non-articular process and transverse process of Cy₄ was found to be 1.91±0.07 cm in adult Blue bull. Further, it was measured as 1.86±0.10 cm and 1.95±0.10 cm in females and males respectively. The average distance between the cranial non-articular process and transverse process of Cy₅ was found to be 2.24±0.02 cm in adult Blue bull. Further, it was measured as 2.20±0.02 cm in females that was significantly lesser (P<0.05) than that of males, where it was found to be 2.29±0.02 cm.

The average length of ventral spine of Cy₄ was found to be 0.99±0.02 cm in adult Blue bull. Further, it was measured as 0.95±0.04 cm and 1.03±0.02 cm in females and males respectively. The average length of ventral spine of Cy₅ was found to be 1.16±0.01 cm in adult Blue bull. Further, it was measured as 1.12±0.01 cm in females that was significantly lesser (P<0.05) than that of

males, where it was found to be 1.19±0.01 cm. The average length of ventral spine of Cy₆ was found to be 1.20±0.02 cm in adult Blue bull. Further, it was measured as 1.18±0.02 cm and 1.23±0.02 cm in females and males respectively. Similarly, the average length of ventral spine of Cy₇ was found to be 0.73±0.03 cm in adult Blue bull. Further, it was measured as 0.71±0.04 cm and 0.76±0.03 cm in females and males respectively.

The average height of ventral spine at the cranial aspect of Cy₄ was found to be 0.34±0.01 cm in adult Blue bull. Further, it was measured as 0.32±0.01 cm in females that was significantly lesser (P<0.05) than that of males, where it was found to be 0.36±0.01 cm. The average height of ventral spine at the cranial aspect of Cy₅ was found to be 0.41±0.02 cm in adult Blue bull. Further, it was measured as 0.38±0.03 cm and 0.44±0.03 cm in females and males respectively. The average height of ventral spine at the cranial aspect of Cy₆ was found to be 0.37±0.01 cm in adult Blue bull. Further, it was measured as 0.35±0.01 cm in females that was significantly lesser (P<0.05) than that of males, where it was found to be 0.39±0.01 cm. Similarly, the average height of ventral spine at the cranial aspect of Cy₇ was found to be 0.22±0.01 cm in adult Blue bull. Further, it was measured as 0.20±0.01 cm in females that was significantly lesser (P<0.05) than that of males, where it was found to be 0.24±0.01 cm.

The average height of ventral spine at the middle of Cy₄ was found to be 0.43±0.01 cm in adult Blue bull. Further, it was measured as 0.40±0.01 cm in females that was significantly lesser (P<0.05) than that of males, where it was found to be 0.46±0.01 cm. The average height of ventral spine at the middle of Cy₅ was found to be 0.49±0.02 cm in adult Blue bull. Further, it was measured as 0.47±0.01 cm and 0.52±0.03 cm in females

and males respectively. Similarly, the average height of ventral spine at the cranial aspect of Cy₆ was found to be 0.40±0.02 cm in adult Blue bull. Further, it was measured as 0.38±0.02 cm and 0.43±0.02 cm in females and males respectively. The average height of ventral spine at the middle of Cy₇ was found to be 0.33±0.01 cm in adult Blue bull. Further, it was measured as 0.30±0.01 cm in females that was significantly lesser (P<0.05) than that of males, where it was found to be 0.35±0.01 cm. The average height of ventral spine at the caudal aspect of Cy₄ was found to be 0.42±0.01 cm in adult Blue bull. Further, it was measured as 0.40±0.01 cm in females that was significantly lesser (P<0.05) than that of males, where it was found to be 0.44±0.01 cm. Similarly, the average height of ventral spine at the caudal aspect of Cy₅ was found to be 0.38±0.02 cm in adult Blue bull. Further, it was measured as 0.35±0.02 cm in females that was significantly lesser (P<0.05) than that of males, where it was found to be 0.42±0.02 cm. The average height of ventral spine at the cranial aspect of Cy₆ was found to be 0.38±0.01 cm in adult Blue bull. Further, it was measured as 0.36±0.01 cm and 0.40±0.02 cm in females and males respectively. Similarly, the average height of ventral spine at the cranial aspect of Cy₇ was found to be 0.21±0.01 cm in adult Blue bull. Further, it was measured as 0.20±0.01 cm and 0.23±0.01 cm in females and males respectively.

The average distance between the ventral spines of Cy₄ and Cy₅ was found to be 3.17±0.02 cm in adult Blue bull. Further, it was measured as 3.14±0.02 cm and 3.21±0.02 cm in females and males respectively. Similarly, the average distance between the ventral spines of Cy₅ and Cy₆ was found to be 3.21±0.02 cm in adult Blue bull. Further, it was measured as 3.17±0.03 cm and 3.25±0.03 cm in females and males respectively. The average distance between the ventral spines of Cy₆ and Cy₇ was found to be 3.21±0.04 cm in

adult Blue bull. Further, it was measured as 3.16±0.04 cm and 3.26±0.05 cm in females and males respectively. The average length of sulcus vasculosus of Cy₄ was found to be 0.79±0.04 cm in adult Blue bull (Diagram 51). Further, it was measured as 0.73±0.05 cm and 0.85±0.04 cm in females and males respectively. The average length of sulcus vasculosus of Cy₅ was found to be 0.66±0.02 cm in adult Blue bull. Further, it was measured as 0.62±0.02 cm in females that was significantly lesser (P<0.05) than that of males, where it was found to be 0.69±0.01 cm. Similarly, the average length of sulcus vasculosus of Cy₆ was found to be 1.06±0.02 cm in adult Blue bull. Further, it was measured as 1.03±0.02 cm in females that was significantly lesser (P<0.05) than that of males, where it was found to be 1.09±0.01 cm. The average length of sulcus vasculosus of Cy₇ was found to be 0.64±0.01 cm in adult Blue bull. Further, it was measured as 0.62±0.02 cm and 0.65±0.02 cm in females and males respectively.

The average width of sulcus vasculosus of Cy₄ at the cranial aspect was found to be 0.36±0.02 cm in adult Blue bull. Further, it was measured as 0.34±0.03 cm and 0.38±0.04 cm in females and males respectively. The average width of sulcus vasculosus of Cy₅ at the cranial aspect was found to be 0.21±0.01 cm in adult Blue bull. Further, it was measured as 0.19±0.01 cm in females that was significantly lesser (P<0.05) than that of males, where it was found to be 0.23±0.01 cm. The average width of sulcus vasculosus of Cy₆ at the cranial aspect was found to be 0.23±0.01 cm in adult Blue bull.

Further, it was measured as 0.20±0.01 cm and 0.25±0.02 cm in females and males respectively. The average width of sulcus vasculosus of Cy₇ at the cranial aspect was found to be 0.08±0.02 cm in adult Blue bull. Further, it was measured as 0.06±0.01 cm in

females that was significantly lesser ($P < 0.05$) than that of males, where it was found to be 0.09 ± 0.01 cm.

The average width of sulcus vasculosus of Cy_4 at the middle was found to be 0.31 ± 0.01 cm in adult Blue bull. Further, it was measured as 0.29 ± 0.01 cm and 0.33 ± 0.01 cm in females and males respectively. Similarly, the average width of sulcus vasculosus of Cy_5 at the middle was found to be 0.13 ± 0.01 cm in adult Blue bull. Further, it was measured as 0.12 ± 0.01 cm and 0.14 ± 0.02 cm in females and males respectively. The average width of sulcus vasculosus of Cy_6 at the middle was found to be 0.11 ± 0.01 cm in adult Blue bull. Further, it was measured as 0.09 ± 0.01 cm in females that was significantly lesser ($P < 0.05$) than that of males, where it was found to be 0.13 ± 0.01 cm. The average width of sulcus vasculosus of Cy_7 at the middle aspect was found to be 0.05 ± 0.01 cm in adult Blue bull. Further, it was measured as 0.04 ± 0.01 cm and 0.06 ± 0.01 cm in females and males respectively.

The average width of sulcus vasculosus of Cy_4 at the caudal aspect was found to be 0.15 ± 0.01 cm in adult Blue bull. Further, it was measured as 0.13 ± 0.01 cm and 0.17 ± 0.01 cm in females and males respectively. Similarly, the average width of sulcus vasculosus of Cy_5 at the caudal aspect was found to be 0.09 ± 0.01 cm in adult Blue bull. Further, it was measured as 0.07 ± 0.01 cm and 0.11 ± 0.01 cm in females and males respectively. The average width of sulcus vasculosus of Cy_6 at the caudal aspect was found to be 0.06 ± 0.01 cm in adult Blue bull. Further, it was measured as 0.04 ± 0.001 cm and 0.07 ± 0.01 cm in females and males respectively. Similarly, the average width of sulcus vasculosus of Cy_7 at the middle aspect was found to be 0.05 ± 0.01 cm in adult Blue bull. Further, it was measured as 0.04 ± 0.01 cm and 0.05 ± 0.01 cm in females and males

respectively. The average distance between the sulcus vasculosus of Cy_4 and Cy_5 was found to be 3.10 ± 0.07 cm in adult Blue bull. Further, it was measured as 3.00 ± 0.06 cm and 3.20 ± 0.12 cm in females and males respectively. Similarly, the average distance between the sulcus vasculosus of Cy_5 and Cy_6 was found to be 3.10 ± 0.06 cm in adult Blue bull. Further, it was measured as 3.00 ± 0.06 cm and 3.20 ± 0.06 cm in females and males respectively. The average distance between the sulcus vasculosus of Cy_6 and Cy_7 was found to be 3.05 ± 0.07 cm in adult Blue bull. Further, it was measured as 2.97 ± 0.09 cm and 3.13 ± 0.09 cm in females and males respectively (Table 2).

The arches, dorsal spine, ventral spine, transverse process and cranial non-articular process were found in Cy_3 - Cy_6 in Blue bull and there after they reduced in both the sexes. The fifteenth coccygeal vertebra was represented by cylindrical body with reduced processes. Further, various parameters of the third to fifteenth coccygeal vertebrae like average length and width of body, average length, height and thickness of dorsal spine, average length and width of transverse process, cranial non-articular process and sulcus vasculosus, average length and height of ventral spine, average length of vertebral canal, average cranial and caudal diameters of vertebral canal showed characteristic sexual variations in the Blue bull.

There is no previous information on these parameters in the third to fifteenth coccygeal vertebrae of Blue bull, nor in any other domestic animals with which comparisons could be made. We therefore believe that the data presented above would form a baseline for further work especially comparability and compatibility are now desirable traits as efforts are geared up towards massive improvement in the livestock sector of the international economy.

Acknowledgements

The authors are grateful to the Dean, CVASc., GBPUA&T, Pantnagar, Uttarakhand and Ministry of Environment of Forests (MoEF), New Delhi and Jodhpur Zoo, Rajasthan, India for providing facilities and support for carrying out research on the bones of Blue bull. Funding was provided by Department of Science and Technology, New Delhi and Indian Council of Agricultural research, New Delhi, India as Ph.D. grant (DST-INSPIRE Fellowship and ICAR-SRF (PGS)) to the first author.

References

- Bagchi, S., Goyal, S.P. and Shankar, K. 2004. Herbivore density and biomass in a semi-arid tropical dry deciduous forest of western India. *Journal of Tropical Ecology*. 20(4): 475-478.
- Breland, O.P. 1943. *Manual of comparative anatomy*, McGraw-Hill Book Company, Inc, New York and London, pp 146-151.
- Dyce, K.M., Sack, W.O. and Wensing C.J.G. 2006. *Text Book of Veterinary Anatomy*, Saunders Elsevier, 4th ed., pp 35 – 41.
- Frandsen, B.S. and Spurgeon, T.L. 1992. *Anatomy and physiology of farm animals*. Lea and Febiger, Philadelphia. 5th ed. pp 64-68.
- Getty, R., Sisson, S. and Grossman, J.D. 1930. *The Anatomy of the Domestic Animals*. W.B. Saunders Comp., Philadelphia. 2nd ed. (Vol. 1), pp 25-27, 33-45, 125-130.
- Konig, H.E. and Liebich, H.G. 2005. *Veterinary Anatomy of Domestic Animals*, 3rd Edn, Schattauer, Stuttgart, Germany. pp 49-104, 145-160, 215-236.
- Levine, J.M., Levine, G.J., Hoffman, A.G., Mez, J. and Bratton, G.R. 2007. *Comparative Anatomy of the Horse, Ox and Dog: The Vertebral Column and Peripheral Nerves*. CE article-1, pp 279-281.
- Meena, V. K. 2012. Gross studies on the bones of vertebral column in chital (*Axis axis*). Masters' thesis submitted to the Rajasthan University of Veterinary and Animal Sciences, Bikaner.
- Miller, M.E., Christensen, G.C. and Evans, H.E. 1964. *Anatomy of the Dog*. WB Saunders Company, Philadelphia, USA, pp 51- 61.
- Ozkan, Z.E. 2007. Macro-anatomical investigations on the skeletons of Mole-rat (*Spalax leucodon nordmann*) III. Skeleton axiale. *Vet. Archiv.*, 77: 281-289.
- Raghavan, D. 1964. *Anatomy of Ox*. Indian Council of Agricultural Research, New Delhi, pp 17-38.
- Rajani, C.V. and Chungath, J.J. 2012. Studies on the Lumbar, Sacral and Coccygeal Vertebrae of Indian Muntjac (*Muntiacus muntjak*). *Indian Journal of Veterinary Anatomy*. 24 (2): 78-79.
- Sathapathy, S., Dhote, B.S., Singh, I., Mahanta, D. and Tamil selvan, S. 2017. Gross and morphometrical studies on the sacrum of blue bull (*Boselaphus tragocamelus*). *Journal of Entomology and Zoology Studies*. 5(6): 1591-1597.
- Sathapathy, S., B.S. Dhote, M. Mrigesh, D. Mahanta and Tamil Selvan, S. 2018a. Gross and Morphometrical Studies on the Sternum of Blue Bull (*Boselaphus tragocamelus*). *Int. J. Curr. Microbiol. App. Sci.* 7(01): 136-145. doi: <https://doi.org/10.20546/ijcmas.2018.701.015>.
- Sathapathy, S., Dhote, B.S., Singh, I., Mahanta, D. and Mrigesh, M. and Joshi, S. K. 2018b. Gross Anatomical and Sex wise Biometrical Studies on the Atlas and Axis of Blue bull (*Boselaphus tragocamelus*). *Journal of Animal*

- Research*. 8(1): 137-147. DOI: 10.30954/2277-940X.2018.00150.22.
- Sathapathy, S., Dhote, B.S., Singh, I., Mahanta, D., Tamil selvan, S. and Mrigesh, M. 2018c. Gross morphometrical study on the atypical (6th and 7th) cervical vertebrae of Blue bull (*Boselaphus tragocamelus*) with special reference to sexual dimorphism. *International Journal of Livestock Research*. 8(9): 192-201. DOI 10.5455/ijlr.20180207043008.
- Smuts, M.S. and Bezuidenhout, A.J. 1987. *Anatomy of Dromedary*, Oxford Science Publications, pp 9-20.
- Snedecor, G.W. and Cochran, W.G. 1994. *Statistical Methods*. 8th edn. Iowa State University Press, Ames, Iowa, USA.
- Yilmaz, S. 1998. Macro-Anatomical investigations on the skeletons of porcupine (*Hystrix cristita*). *Anatomia Histologia Embryologia*, 27: 293-296.
- Yilmaz, S., Dinç, G. and Toprak, B. 2000. Macro-anatomical investigations on skeletons of otter (*Lutra lutra*) III. Skeleton axiale. *Vet. Arhiv.*, 70: 191-198.

How to cite this article:

Sathapathy, S., B.S. Dhote, D. Mahanta, S. Tamilselvan, I. Singh, M. Mrigesh and Joshi, S.K. 2018. Gross Morphological and Sex wise Morphometrical Studies on the Third to Fifteenth Coccygeal Vertebrae of Blue Bull (*Boselaphus tragocamelus*). *Int.J.Curr.Microbiol.App.Sci*. 7(11): 411-428. doi: <https://doi.org/10.20546/ijcmas.2018.711.049>