

Original Research Article

<https://doi.org/10.20546/ijcmas.2017.605.311>

Rapidly Growing Mycobacteria an Often Overlooked Cause of Surgical Site Infections

Priyanka Biswas, A. Gupta* and R. Sriram

Department of Microbiology Diamond jubilee block Armed Forces Medical College,
Pune 411040, India

*Corresponding author

ABSTRACT

Keywords

Mycobacteria,
Patient
Morbidity,
Surgical site
infections
(SSIs)

Article Info

Accepted:
26 April 2017
Available Online:
10 May 2017

Surgical site infections are a common cause of Health care associated infections and result in increased patient morbidity. Rapidly growing Mycobacteria are increasingly being reported as the causative organism in these infections. This study was carried out to identify and phenotypically characterise SSIs due to these organisms at a tertiary care centre. Antibiotic susceptibility was ascertained using microbroth dilution. Strict Infection control measures were then put into place to prevent these infections. Infections due to these organisms require prolonged treatment and occasionally even surgery. It is important to have a high index of suspicion to be able to recognise these infections and to identify them in a clinical microbiology laboratory.

Introduction

Non Tuberculous Mycobacteria (NTM) are free-living ubiquitous organisms, which despite being known since the time of Robert Koch, have often been dismissed as contaminants and saprophytes (Collins *et al.*, 1984). Their reservoirs include water, soil, animals and dairy products (Collins *et al.*, 1984; Wu *et al.*, 2009; Duarte *et al.*, 2009).

However, they are also known to colonise medical equipment such as endoscopes and surgical solutions (Wu *et al.*, 2009). Based on the Runyoun classification, NTM are classified as photochromogens, scotochromogens, non photochromogens and

rapid growers (Han *et al.*, 2007). The mycobacteria classified as rapid growers are characterised by their ability to grow on solid media in less than 7 days (Chaudhari *et al.*, 2010). The clinical significance of Rapidly Growing Mycobacteria (RGM) has only recently been appreciated with increasing number of outbreaks, pseudo outbreaks and cases of health care associated infections being attributed to them (Wolinsky *et al.*, 1968). In almost all cases of nosocomial infections caused by this group of microorganisms, failure of adherence to sterilisation processes of surgical instruments, medical devices or solutions was noticed.

Infections due to RGM are associated with significant morbidity in patients recovering from surgeries. The objective of this study was to report a series of 110 cases who had undergone open or laparoscopic surgery and presented with symptoms and signs of surgical site infection (SSI).

Materials and Methods

Pus swabs, Fine Needle Aspirates and tissue biopsies from a total of 110 patients of surgical site infections were analysed in the microbiology laboratory. These patients had undergone various surgeries like herniorrhaphy, cholecystectomy, appendicectomy and gastrectomy in the period extending from November 2012 to April 2013. Gram, Ziehl Neelsen (ZN) and lactophenol cotton blue (LCB) stains were done to rule out bacterial, mycobacterial and fungal causes. Specimens were cultured on Blood agar, MacConkey agar, Sabouraud agar and Lowenstein-Jensen media (LJ).

Species identification was done according to rate of growth on LJ media, growth on MacConkey agar, nitrate reduction, citrate utilisation, urea hydrolysis, Cefoxitin and Polymyxin B sensitivities (Table 1). Antibiotic susceptibility testing (ABST) was done using microbroth dilution for the following antibiotics-Amikacin, Linezolid, Imipenem, Ciprofloxacin, Clarithromycin, Polymyxin B and Cefoxitin. Interpretation of the ABST was done using CLSI guidelines 2014. The various details of the patients in the form of age, sex, date of surgery, date of presentation of symptoms and type of surgery was collected and analysed. Follow up of the patients was done to see for resolution of symptoms.

Results and Discussion

Maximum cases comprised those who underwent laparoscopic surgeries. Amongst

the 110 cases, 76 were male and 34 were female patients (Fig. 1). Post operatively all the patients had healthy wounds and suture removal was done on 7th to 10th day post op. The time of presentation after the date of surgery varied from a minimum of seven days to a maximum of 56 days with a mean of 23 days. The patients presented with nodular cutaneous lesions and abscesses at incision site which later progressed to chronic discharging sinus (Fig. 2). The presenting complaints were of mild discomfort or pain at the operated site. Mild erythema and induration around the operated site with serosanguinous discharge was present. There was no history of fever or other constitutional symptoms. Routine blood counts were normal.

Gram stain showed no organisms. LCB stain did not show any fungal elements. ZN stain demonstrated acid fast bacilli in 69 isolates and was negative in 41 isolates. All the 110 isolates grew on LJ media as small non-pigmented white colonies in (2-3) days, repeat ZN staining was positive (Fig. 3). 80 isolates grew on MacConkey agar as magenta coloured colonies after incubation for 24-48hrs. Species identification could only be done for 87 isolates. Of these 87 isolates, *M. abscessus* was the predominant isolate constituting 61(70%) of the isolates, followed by *M. fortuitum* with 19(22%) isolates and 7(8%) were *M. chelonae* (Fig. 4).

Majority of the isolates showed sensitivity to Imipenem, Linezolid, Amikacin and Ciprofloxacin, however considerable resistance was seen among the isolates to macrolides.

The specimens were reported as surgical site infections due to RGM. A course of antibiotics was started according to the sensitivity pattern. The patients were on regular follow up in the OPD, 73 of cases responded to the treatment with resolution of

symptoms. The remaining required surgery in the form of mesh removal and surgical debridement followed by prolonged treatment.

Health care-associated infections are defined as infections occurring in patients during their care which was not present or incubating at the time of admission into the health care facility. They are the most frequent adverse event in health-care delivery globally.

Surgical site infections (SSIs) are a major cause of these infections. A SSI is defined as an infection that occurs after surgery in whichever part of the body the surgery has taken place. The severity of these infections can vary from minor superficial infections involving the skin only to others which are more serious and involve deeper tissues, organs, or implants.

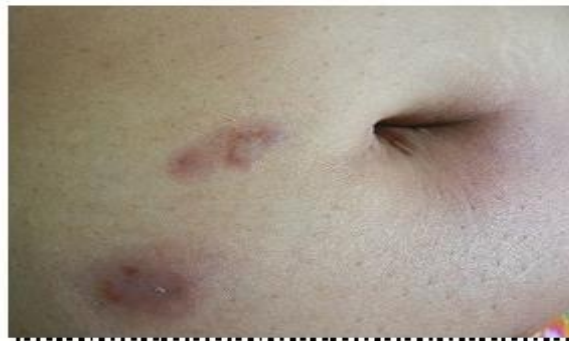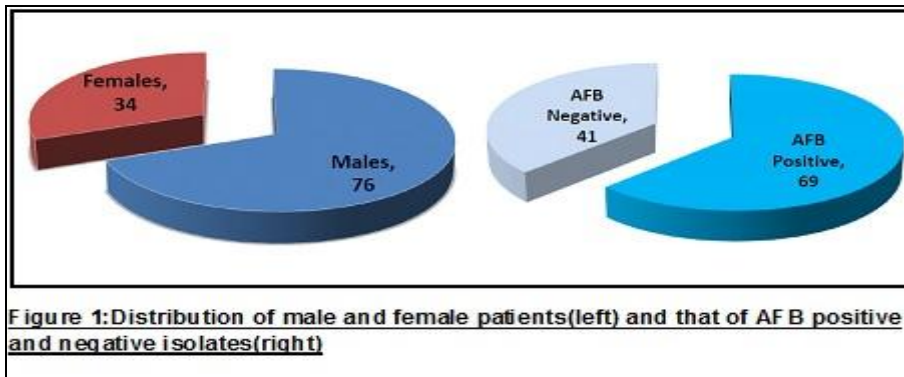


Figure 2: Erythema and abscess at the operated site

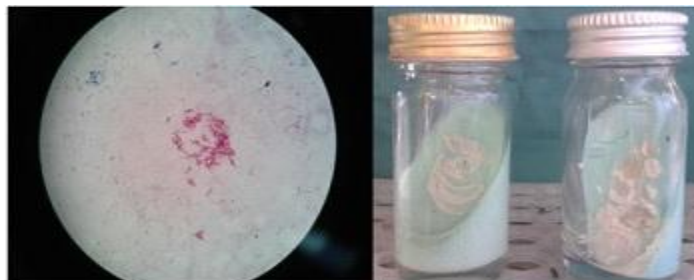


Figure 3: Ziehl Neelsen staining showing acid fast bacilli(left) and Growth on Lowenstein Jensen media(right)

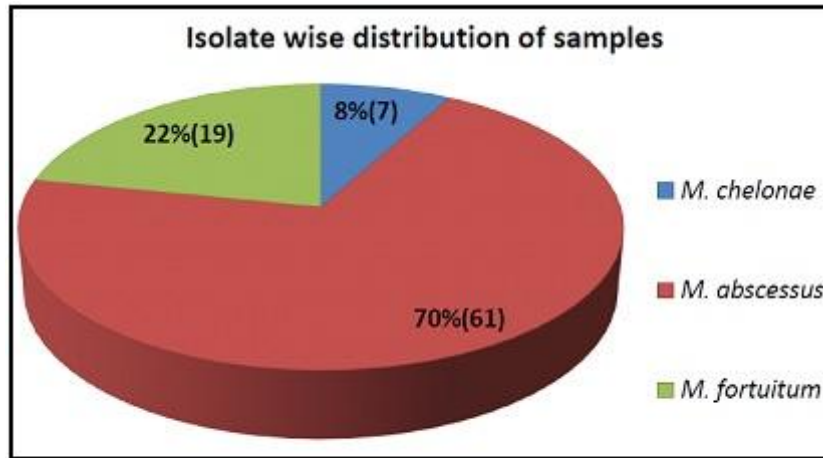


Figure4: The distribution of the different species of rapidly growing *Mycobacteria* from the total 87 isolates speciated

Tests for Identification	Isolates		
	<i>M. fortuitum</i>	<i>M. chelonae</i>	<i>M. abscessus</i>
Rate of growth	<7 days	<7 days	<7 days
Growth on MacConkey at 37°C	+	+	+
Nitrate reduction	+	-	-
Citrate utilisation	-	+	-
Susceptibility to Polymyxin B	=10mm	No zone of inhibition	No zone of inhibition
Susceptibility to Cefoxitin	Resistant	Resistant	Partial/complete zone of inhibition

Table 1: Phenotypic identification of rapidly growing *Mycobacteria*

The Center for Disease Control and Prevention (CDC) has identified three different types of SSI. These are superficial incisional SSIs, deep incisional SSIs and organ/space SSIs. Surgical site infections result in increasing costs in the form of prolonged hospitalization and therapeutic antibiotic treatment. Other costs include additional diagnostic tests and at times even another surgery.

The common pathogens isolated from these infections include *Staphylococcus aureus*, coagulase negative staphylococcus, gram

negative bacilli, enterococci and anaerobes. Many hospitals do not have the microbiological facilities for diagnosing infections caused by mycobacteria though various reports have emerged of these bacteria causing SSIs (Collins *et al.*, 1984; Duarte *et al.*, 2009; Lahiri *et al.*, 2009).

Infections due to RGM are on the rise, the problem compounded by the fact that they are resistant to commonly used disinfectants (Collins *et al.*, 1984; Duarte *et al.*, 2009; Kothavade *et al.*, 2013). These bacteria have

predilection for causing infections of the dermis and subcutaneous area. They are transmitted by aerosol, dust, contaminated tap water, water distribution pipes, sink faucets, medical devices and most importantly, erroneous sterilisation of laparoscopic instruments. *M. fortuitum*, *M. chelonae* and *M. abscessus* are responsible for majority of infections due to RGM (Lahiri *et al.*, 2009; Kothavade *et al.*, 2013), which may range from multiple lesions post-surgery to sternal wound infection and endocarditis following cardiac surgery (Phillips *et al.*, 2001). Delayed wound healing, chronicity of infection and prolonged course of expensive antibiotics, makes RGM an important cause of serious nosocomial infections (Chauhan *et al.*, 2007).

Wound infections due to RGM take some time to make their clinical appearance, when the operation scar breaks down and a non-healing superficial ulcer develops with discharging sinus. A high index of suspicion is needed for considering RGM as etiological agents, as the clinical symptoms are often non-specific and unless suspected, these agents as causes of non-healing wounds may often be missed (Regnier *et al.*, 2009). Therefore any chronic cutaneous lesion after a medical procedure which fails to resolve with an empiric trial of antibiotics should evoke the possibility of infection due to RGM1 ().

In our study, efforts to culture RGM from various specimens such as tap water in operation theatre (OT), sink faucets, air conditioning vents, glutaraldehyde solution used for disinfection of laparoscopes, wet swabs from laparoscope, surgical tray and the various OT instruments were made, but the pathogen could not be cultured.

Most of the previous studies have reported infections due to RGM after laparoscopic surgery. This could be attributed to the layer of insulation present on the laparoscopic instruments which renders them unfit for autoclaving unlike the instruments used in open surgery (Vijayaraghavan *et al.*, 2006). Cleaning is a very important step prior to disinfection and

if not cleaned properly, deposits of blood and charred tissue may collect in the joints of the instrument. These uncleaned surfaces then become the hub for endospores, which then get transferred to the subcutaneous tissue during the surgical process, and later germinate, resulting in SSI3. Studies also suggest that immersing laparoscopes in 2-2.5% glutaraldehyde solution for 20 min achieves just disinfection but not sterilisation3. Such glutaraldehyde treated laparoscopes are then often cleaned with boiled water, which could itself be a source of RGM.

Majority of the isolates obtained in our study were susceptible to the commonly recommended antibiotics for RGM infections like Imipenem, Linezolid, Amikacin and Ciprofloxacin, however resistance was seen among the isolates to macrolides. This is a finding which has been seen in other studies too4.

The recommendations to prevent SSI are use of gloves by the staff carrying laparoscopic disinfection, thorough cleaning of the instrument and removal of all detachable parts prior to disinfection, use of higher concentrations of glutaraldehyde (3.4%) disinfectant, keeping a count of the glutaraldehyde use cycles and use of autoclaved water for disinfections.

In conclusion, rapidly growing mycobacteria are increasingly being implicated as a cause of surgical site infections. These infections are difficult to diagnose and can result in prolonged morbidity. The medical treatment of these infections also tends to be prolonged and requires the use of multi drug antibiotic therapy and sometimes even surgical intervention.

The RGM should be considered in the list of etiological agents for all cases of surgical site infections. Strict infection control practices must be followed to prevent these infections and careful surveillance must be used to identify any potential outbreaks (Phillips *et al.*, 2001; Broda *et al.*, 2013).

References

- Broda, A., Jebbari, H., Beaton, K., *et al.* 2013. Comparative drug resistance of *Mycobacterium Abscessus* and *M. chelonae* isolates from patients with and without cystic fibrosis in the United Kingdom. *J. Clin. Microbiol.*, 51(1): 217-223.
- Chaudhari, S., Sarkar, D., Mukherji, R. 2010. Diagnosis and management of atypical mycobacterial infection after laparoscopic surgery. *Indian J. Surg.*, 72(6): 438-442.
- Chauhan, A., Gupta, A.K., Satyanarayan, S., *et al.* 2007. A case of nosocomial atypical mycobacterial infection. *MJAFI*, 63: 201-202.
- Collins, C.H., Grange, J.M., Yates, M.D. 1984. Mycobacteria in water. *J. Appl. Bacteriol.*, 57: 193-211.
- Duarte, R.S., Lourenco, M.C.S., Fonseca, L.S., *et al.* 2009. Epidemic of postsurgical infections caused by *Mycobacterium massiliense*. *J. Clin. Microbiol.*, 47(7): 2149-2155.
- Han, X.Y., De, I., Jacobson, K.L. 2007. Rapidly growing mycobacteria: Clinical and microbiologic studies of 115 cases. *Am. J. Clin. Pathol.*, 128(4): 612-621.
- Kothavade, R.J., Dhurat, R.S., Mishra, S.N. 2013. Clinical and laboratory aspects of the diagnosis and management of cutaneous and subcutaneous infections caused by rapidly growing mycobacteria. *Eur. J. Clin. Microbiol. Infect. Dis.*, 32: 161-188.
- Lahiri, K.K., Jena J, Pannicker KK. Mycobacterium fortuitum infections in surgical wounds. *MJAFI*, 65: 91-92.
- Phillips, M.S., Reyn, F.V. 2001. Nosocomial infections due to Nontuberculous Mycobacteria. *J. Clin. Infect. Dis.*, 33: 1363-1374.
- Regnier, S., Cambau, E., Meningaud, J.P. *et al.* 2009. Clinical management of rapidly growing mycobacterial cutaneous infections in patients after mesotherapy. *J. Clin. Infect. Dis.*, 49: 1358-1364.
- Vijayaraghavan, R., Chandrashekhar, R., Sujatha, Y., *et al.* 2006. Hospital outbreak of atypical mycobacterial infection of port sites after laparoscopic surgery. *J. Hosp. Infect.*, 64(4): 344-347.
- Wolinsky, E., Ryneerson, T.K. 1968. Mycobacteria in soil and their relation to disease-associated strains. *Am. Rev. Respir. Dis.*, 97(6P1): 1032-1037.
- Wu, T.S., Lu, C.C., Lai, H.C. 2009. Current situations on identification of Non tuberculous Mycobacteria. *J. Biomed. Lab. Sci.*, 21(1): 1-4.

How to cite this article:

Priyanka Biswas, A. Gupta and Sriram, R. 2017. Rapidly Growing *Mycobacteria* An often Overlooked Cause of Surgical Site Infections. *Int.J.Curr.Microbiol.App.Sci.* 6(5): 2777-2782. doi: <https://doi.org/10.20546/ijcmas.2017.605.311>