

Case Study

<https://doi.org/10.20546/ijcmas.2017.605.069>

Immune Mediated Haemolytic Anaemia Secondary to Sheathed Microfilaria – A Case Report

M. Ashwini* and Usha Narayana Pillai

Department of Veterinary Clinical Medicine, College of Veterinary and Animal Sciences, Mannuthy, India

*Corresponding author

ABSTRACT

Keywords

Sheathed microfilaria;
Brugia spp;
Immune mediated haemolytic anaemia (IMHA);
Coombs' test.

Article Info

Accepted:
04 April 2017
Available Online:
10 May 2017

A one year old female Labrador dog was presented to University Veterinary Hospital Kokkalai, with a history of anorexia, weakness, blood in urine and faeces. On physical examination mucous membranes were pale icteric, fever (105.3⁰F), tachypnoea was noticed. Abdominal palpation revealed splenomegaly which was confirmed by ultrasonography. Haematological examination revealed leucocytosis, severe macrocytic hypochromic anaemia (VPRC-9.4%) and thrombocytopenia. Wet film was positive for microfilaria and confirmed as *brugiaspp* on Giemsa staining of thick blood smear. Leptospirosis was ruled out by MAT. Biochemical studies showed hyperglobulinemia, elevated ALT and indirect bilirubin. The blood was positive for saline agglutination test and further antiglobulin test was carried out at 37⁰C using VMRD polyvalent Coombs' reagent which was positive at 1:32 dilution. Treatment was initiated with a dexamethasone @ 0.5 mg/kg IV for 7 days, then tapered to 0.25 mg/kg for 7 days and 0.125 mg/kg for next 7 days PO. The pet was transfused with 250 ml of whole blood on the day of admission and supportive therapy with amoxicillin-clavulanic acid 600mg IV (14 days), levamisole @ 10mg/kg for 10 days, pantoprazole and haematinics were given. The pet made an uneventful recovery.

Introduction

Immune-mediated hemolytic anemia (IMHA) is considered as one of the most common immune-haematological disorders in dogs in which antibodies are produced against the body's erythrocytes (Klag *et al.*, 1993). The condition can occur as primary/ idiopathic and secondary forms. Primary IMHA is not associated with any known existing cause, while secondary IMHA is usually associated with various etiologies such as infectious diseases, drugs, or neoplasia (Pedersen, 1999). Various blood parasites such as *Anaplasmaspp*, *Ancylostomacanicum*,

Babesiacanis, *Babesiagibsoni*, *Dirofilariaimmitis* (Heart worm), *Ehrlichia* spp and many diseases such as histoplasmosis, leishmaniasis, leptospirosis, mycoplasmosis had been implicated as the cause for secondary IMHA in dogs (Archer and Mackin, 2013). The current paper describes a case of IMHA, associated with sheathed microfilariae.

Case Report and Method

One year old Labrador was presented with the signs of anorexia, weakness, blood in urine

and faeces. On physical examination pale icteric mucous membrane (Fig 1), fever (105.3⁰F), tachypnoea was noticed. Splenomegaly was noted on abdominal palpation. Routine haematology and serum biochemical analysis is presented in table 1 and 2 respectively. On the day of presentation the dog was severely anaemic (macrocytic hypochromic) with high leucocyte count and thrombocytopenia. Differential leucocyte count revealed lymphocytosis, monocytosis and granulocytosis. Serum biochemistry analysis revealed hyperglobulinemia, hyperbilirubinemia, high alanine amino transferase and alkaline phosphatase levels.

Routine clinical examinations such as wet film, blood smear was stained with Giemsa' examination was done. Serum was checked for MAT to rule out leptospirosis. Severe acute anaemia prompted for performing saline agglutination test which was positive (Fig 2). Later Coombs' test was performed at 37⁰C using VMRD canine polyvalent Coombs' reagent (Goat origin anti canine IgG, IgM and C₃) to confirm IMHA. The test was positive at 1:32 titer (Fig 3). Wet film was positive for moving haemoparasite suggestive of microfilariae. On examination of Giemsa stained blood smear the microfilaria was confirmed as sheathed microfilaria (Fig 4) and no other haemoparasite could be detected. But spherocytosis (Fig 4) was evident on the blood smear. Immune mediated haemolytic anaemia secondary to sheathed microfilariae was diagnosed on the second day.

On the day of presentation the animal was transfused with 250ml of whole blood from a healthy donor dog and amoxicillin-clavulanic acid 600mg IV. The treatment was initiated for IMHA and microfilariosis with dexamethasone @ 0.5 mg/kg IV for 7 days and levamisole @ 10mg/kg PO for 10 days respectively. Dexamethasone was later

tapered 0.25 mg/kg for 7 days, subsequently to 0.125 mg/kg for next 7 days PO. Antibiotics were continued for 14 days.

Results and Discussion

The dog made an uneventful recovery after the treatment. Wet film examination and saline agglutination were repeated on day 14 and 21 and was found to be negative. The haemato-biochemical changes after the initiation of treatment is represented in table 1 and 2. There was rise in erythrocyte count, haemoglobin level and VPRC. Platelet count, leucocyte count returned to normal by day 14. There was marked increase in ALP value, which might be due to immunosuppressive therapy.

Immune mediated haemolytic anaemia is characterized by moderate to severe anaemia, autoagglutination, spherocytosis, positive Coombs' test (Klag *et al.*, 1993). In the present study the dog had characteristic signs of IMHA. The Coombs' test or antiglobulin test which demonstrates the presence of anti-erythrocyte antibodies was also performed to confirm the diagnosis, which was found to be positive at 1:32 titer. Many studies have confirmed various haemoparasites to act as a trigger for IMHA (Archer and Mackin, 2013). Recent vaccination and drug therapy are implicated in secondary IMHA (Duval and Giger, 1996; Garratty, 2010).

But the dog here was not under any drug therapy and was not vaccinated recently. In this case sheathed microfilaria was considered to be the trigger because no other underlying causes could be identified and complete recovery was noticed after immunosuppressive and levamisole treatment. Kerala is endemic for microfilariosis, as suggested by Chirayath, (2013) and occurrence of microfilariosis in dogs was 8.12 per cent.

Table.1 Haemological changes recorded in the present case study

Haematological Parameters	Reference range	Day 0	Day 5	Day 14	Day 21
RBC ($10^6/\mu\text{l}$)	5.50 – 8.50	0.89	1.65	3.56	3.04
HGB (g/dl)	12.0 – 18.0	2.3	4.7	7.0	9.9
VPRC (%)	37.0 – 55.0	9.4	16.8	26.4	24.1
MCV (fL)	60.0 – 77.0	105.6	101.8	74.2	79.3
MCH (pg)	19.0 – 25.0	25.8	28.5	19.7	32.6
MCHC (g/dL)	32.0 – 36.0	24.5	28	26.5	41.1
RDW (%)	11.0 – 14.0	15	23.4	19.3	13.2
PLT ($\times 10^3/\mu\text{l}$)	160 - 525	98	139	368	164
WBC ($10^3/\mu\text{l}$)	6.0 - 17.0	83.7	37.6	16.5	8.6
LYM($10^3/\mu\text{l}$)	0.7 – 5.1	34.4	17.2	4.5	1.5
MON($10^3/\mu\text{l}$)	0.2 – 1.7	7.6	3.5	2.4	0.4
GRAN($10^3/\mu\text{l}$)	4.4 – 12.6	41.7	16.9	9.6	6.7

Table.2 Biochemical changes recorded in the present case study

Serum biochemistry	Reference range	Day 0	Day 14	Day 21
Total protein (g/dl)	5.4 - 7.1	8.275	4.542	4.076
Albumin (g/dl)	2.6 - 3.3	2.914	2.694	2.756
Globulin (g/dl)	2.7 - 4.4	5.361	1.848	1.32
A:G	0.9 - 0.75	0.543	1.457	2.087
Total bilirubin (mg/dl)	0.10 - 0.5	12.78	2.069	0.037
Direct Bilirubin (mg/dl)	0.06 - 0.12	4.337	1.319	0.733
Indirect Bilirubin (mg/dl)	0.01 - 0.49	8.443	0.75	0.696
ALT (U/L)	21- 102	326.5	36.02	5.196
ALP (U/L)	23 - 66	83.73	764.8	845.9
BUN (mg/dl)	10 - 28	14.16	19.663	28.037
Creatinine (mg/dl)	0.5 – 1.5	0.424	1.126	0.857

Fig.1 Pale icteric mucous membrane and haemoglobinuria on the day of presentation

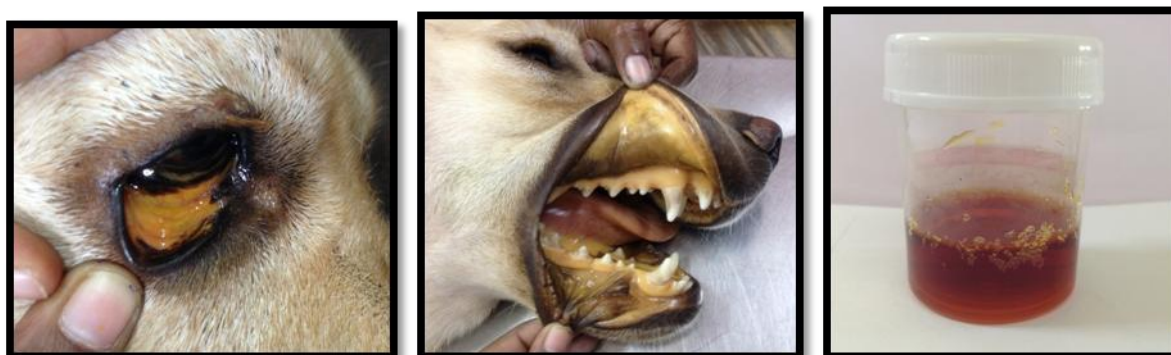

Fig.2 Postive saline agglutination test

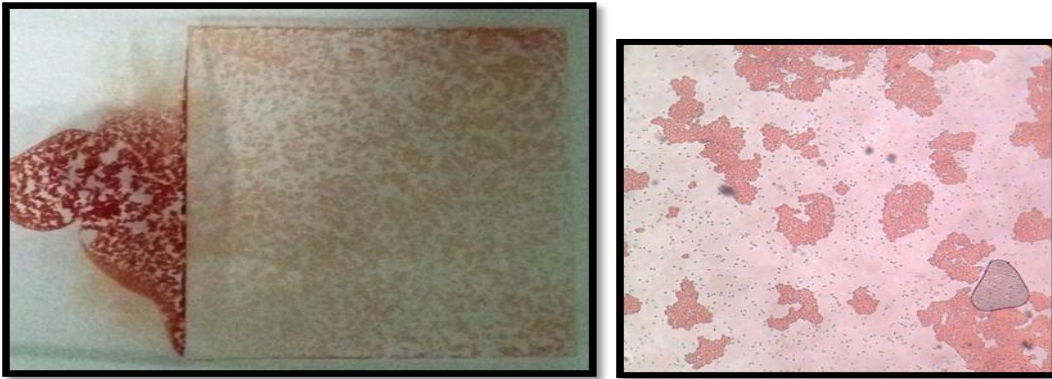


Fig.3 Microtiter method of Coombs' test positive at 1:32 titer

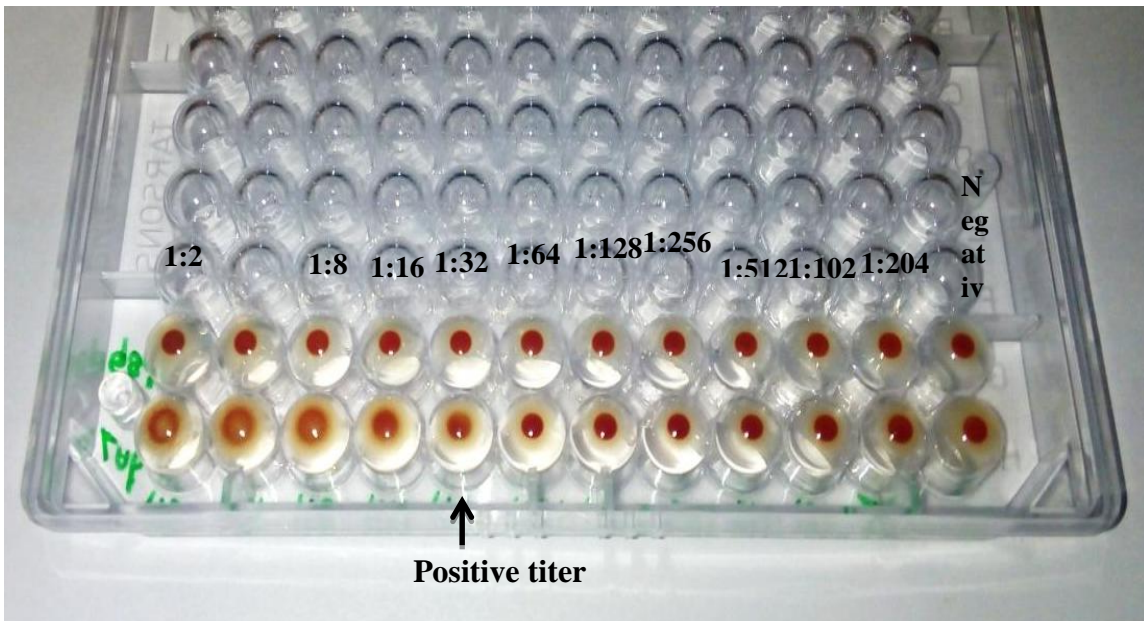
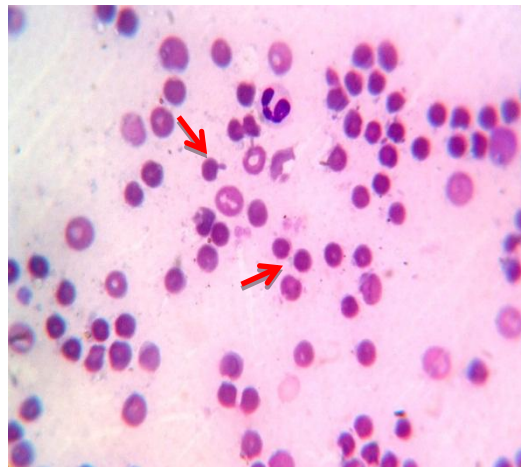
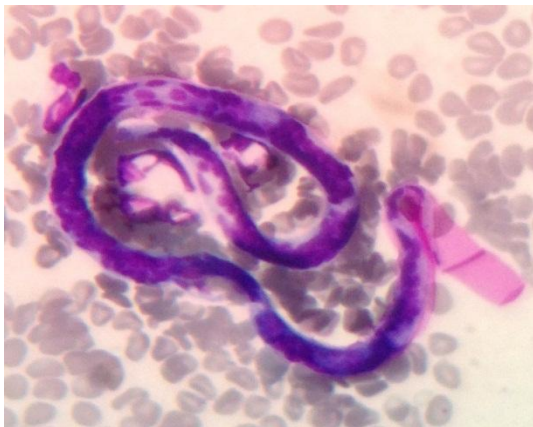

Fig.4 Blood smear examination: Sheathed microfilaria and Spherocytosis



Anaemia in microfilariosis might be due to motility of the organism leading to mechanical destruction of RBC (Chirayath, 2013). Also auto agglutination of erythrocytes was reported earlier by Hashem and Badaway (2008).

Direct and indirect Coombs' test was found to be positive in a human infected with *Wuchereriabancrofti* (Srinivas, 2003). *Dirofilariaimmitis* is known to act as a trigger for IMHA (Archer and Mackin, 2013). No species identification was carried out in the present study.

In conclusion, currently the role of antierythrocyte antibody in microfilariosis is unknown. Based on the present case the role of microfilaria in causing IMHA cannot be excluded. Further detailed study regarding the presence of antierythrocyte antibody using flow cytometry in microfilaria infected dogs should be carried out.

Acknowledgements

The author duly acknowledges the Dean, College of Veterinary and Animal Science, Mannuthy for providing facilities for conduct of the research. This study is part of M.V.Sc thesis submitted by the first author to Kerala Veterinary and Animal Sciences University, Pookode.

References

- Archer, T. and Mackin, A. 2013. Diagnosis of immune-mediated hemolytic anemia. *Today's Vet. Practice*, 3(4): 32-36.
- Chirayath, D. 2013. Molecular characterization and therapeutic management of microfilariae in dogs. Ph.D thesis, Kerala Veterinary and Animal Sciences University, Pookode, 173p.
- Duval, D. and Giger, U. 1996. Vaccine-associated immune-mediated hemolytic anemia in the dog. *J. Vet. Int. Med.*, 10(5): 290-295.
- Garratty, G. 2010. Immune hemolytic anemia associated with drug therapy. *Blood Rev.*, 24: 143-150.
- Hashem, M., and Badawy, A. 2008. Hematological and biochemical studies on filariasis of dogs. *Int. J. Vet. Med.*, 4(2): 1-7.
- Klag, A.R., Giger, U. and Shofer, F.S. 1993. Idiopathic immune-mediated hemolytic anemia in dogs: 42 cases (1986-1990). *J. Am. Vet. Med. Assoc.*, 202: 783-788.
- Pedersen, N.C. 1999. A review of immunologic diseases of the dog. *Vet. Immunol. Immunopathol.*, 69: 251-342.
- Srinivas, U.M. 2003. Severe bone marrow aplasia and Coombs'-positive autoimmune hemolytic anemia in microfilariasis - coincidental or causal? *Images in Hematol.*, 157: 1.

How to cite this article:

Ashwini, M., and Usha Narayana Pillai. 2017. Immune Mediated Haemolytic Anaemia Secondary to Sheathed Microfilaria – A Case Report. *Int.J.Curr.Microbiol.App.Sci*. 6(5): 603-607. doi: <https://doi.org/10.20546/ijemas.2017.605.069>