

Case Study

<https://doi.org/10.20546/ijcmas.2017.611.479>

Successful Management of Hydroallantoisin A Non-Descriptive Goat

S. Alagar*, C. Velladurai, S. Manivannan and M. Selvaraju

Department of Veterinary Gynaecology and Obstetrics, India

*Corresponding author

ABSTRACT

Keywords

Goat, Hydroallantois,
Histology,
Prostaglandin.

Article Info

Accepted:

28 September 2017

Available Online:

10 November 2017

A case of hydroallantois and its clinical management in a full term pregnant 3 kidding pleuriparous non-descriptive goat having symptoms of anorexia, respiratory distress, bilateral abdominal distension, reluctant to move and stand was reported. Abdominal palpation was revealed enlarged uterus with presence of large volume of fluid. Fluid therapy along with prostaglandin (cloprostenol sodium) and dexamethasone was administered for induction of parturition and managing the shock. One non-viable fetus was delivered by gentle traction. Average allantoic fluid 7-10 liters was removed. Parenteral (day 5) as well as intra-uterine antibiotic (2 days) coverage was given. Placentas were expelled out after 24 hours.

Introduction

Hydroallantois, a placental dropsical condition characterized by progressive bilateral abdominal distension, respiratory distress, depression, tendency to adopt recumbent posture, difficulty in standing and walking is caused by abnormal accumulation of large volume of allantoic fluid in the uterus of pregnant female during 5-20 days period in last trimester of pregnancy.

It has been commonly reported to occur in bovine, Bubaline, equine and rarely in ovine, canine and caprine (Milton *et al.*, 1989; Kumar *et al.*, 2012 and Feliciano *et al.*, 2013).

A reduction in the number of cotyledons has also been associated with hydrallantois (Peek, 1997). Decreased active transport of sodium

across the chorioallantoic membrane, increased permeability of the chorioallantoic membrane, hormonal imbalances, fetal renal disease (Morin *et al.*, 1994), multiple fetuses in the uterus, fetal liver disease, uterine torsion and/or twisting of the umbilical cord, deficiency of vitamin A causing decreased endometrial resistance to infections (compromises the number of caruncles)

Malnutrition conditions and heart or renal diseases of the ewe (Toniollo and Vicente, 1993) may contribute to this process.

Present paper reports about a rare case of Hydroallantois and its successful therapeutic-obstetrical management in a non-descriptive goat.

Case history and clinical observation

A 4-year-old non-descriptive doe was presented with history of full term pregnant and sudden bilateral distention of abdomen (Fig. 1), anorexia, respiratory distress, expiratory grunt, difficulty in getting up. The animal was dull and depressed with sunken eye balls. The physiological parameters such as pulse rate, respiratory rate and rectal temperature were within physiological limit. Vaginal examination revealed patent vaginal passage, absence of vaginal discharge and intact cervical seal. Based on history, symptoms and observations, this case was diagnosed as hydrallantois.

Treatment

Due to the proximity of the parturition and the clinical conditions of the patient, it was decided to induction of parturition. The goat was treated with prostaglandin 1ml (250 µg). 36 hours after induction parturition cervix was three finger dilation, cervix was fully dilate after fanning and feathering along with 50 ml of calcium diluted with 150 ml of normal saline. To avoid shock due to sudden release of allantoic fluid, rusch catheter (18") was introduced into the allantoic cavity through cervix. Simultaneously intravenous fluid (normal saline 500 ml) was given.

After removal of excessive Allantoic fluids, Presentation (P1) anterior longitudinal, Position (P2) - right dorso-ilial, Posture (P3) - bilateral shoulder flexion. The dead non-viable, immature normal male fetus was delivered by simple traction. The diseased placenta was removed manually. Following fetal delivery inj. Calcium borogluconate (150 ml, i/v) and inj. Oxytocin (20 IU, i/v) were administered. The animal was treated with inj. Enrofloxacin (250mg, i/m), inj. Meloxicam (25 mg, i/m), inj. DNS (250 ml, i/v), inj. Ringer lactate (150 ml, i/v) and inj.

Chlorpheniramine maleate, 2ml i/m. The antibiotic, antihistamine and fluids were continued for one week and dam recovered uneventfully.

Results and Discussion

Hydrallantois is the single pathologic factor present in 85 to 90 per cent of dropsical conditions in the bovine (Toniollo *et al.*, 2003). Normal allantoic fluid volume in sheep and goats has been reported to be between 0.5 to 1.5 liters (Mary and David, 2009). 6 to 18 liters of amniotic fluid has been reported to remove from the cases of hydroallantois in sheep and doe (Philip *et al.*, 2012). In present case, 7-10 liters of allantoic fluid was removed per vaginal. The exact cause of hydrallantois is not certain but it has been reported to associated with consumption of legumes with high estrogens, hypothyroidism and placental or uterine disease (Mobini *et al.*, 2002) or diseased uterus wherein caruncles are not functional and rests of the placentomes are enlarged and diseased (Bhattacharyya *et al.*, 2012) or development of adventitial placentation (Misri, 2001). The abnormal functioning of placentomes has been attributed to inadequate numbers of caruncles (Misri, 2001). The deficient numbers of caruncles associated with hydroallantois may be due to either a congenital lack of development or uterine disease acquired in later life (Peek, 1997).

The cause of hydrallantois in this ewe was not certain. Since no abnormalities were detected in the fetuses and placental edema was the only lesion found, we believe that this could have caused a decrease in the active transport of sodium across the chorioallantoic membrane or an increase in the permeability of the chorioallantoic membrane (Peiró *et al.*, 2007). Hormonal imbalances due to phytoestrogens ingestion (Adams *et al.*, 1981) in the pasture cannot be discarded.

Before treatment

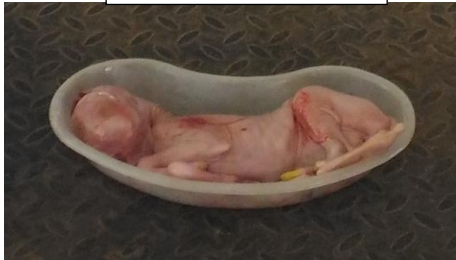

Bilateral

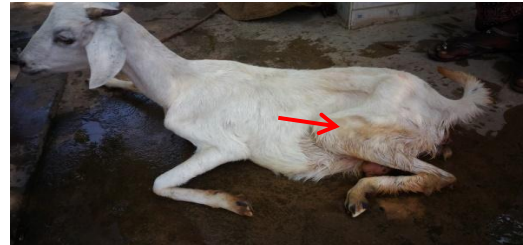Allantoic fluid (7 – 10)



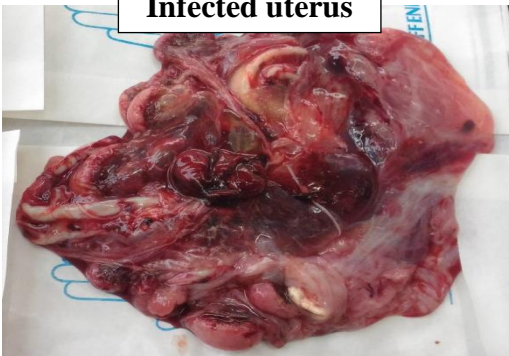
Immature fetus



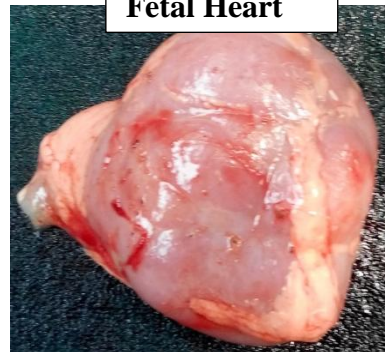After



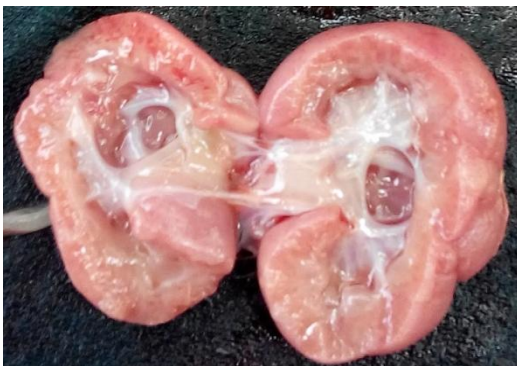Infected uterus



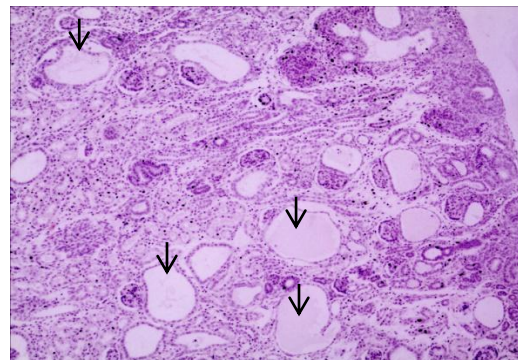
Fetal Heart



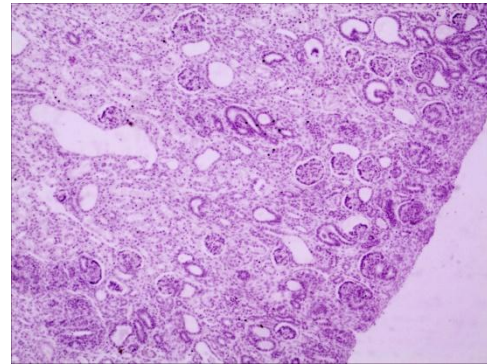
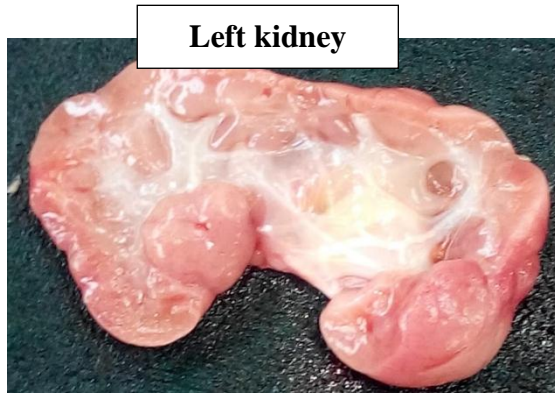Right kidney



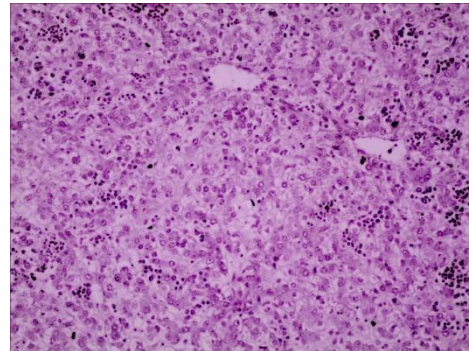
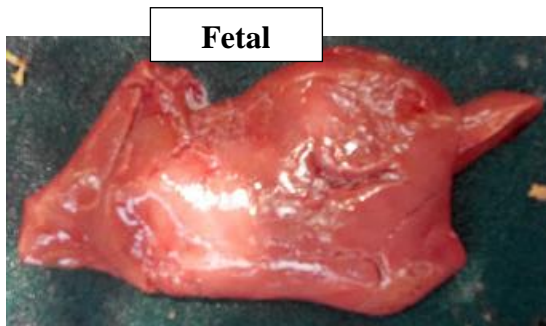Histolog



Cortex has diffuse severe dilatation of renal tubules.



Cortex showed diffuse moderate dilatation of renal tubules



Normal haemopoietic liver

Bhattacharyya *et al.*, (2012) and Morin *et al.*, (1994) preferred caesarian section for relieving severe abdominal discomfort and respiratory distress. In present case pre-vaginal relieving of allantoic fluid is carried out. Most fetuses of animals with hydrallantois are under developed with congenital defects or are apparently normal but not viable (Morin *et al.*, 1994) in present case one non-viable and underdeveloped fetus was observed.

References

- Adams, N. R., H. Hearnshaw and C. M. Oldham, 1981. Abnormal function of the corpus luteum in some ewes with phyto-estrogenic infertility. *Australian Journal of Biological Science*.34: 61-65.
- Bhattacharyya, H.A., S. H. Dar, M. R. Fazili and A. Hafiz, 2012. A Typical Case of Hydrallanto is accompanied by Fetal Monstrosity in a Local Ewe of Kashmir. *Veterinary Research Forum*.3: 221 – 223.
- Feliciano, M. A. R., D. J. Cardilli, R. M. Crivelaro, E. Garrido, M. A. M. Silva, T.L.L. Castanheira and W.R.R Vicente, 2013. Hydrallantois in a female dog: a case report. *Arquivo Brasileiro de Medicina Veterinária e Zootecnia*, 65: 1091-1095.
- Kumar, S., U. Sharma, A. K. Pandey, S. Agarwal, R. B. Kushwaha and A. K. Tripathi, 2012. Hydroallantois in Buffalo: A Case Report. *Buffalo Bulletin*.31: 67-69.
- Mary C. Simth and David and M. Sherman, 2009. Periparturient Problems; Hydrops of Uterus; in *Goat Medicine*, 2nd edition., Wiley-Blackwell, Iowa, USA.
- Milton, A., B. Welker and P. Modransky, 1989. Hydrallantois in Ewe. *J. Am. Vet. Med. Assoc.*, 195:1385-86.

- Misri, J., 2001. Hydrallantois in a goat. *Indian Veterinary Journal*, v.78, p.255-256, 2001.
- Mobini, S., A. M. Health and D. G. Pugh, 2002. *Theriogenology of sheep and goats*. In: *Sheep and Goat Medicine*. Ed: Pugh, D.G W-B Saunders co. Philadelphia. 129-186.
- Morin, D. E., L. Hornbuckle, L. Rowan and H. E. Whiteley 1994. Hydrallantois in a caprine doe. *J. Am. Vet. Med. Assoc.*, 204:108-111.
- Morin, D. E., T. Hornbuckle, L. L. Rowan and H. E. Whiteley, 1994. Hydrallantois in a caprine doe. *Journal of American Veterinary Medical Association*, 204:108-111.
- Peek, S. F. 1997. Dropsical conditions affecting pregnancy. In: Youngquist, R. S. *Current Therapy in Large Animal Theriogenology*. 1^{ed.}, W. B. Saunders, 400-403.
- Peiró, J. R., A. S. Borges, R. Yanaka, M. B. Koivisto, L. C. N. Mendes, F. L. F. Feitosa, J. O. Abujamra, C. A. Rodrigues, 2007. Hydrallantois in ewe (Case Report). *ArsVeterinaria, Jaboticabal*, 23:116-119.
- Philip, L. M., M. R. Mohan and P. F. Bastin, 2012. Fetal Anasarca Twins with Hydroallantois in Malabari Does. *J. Ind. Vet. Assoc., Kerala*. 10: 52-53.
- Toniollo, G. H. and W. R. R. Vicente, 1993. *Manual de Obstetrícia Veterinária*. 1^{ed.}, São Paulo, Livraria Varela.
- Toniollo, G. H., W. R. R. Vicente and M. B. Carvalho, 2003. *Manual de Obstetrícia Veterinária*. 1^{edn.}, São Paulo, Livraria Varela.

How to cite this article:

Alagar, S., C. Velladurai, S. Manivannan and Selvaraju, M. 2017. Successful Management of Hydroallantois in A Non-Descriptive Goat. *Int.J.Curr.Microbiol.App.Sci*. 6(11): 4095-4099. doi: <https://doi.org/10.20546/ijcmas.2017.611.479>