

Original Research Article

<http://dx.doi.org/10.20546/ijcmas.2016.509.051>

***Tinea cruris* and *Tinea genitalis* due to *Trichophyton interdigitale* in and around Muzaffarnagar (Western UP), India: Possibly an Outbreak**

Thakur Rameshwari<sup>1\*</sup>, Kushwaha Pragya<sup>2</sup>, Kumar Harish<sup>3</sup> and Paramjit Singh<sup>4</sup>

Department of Microbiology, Muzaffarnagar Medical College, Opp: Begrajpur Industrial area, Meerut Road, Muzaffarnagar (U.P.), India

\*Corresponding author

**A B S T R A C T**

Identification of dermatophyte causing *Tinea cruris* and *Tinea genitalis* by culture, biochemical and morphological characteristics in 130 cases during past six months, from February 1 to July 30, 2016. Patients suffering from tinea cruris or tinea genitalis were scraped from the affected area after cleaning the part with 70% alcohol. Potassium hydroxide mounts (KOH 20%) were prepared for microscopy to see the fungal elements. Cultures were set up to study the morphological characteristics and for performing the biochemical tests and in vitro hair perforation test. All one hundred and thirty isolates were positive for microscopy and culture and were identified as *Trichophyton interdigitale* (former *Trichophyton mentagrophyte*) *T. interdigitale* was found to be the only species responsible for all the cases of tinea infection. More males were affected than females. Few single females were suffering from the tinea infection. Most of the married females, who had *Tinea cruris* or *Tinea genitalis*, gave the history of their spouses having acquired the infection first. Some single males who had *Tinea genitalis*, gave the history of having had sex with commercial sex worker. Two male patients gave the history of sharing the loincloth for wrestling. Few patients also had tinea corporis and tinea faciei. To avoid the spread of infection, it is important to identify the pathogen and start the treatment at the earliest.

**Keywords**

*Trichophyton interdigitale*,  
*Tinea cruris*,  
*Tinea genitalis*,  
Dermatophytes.

**Article Info**

Accepted:  
18 August 2016  
Available Online:  
10 September 2016

**Introduction**

*Tinea corporis* and *Tinea cruris* are superficial dermatophyte infections and occur all over the world, but more common in tropical countries. Commonly, this is called ringworm. In *Tinea cruris*, there is dermatophyte infection of groin, but genitalia are usually spared even if the infection is extensive, whereas in *Tinea genitalis*, scrotum and penis are affected (Figure 1) and in females, labia majora and

mons pubis are also involved (Figure 2). Until now, *Trichophyton rubrum* has been the most frequently isolated species (La Touche, 1967; Kumar *et al.*, 1981; Pillai *et al.*, 1975; Dekio *et al.*, 1990) followed by *Trichophyton mentagrophyte*, *Epidermophyton floccosum* and *Trichophyton verrucosum* (La Touche, 1967).

Spread of infection can be human to human, from animals and from soil.

Surprisingly, we started receiving many cases of *Tinea cruris* and *Tinea genitalis* all due to *Trichophyton interdigitale* early this year. Majority of the cases gave history of having had *Tinea cruris/Tinea genitalis* prior to tinea infection of other parts of the body. Non-had concomitant infection such as *Tinea pedis* or *Tinea unguium*. In this study, the patients gave varied history about how they got infected. Very few gave history of sexual contact in cases of *Tinea cruris* or *Tinea genitalis*. Two patients gave history of sharing langota (loin Cloth) used for wrestling in India.

### **Patients and Methods**

During the past six months starting from Feb1, 2016 to July 30, 2016, 130 patients either with *Tinea cruris* or *Tinea genitalis* were enrolled for the study.

Only those patients with *Tinea cruris* or with *Tinea genitalis* were enrolled, who were not on antifungal drugs for past 4 weeks and lesions were of less than six months duration and in the age group 15-70 years.

Skin scrapings were taken from the affected areas in groin or from genital lesions if involved after thoroughly cleaning the lesions with 70% alcohol. Scrapings were also taken from any concomitant lesion elsewhere, e.g. toe nail, tenia pedis or tenia corporis if any and was processed and cultured separately in order to differentiate between autoinfection or mixed infection.

All the samples were examined for fungal elements in KOH 20% mount under high power of the microscope for fungal hyphae. Sabouraud's dextrose agar supplemented with cycloheximide and chloramphenicol

was used and plates were incubated at 30°C. Both positive and negative samples were inoculated on Sabouraud's Cycloheximide Chloramphenicol Agar (HI Media). Culture positive plates were seen for colony characteristics both on surface and reverse (Figure 3 and 5). Lacto phenol Cotton Blue (LCB) preparations by teased mount method and scotch tape method were prepared to study the microscopic structures in details (Figure 4 and 6). Urease test and in vitro hair perforation tests were performed for the confirmation of *Trichophyton interdigitale* species. Also, other standard tests needed for the identification of dermatophytes were performed according to the description given in various textbooks, manuals, and journals (Nenoff *et al.*, 2014; Rippon, 1988; Kwon-Chung *et al.*, 1992; Larone, 2002; Vena *et al.*, 2012).

Our study has limitation, because of the lack of molecular typing. It is impossible to differentiate between anthropophilic and zoophilic strains of *T. interdigitale*, because morphological differentiation by classical microscopic and biochemical methods is often problematic even in the hands of experienced mycologist.

### **Clinical Results**

Most of the patients with *Tinea cruris* presented with extensive annular scaly lesions with central clearing. In male patients with *Tinea genitalis* along with the involvement of groin, there were scaly lesions on penis and scrotum. In female patients of *Tinea genitalis*, besides lesions in groin, there were erythematous, annular scaly lesions on mons pubis and labia majora. Non of our patients either with *Tinea cruris* or *Tinea genitalis* had pustular lesions or involvement of inguinal lymph nodes.

Out of a total 130 patients enrolled (84 males and 46 females), *Tinea cruris* was

more common in the age group 26-35 year both in males (n=18[21.428%]) and in females 14 (30.434%) *Tinea genitalis* was also found to be more common in the same age group: males (n=10 [11.9047%]) and in females (n=4[8.695%]) (Table 1). There were 7 couples in different age groups, who had *Tinea cruris*.

**Mycological Results**

Intrestingly, *T. interdigitale* was isolated from all the cases. Out of 100 cases with *Tinea cruris*, white cottony growth was seen in (n=75 [75%]), mixed i.e. partly granular and partly cottony in (n=22[22%]) and granular in (n=3[3%]).

Isolates from *Tinea genitalis* cases also had

varied colony appearance and out of 30 cases: White cottony was seen in (n=10 [33.33%]), Mixed appearance (n=14[46.66%]) and granular (n=6[20%]).

**Discussion**

A recent report of tourists from Switzerland having visited South East Asia and having protected sex with commercial sex workers and later suffered from severe inflammatory *Tinea genitalis* due to *T. interdigitale*. Some of them even required hospitalization on their return (Luchsinger *et al.*, 2015). *Tinea genitalis* has been reported from India from time to time in isolated reports (Pandey *et al.*, 1981; Vora *et al.*, 1994; Mukopadhyay, 2005). It is more common in hot and humid climate of tropics.

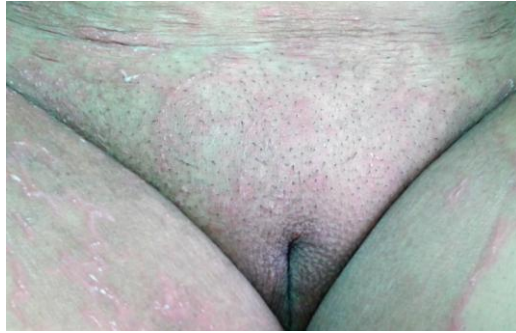**Table.1**

Age in years	<i>Tinea cruris</i>		<i>Tinea genitalis with Tinea cruris</i>	
	Male	Female	Male	Female
15-25	32 (38.096%)	8 (17.391%)	7 (8.333%)	3 (6.5217%)
26-35	18 (21.428%)	14 (30.434%)	10 (11.9047%)	4 (8.695%)
36-45	7 (8.333%)	4 (8.695%)	3 (3.571%)	3 (6.5217%)
46-55	7 (8.333%)	10 (21.739%)	-	-
<b>Total</b>	64 (76.190%)	36 (78.260%)	20 (23.808%)	10 (21.739%)

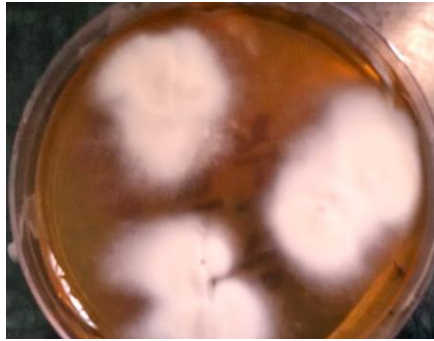
**Fig.1** *Tinea genitalis* (Annular scaly lesions with central clearing and scaly lesions of penis and scrotum)



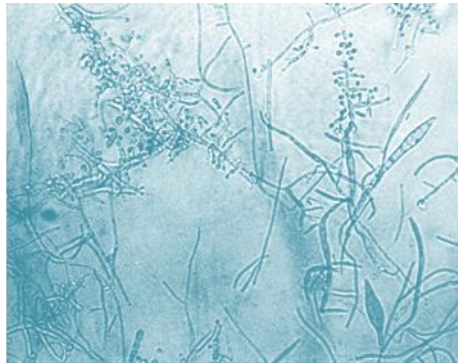
**Fig.2** *Tinea genitalis* (Extensive scaly lesions of groin along with involvement of mons pubis and labia majora.



**Fig.3** Cottony growth of *T. interdigitale*



**Fig.4** LCB mount



**Fig.5** Powdery growth of *T.interdigitale* (Zoophilic strain)



**Fig.6** LCB mount (Abundant sporulation)



In a study by Kumar *et al.*, (1981) they found 1% genital involvement in 2200 cases of dermatophyte infections. In another study by Pandey *et al.*, 20% patients with *Tinea cruris* also had genital involvement (Pandey *et al.*, 1981).

Few male patients gave history of having had sex with commercial sex workers. One of the male patients gave history of being homosexual and had genital molluscum contagiosum. In case of female patients, especially married ones gave the history of their spouses suffering from *Tinea cruris*.

In one study of nine cases of *Tinea genitalis* by Romano *et al* from Italy (Romano *et al.*, 2005), five cases of *Tinea genitalis* were due to *T. rubrum*, two due to *E. floccosum* and two due to *T. interdigitale*. There is no mention of sexual transmission, but concurrent infections like *Tinea unguium* of toenail, tinea pedis and tinea barbae is mentioned. *Tinea genitalis* and *Tinea cruris* can be transmitted sexually as well as by other means and it can be caused by both zoophilic and anthropophilic dermatophytes. None of our patients had highly inflammatory and pustular lesions, which goes in favour of infections being caused by anthropophilic strain of *T. interdigitale*. Also, lesions cleared after two weeks of treatment with Terbinafine 250 mg once a day.

In conclusion, all cases of *Tinea cruris* should be examined carefully for tinea genitalis. Though *Tinea genitalis* doesn't qualified to be called sexually transmitted infection, but *Tinea cruris* and *Tinea genitalis* can actually be transmitted sexually. Condoms have no role in the prevention of transmission of the infection. Lesions on the genital area should be looked for carefully, because it may point at the promiscuous sexual behaviour of the person and can help in diagnosing other sexually transmitted infections.

### References

- Dekio, S., Qin, L., Kawasaki, Y. *et al.* 1990. Tinea of scrotum: report of a case presenting as lichenified plaques. *J. Dermatol.*, 17: 448-51.
- Kumar, B., Talwar, P., Kaur, S. 1981. Penile tinea. *Mycopathologia*, 75: 169-72.
- Kwon-Chung, K.J., Bennett, J.E. 1992. Dermatophytoses (Ringworm, Tinea, Dermatormycoses). In: Medical Mycology. 2nd ed. Philadelphia, PA: Lea and Febige, 105-170.
- La Touche, C.J. 1967. Scrotal dermatophytosis. *Br. J. Dermatol.*, 79: 339-44.
- Larone, D.H. 2002. Dermatophytes. In: Medically Important Fungi: A Guide to Identification. 4th ed. Washington DC: American Society for Microbio-

- logy (ASM) Press, 229–253.
- Luchsinger, I., Bosshard, P.P., Kasper, R.S., Reinhardt, D., Lautenschlager, S. 2015. *Tinea genitalis*: a new entity of sexuality transmitted infection? Case series and review of literature. *Sex Transm. Infect.*, 0: 1-4.
- Mukopadhyay, A.K. 2005. Trichophyton rubrum infection of prepuce. *Indian J Dermatol. Venerol. Leprol.*, 71: 130-131.
- Nenoff, P., Krüger, C., Schaller, J., et al. Mycology—an update part 2: dermatomycoses: clinical picture and diagnostics. *J. Dtsch. Dermatol. Ges.*, 12: 749–77.
- Pandey, S.S., Chandra, S., Guha, P.K. et al. 1981. Dermatophyte infection of penis; association with particular undergarments. *Int. J. Dermatol.*, 20: 112-114.
- Pandey, S.S., Chandra, S., Guha, P.K. et al. 1981. Dermatophyte infection of the penis; association with a particular undergarment. *Int. J. Dermatol.*, 20: 112-114.
- Pillai, K.G., Singh, G., Sharma, B.M. 1975. Trichophyton rubrum infection of the penis. *Dermatologica*, 150: 252–4.
- Rippon, J.W. 1988. Dermatophytosis and Dermatormycosis. In: Medical Mycology: The Pathogenic Fungi and Pathogenic Actinomycetes. 3rd ed. Philadelphia, PA: Saunders, 169–275.
- Romano, C., Ghilardi, A. and Papini, Manuela. 2005. Nine male cases of *Tinea genitalis*. *Mycoses*, 48: 202-204.
- Vena, G.A., Chieco, P., Posa, F., Garofalo, A., Bosco, A., Cassano, N. 2012. Epidemiology of dermatophytoses: retrospective analysis from 2005 to 2010 and comparison with previous data from 1975. *New Microbiol.*, 35(2): 207–213.
- Vora, N.S., Mukopadhyay, A.K. 1994. Incidence of dermatophytosis of penis and scrotum. *Indian J. Dermatol. Venerol. Lepro.*, 60: 89-91.
- Weitzman, I., Summerbell, R.C. 1995. The Dermatophytes. *Clin. Microbiol. Rev.*, 8(2): 240–259.

#### How to cite this article:

Thakur Rameshwari, Kushwaha Pragya, Kumar Harish and Paramjit Singh. 2016. *Tinea cruris* and *Tinea genitalis* due to *Trichophyton interdigitale* in and around Muzaffarnagar (Western UP), India: Possibly an Outbreak. *Int.J.Curr.Microbiol.App.Sci* 5(9): 468-473.  
doi: <http://dx.doi.org/10.20546/ijcmas.2016.509.051>