

Original Research Article

<http://dx.doi.org/10.20546/ijcmas.2016.504.042>

Study of Keratomycosis in a Tertiary Care Hospital in Visakhapatnam, India

Venkata Hemalatha Neeli and T. Parvathi*

Department of Microbiology, Andhra Medical College, Visakhapatnam

*Corresponding author

ABSTRACT

Keywords

Corneal ulcer,
Keratomycosis,
Middle-aged
men,
Trauma,
Vegetative matter.

Article Info

Accepted:
20 March 2016
Available Online:
10 April 2016

Corneal infections are one of the leading causes of ocular morbidity and blindness world-wide. If normal defense mechanisms of the eye are compromised, almost any microorganism can invade the cornea. Fungal infections affecting the cornea are referred to as keratomycosis or mycotic keratitis. The peak incidence is seen during harvest seasons particularly in tropical and sub-tropical environments. Middle-aged men are more commonly affected. Trauma with vegetative matter serves as the most important pre-disposing factor for mycotic keratitis. It is important to know the exact aetiology of corneal ulcer to institute appropriate therapy in time, lest serious consequences may follow.

Introduction

Corneal infections are one of the leading causes of ocular morbidity and blindness world-wide (Saha and Das, 2006; Iyer *et al.*, 2006; Upadhyay *et al.*, 1991; Srinivasan, 2004). Most of the pathogens cause ulceration of the cornea; which if not accurately diagnosed in time, may be devastating.

Eyelids, tear film and corneal epithelium serve as normal defense mechanisms against infection. If these are compromised, almost any microorganism can invade the cornea. Among the wide spectrum of cornea invaders, fungi are significant pathogens. Fungal infections affecting the cornea are referred to as keratomycosis or mycotic keratitis. The causative fungi of keratomycosis are ubiquitous.

The peak incidence is seen during harvest seasons particularly in tropical and sub-tropical environments (Lisa *et al.*, 2011; Wong *et al.*, 1997). Middle-aged men are more commonly affected. Trauma with vegetative matter serves as the most important pre-disposing factor for mycotic keratitis (Saha and Das, 2006; Lisa *et al.*, 2011; Upadhyay *et al.*, 1991).

It is very important to identify the causative agent of fungal corneal ulcer and institute timely management; lest sight-threatening conditions may follow.

The aim and objectives of this study includes, to isolate and identify the fungi from corneal scrapings of suspected keratitis patients. And

also to determine their anti-fungal susceptibility pattern.

Materials and Methods

The present study was conducted at King George Hospital, Visakhapatnam over a period of one year from January 2015 to December 2015. Socio-demographic history and information pertaining to the risk factors was recorded. After diagnosing the infective corneal ulcer clinically, under strict aseptic conditions, corneal scrapings were obtained by qualified ophthalmologists of Regional Eye Hospital, Visakhapatnam and were sent to the Microbiology Department for further processing.

The corneal scrapings were obtained from 50 suspected cases of mycotic keratitis (Figure1) after performing a thorough ocular examination by the slit-lamp bio-microscope. After instillation of 4% lignocaine eye drops, material from the base and edge of the corneal ulcer was obtained using a sterile Bard-Parker blade (No.15). The sample thus obtained was further processed according to the standard microbiological protocols.

First, direct microscopic examination was done using 10% KOH for presumptive diagnosis of mycotic keratitis (Figure 2).

The sample was then inoculated onto Sabouraud's Dextrose Agar (SDA) with Gentamicin and was incubated in a Biological Oxygen Demand (BOD) incubator (Figure

3). Various fungal isolates were obtained (Figure 4 to Figure 9). The isolates obtained were identified and antifungal susceptibility testing was done as per CLSI M44-A2 guidelines for *Candida* and CLSI M51-A guidelines for non-dermatophytic filamentous fungi.

Results and Discussion

In the present study, out of 50 corneal scraping samples processed, 15 showed fungal hyphae in KOH wet mount (Diagram 1).

Out of 50 samples processed, 23 were culture positive for fungal isolates and 27 were culture sterile (Diagram 2).

Filamentous fungi were isolated more when compared to that of yeasts. The various fungal isolates obtained were *Aspergillus fumigatus* – 8 isolates (35%), *A.niger* – 5 (22%), *A.flavus* – 4 (17%), *Pencillium spp.* – 2 (9%), *Candida spp.* – 2 (9%) and *Fusarium spp.*- 2 (9%) isolates (Diagram 3).

Fungal corneal ulcers were more common in the age group of 40- 60 years (56.5%) followed by 20 – 40 years (30%) (Diagram4). Thus, economically productive age group is most commonly affected.

Fungal corneal ulcers were more common in the males (65.21%) when compared to that of females (Diagram 5). This might be because of more occupational exposure of males compared to that of females.

Table.1 Anti-fungal susceptibility testing for fungal isolates isolated from corneal ulcers

	Susceptible	Intermediate	Resistant
Amphotericin-B	34.78%	43.47%	21.73%
Itraconazole	43.47%	13.04%	43.47%
Fluconazole	17.39%	30.43%	52.17%
Ketoconazole	30.43%	21.73%	47.82%
Clotrimazole	26.08%	30.43%	43.47%
Nystatin	13.04%	52.17%	34.78%

Figure.1 Clinical Photographs Showing Typical Corneal Ulceration

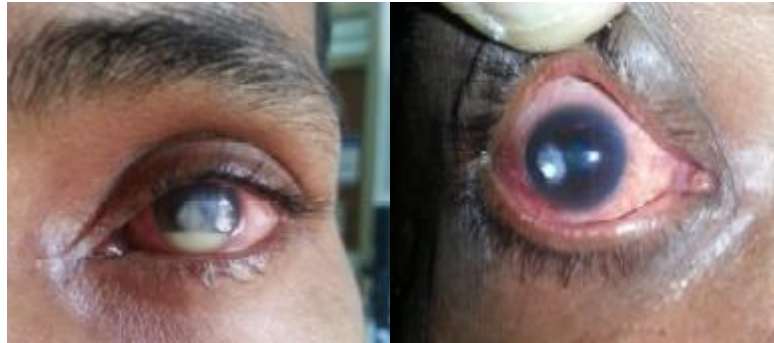

Figure.2 KOH Mount Showing Septate Hyphae

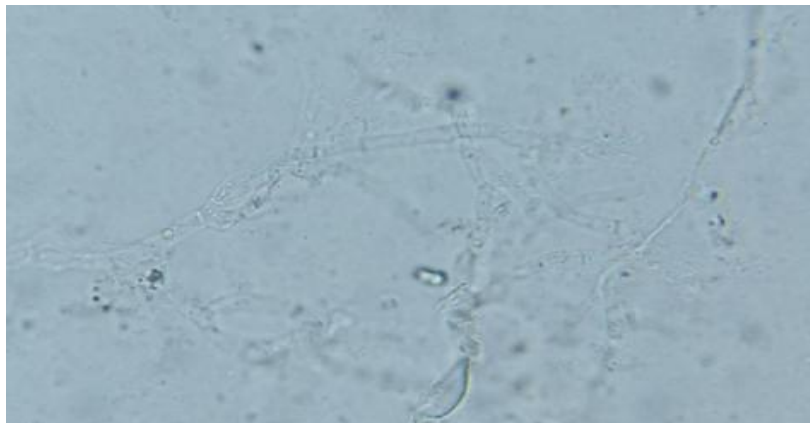


Figure.3 BOD Incubator with McCartney Bottles Showing Fungal Colonies on SDA



Figure.4 SDA and LPCB Wet Mount Showing *Fusarium spp*



Figure.5 SDA and LPCB Wet Mount Showing *Aspergillus flavus*




Figure.6 SDA and LPCB Wet Mount Showing *Aspergillus niger*

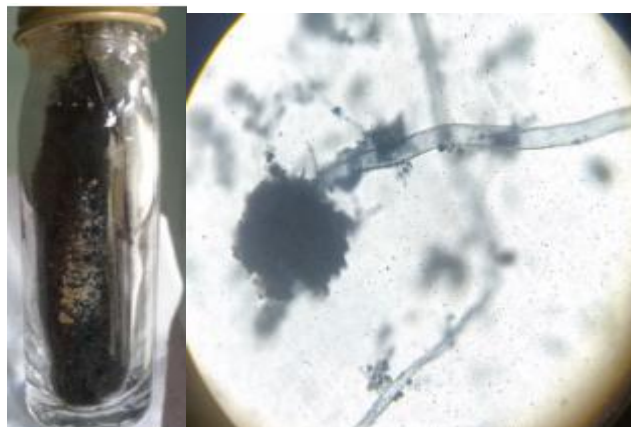

Figure.7 SDA and LPCB Wet Mount Showing *Aspergillus fumigatus*




Figure.8 SDA and Gram's Stain Showing *Candida spp*



Figure.9 SDA and LPCB Wet Mount Showing *Pencilium spp*

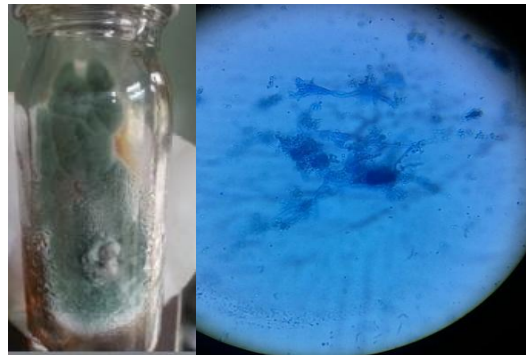


Diagram.1 Pie Diagram Representing percentage of Samples Showing Hyphae in KOH wet mount

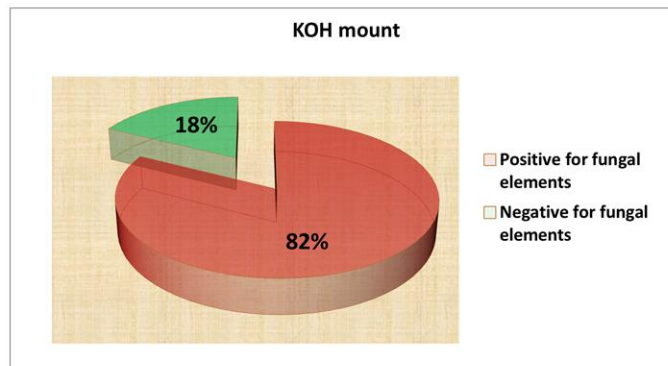


Diagram.2 Pie Diagram Showing Percentage of Culture Positivity

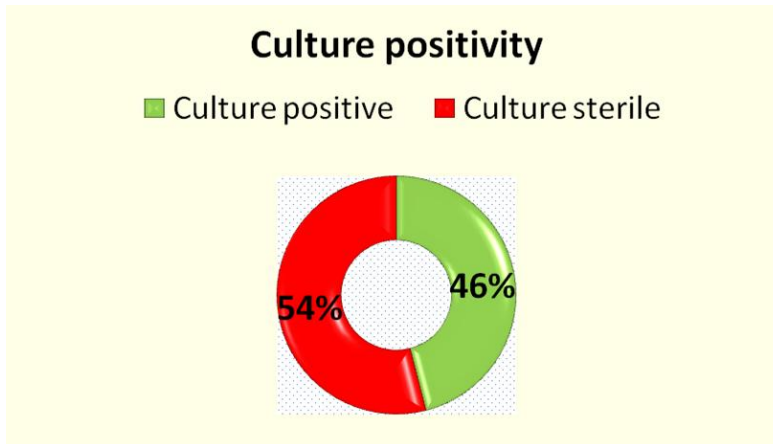


Diagram.3 Bar Diagram Showing Fungal Isolates Obtained from Corneal Scrapings

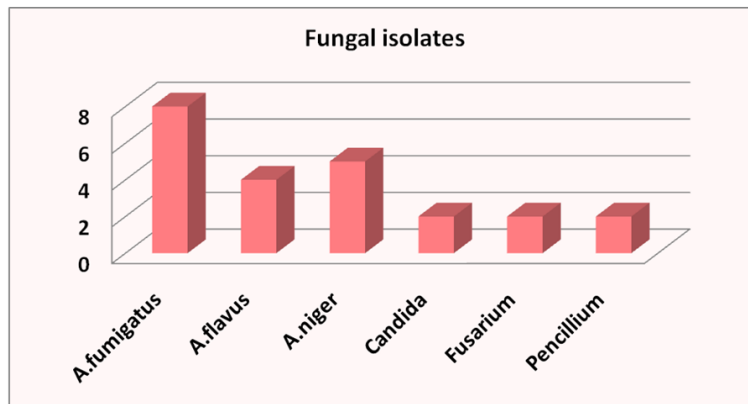


Diagram.4 Bar Diagram Showing Age Distribution Pattern of Keratomycosis

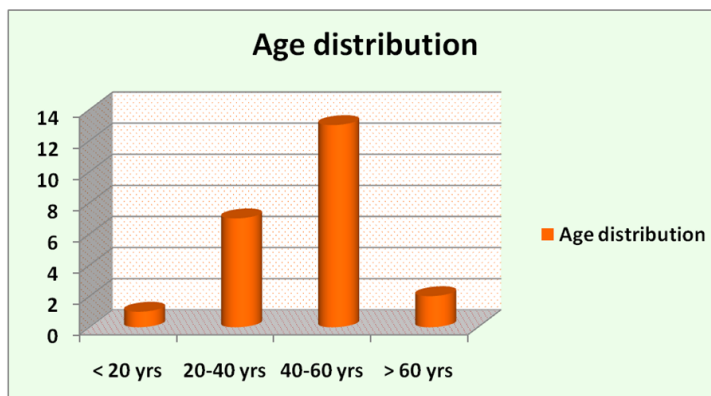


Diagram.5 Bar Diagram Showing Sex Distribution Pattern of Keratomycosis

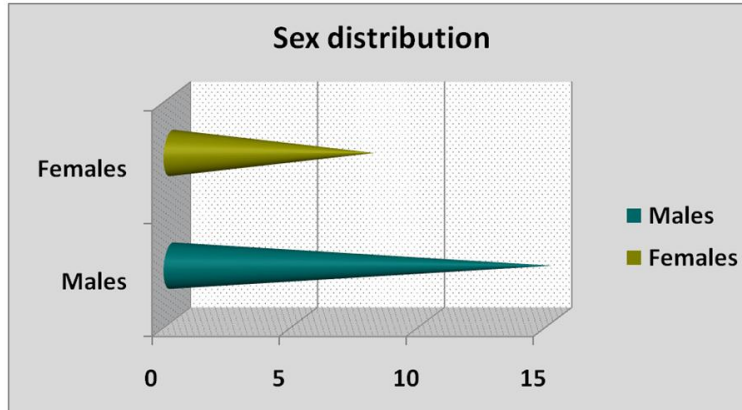


Diagram.6 Bar Diagram Showing the Impact of Occupation on Keratomycosis

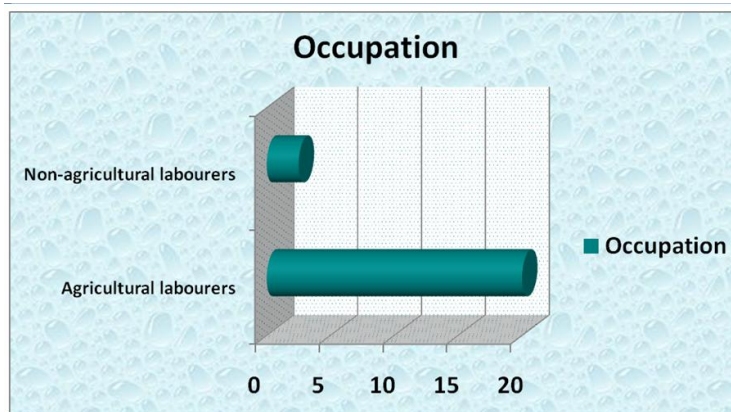
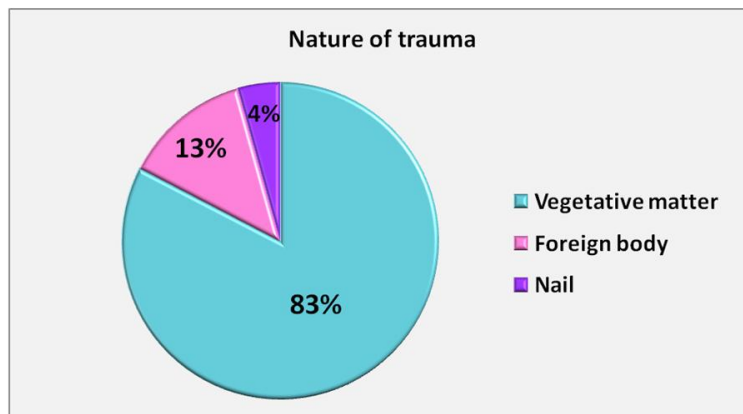


Diagram.7 Pie Diagram Showing the Nature of Trauma Responsible For keratomycosis



Fungal corneal ulcers were more common in agricultural labourers (86.9%) when compared to non-agricultural labourers (Diagram 6). This might be because of more chances of

exposure to vegetative matter in farmers than others. Corneal injury appears to be the most important predisposing factor followed by diabetes mellitus. Vegetative matter (83%),

followed by foreign body (13%) is the most common agent responsible for trauma (Diagram 7).

Antifungal susceptibility testing was done as per CLSI M44-A2 guidelines for *Candida* and CLSI M51-A for non-dermatophytic filamentous fungi on Mueller Hinton agar against Amphotericin-B - 20µg, Itraconazole - 10µg, Fluconazole - 10µg, Ketoconazole - 10µg, Clotrimazole - 10µg and Nystatin - 100units/disc (Table 1).

In the present study, males are more commonly affected than that of females. Similar gender predilection was shown by Joanne W.Ho, *et al.*, (2016); Xie L, *et al.*, (2006); Iyer SA' *et al.* (2006); Chowdhary A, *et al.* (2005) and Bharathi MJ, *et al.* (2003).

A large proportion of the patients affected with keratomycosis in the present study were middle-aged adults, and most of them were farmers. Ocular trauma with vegetative matter was the most important risk factor. Similar findings were observed by Wang L, *et al.* (2009); Joanne W. Ho, *et al.* (2016); Xie L, *et al.* (2006); Iyer SA' *et al.* (2006); Chowdhary A, *et al.* (2005) and Bharathi MJ, *et al.* (2003).

In the present study, filamentous fungi were the most common causative pathogens. Similar findings were observed by Joanne W. Ho, *et al.* (2016) and Srinivasan M (2004). *Aspergillus spp.* is the most common isolate of the study. This finding is consistent with that of Chowdhary A, *et al.* (2005).

In conclusion, Fungal keratitis is often a severe disease in which diagnosis can be challenging, the response to medical treatment is slow, and the clinical outcome poor. Corneal perforation is 5 to 6 times more likely with fungal keratitis than it is with bacterial keratitis (Lisa *et al.*, 2011). Because of serious consequences of infectious keratitis, it is important to know the exact aetiology of corneal ulcer to institute appropriate therapy in

time. Laboratory confirmation should be undertaken and fungal infection should be ruled out before prescribing corticosteroids and antibacterial antibiotics (Saha and Das, 2006).

References

- Bharathi, M.J., Ramakrishnan, R., Meenakshi, R., Padmavathy, S., Shivakumar, C., Srinivasan, M. 2007. Microbial keratitis in South India: influence of risk factors, climate, and geographical variation. *Ophthalmic Epidemiol.*, 14(2): 61–9.
- Bharathi, M.J., Ramakrishnan, R., Vasu, S., Meenakshi, R., Palaniappan, R. 2003. Epidemiological characteristics and laboratory diagnosis of fungal keratitis. A three-year study. *Indian J. Ophthalmol.*, 51(4): 315–21.
- Chowdhary, A., Singh, K. 2005. Spectrum of fungal keratitis in North India. *Cornea*, 24(1): 8–15.
- diBisceglie, A.M., Carmichael, T.R. 1987. Factors predisposing to central corneal ulceration in a developing population. *S. Afr. Med. J.*, 71(12): 769–70.
- Dóczi, I., Gyetvai, T., Kredics, L., Nagy, E. 2004. Involvement of *Fusarium* spp. in fungal keratitis. *Clin. Microbiol. Infect.*, 10(9): 773–6.
- Iyer, S.A., Tuli, S.S., Wagoner, R.C. 2006. Fungal keratitis: emerging trends and treatment outcomes. *Eye Contact Lens*, 32(6): 267–71.
- Joanne, W., Ho, Mark, M., Fernandez, Rachele, A., Rebong, Alan, N., Carlson, Terry Kim, Natalie, A., Afshari. 2016. Microbiological profiles of fungal keratitis: a 10-year study at a tertiary referral center. *J. Ophthalmic Inflamm Infect.*, 6: 5.
- Laspina, F., Samudio, M., Cibils, D., Ta, C.N., Fariña, N., Sanabria, R., Klauss, V., Miño de Kaspar, H. 2004. Epidemiological characteristics of microbiological results on patients with infectious corneal ulcers: a 13-year survey in Paraguay. *Graefes Arch. Clin. Exp. Ophthalmol.*, 242(3): 204–9.

- Liesegang, T.J., Forster, R.K. 1980. Spectrum of microbial keratitis in South Florida. *Am. J. Ophthalmol.*, 90(1): 38–47.
- Lisa, J., Keay, Emily, W., Gower, Alfonso Iovieno, Rafael, A., Oechsler, Eduardo, C., Alfonso, M.D., Alice Matoba, Kathryn Colby, Sonal, S., Tuli, Kristin Hammersmith, Dwight Cavanagh, Salena, M., Lee, John Irvine, R., Doyle Stulting, Thomas, F., Maugerand Oliver, D., Schein. 2011. Clinical and Microbiological Characteristics of Fungal Keratitis in the United States, 2001–2007: A Multicenter Study. *Ophthalmol.*, 118(5): 920–926.
- Saha, R., Das, S. 2006. Mycological profile of infectious Keratitis from Delhi. *Indian J. Med. Res.*, 123(2): 159–64.
- Srinivasan, M. 2004. Fungal keratitis. *Curr. Opin. Ophthalmol.*, 15(4): 321–7.
- Tuft, S.J., Tullo, A.B. 2009. Fungal keratitis in the United Kingdom 2003-2005. *Eye (Lond)*, 23(6): 1308–13.
- Upadhyay, M.P., Karmacharya, P.C., Koirala, S., Tuladhar, N.R., Bryan, L.E., Smolin, G., Whitcheer, J.P. 1991. Epidemiologic characteristics, predisposing factors, and etiologic diagnosis of corneal ulceration in Nepal. *Am. J. Ophthalmol.*, 111(1): 92–9.
- Wang, L., Sun, S., Jing, Y., Han, L., Zhang, H., Yue, J. 2009. Spectrum of fungal keratitis in central China. *Clin. Experiment Ophthalmol.*, 37(8): 763–71.
- Wong, T.Y., Fong, K.S., Tan, D.T. 1997. Clinical and microbial spectrum of fungal keratitis in Singapore: a 5-year retrospective study. *Int Ophthalmol.*, 21(3): 127–30.
- Xie, L., Zhong, W., Shi, W., Sun, S. 2006. Spectrum of fungal keratitis in north China. *Ophthalmol.*, 113(11): 1943–8.

How to cite this article:

Venkata Hemalatha Neeli and T. Parvathi. 2016. Study of Keratomycosis in a Tertiary Care Hospital in Visakhapatnam, India. *Int.J.Curr.Microbiol.App.Sci*.5(4): 351-359.
doi: <http://dx.doi.org/10.20546/ijcmas.2016.504.042>