

Original Research Article

<http://dx.doi.org/10.20546/ijcmas.2016.504.013>

Pathological Study of Oral Squamous Cell Carcinoma by Application of P53 and PCNA (Immunohistochemical Approach)

Susan N.Abdulkadir^{1*}, Najat R.Ali², and Najwa J. Alchalabi³

¹Azadi teaching hospital, Iraq

²Collage of Dentistry, Kirkuk University, Iraq

³Bagdad Medical City, Iraq

**Corresponding author*

ABSTRACT

Keywords

Oral Squamous Cell Carcinoma, PCNA, Immuno-histochemical.

Article Info

Accepted:

09March 2016

Available Online:

10 April 2016

Carcinogenesis is a multi-step process involving the activation of oncogenes and inactivation of tumor suppressor genes. Tumor cell growth results from disturbance in the balance between the rate of proliferation and cell death apoptosis. Apoptosis is an active process of cell destruction that requires the activation of a genetic program that may lead to changes in cell morphology, DNA fragmentation, and protein cross-linking. The mechanism of apoptosis provides protection from the possible consequences of uncontrolled cell proliferation which could lead to neoplasia. The aim of this study was to determine the immunohistochemical expression of the P53 and PCNA in oral squamous cell carcinoma. Twenty specimen of oral squamous cell carcinoma were selected for analyses by using the Avidin-biotin complex (ABC) detection system with antibodies against P53 and PCNA it was observed positive labeling for P53 in 19 cases (95%) and one case (5%) was negative and for PCNA however there was a positive labeling in 19 cases (95%) while one case (5%) was negative. It was concluded that distribution of immune reactivity for P53 was observed to be similar to that of PCNA. There appears to be a relationship between P53 and PCNA expression with all malignancy grading. Expression of P53 and PCNA at oral SCC has a prognostic significance. PCNA expressions have been associated with biologically aggressive tumors. PCNA is a good indicator for detecting malignant potentiality in all grades OSCC.

Introduction

Squamous Cell Carcinoma

Early squamous cell carcinoma often presents as a white patch (leukoplakia), red patch (erythroplakia), or a mixed red and white lesion (erythroleukoplakia). With time, a superficial ulceration of the mucosal surface may develop.

As the lesion grows, it may become exophytic mass with a fungating or papillary surface, other tumors have an endophytic growth pattern that is characterized by a depressed, ulcerated surface with a raised, rolled border (Silverman, 1998, Neville, 2002). Pain is not a reliable indicator as to whether a particular lesion may be malignant; larger, advanced carcinomas will

often be painful, but many early oral cancers will be totally asymptomatic or may be associated with only minor discomfort (Neville, 2002a).

The most common site for intraoral carcinoma is the tongue, which accounts for around 40 percent of all cases in the oral cavity proper. These tumors most frequently occur on the posterior lateral border and ventral surfaces of the tongue. The floor of the mouth is the second most common intraoral location. Less-common sites include the gingiva, buccal mucosa, labial mucosa, and hard palate (Neville, 2002a). Oropharyngeal carcinomas have a clinical appearance that is similar to cancers found in the oral cavity proper. Such tumors often arise on the lateral soft palate, tonsillar region and may originate from the base of the tongue. Unfortunately, such tumors are typically larger and more advanced at the time of discovery than are more anterior cancers of the oral cavity (Silverman, 1998; Neville, 2002). Presenting symptoms often include difficulty in swallowing (dysphagia), pain during swallowing (odynophagia), and pain referred to the ear (otalgia) (Neville, 2002).

P53

P53 is located on short arm of chromosome 17 at 17p13.1. It functions primarily to arrest the cell cycle for DNA repair. Ultimately, if repair is unsuccessful P53 is one of the leading signals causing cells to engage in programmed cell death, or apoptosis, via a number of complex cellular signaling pathways (Raymond, 2009). Mutations to P53 are one of the most frequent abnormalities in head and neck cancers cell lines and tissue specimens. Prognostic significance of P53 mutation has been reported. For example, node-negative oral squamous cell carcinoma patients with

P53 over expression were found to have poorer survival (Raymond, 2009).

PCNA

Proliferating cell nuclear antigen (PCNA) is an acidic intra nuclear 36-kd polypeptide linked to cell cycle. Its distribution in the cell cycle increases during the G1-phase, peak at the G1/S-phase interface, and decreases through the G2-phase, reaching low levels which are virtually undetectable by immunohistochemical methods in the M-phase and quiescent cells. As PCNA is detected in its peak distribution, it can be useful marker for proliferating cells (Celise, Celis, 1985; Kurki, Ogata, Tan, 1988 and Tsai, Jin, 1995).

PCNA plays an essential role in DNA replication and has been suggested as a marker for proliferating cell (Hall and Levioson, 1990).

In fact P53 may act as a complimentary marker to PCNA reactivity defines the growth fraction of a tumor and P53 reactivity demonstrates the irreversible malignant change having occurred inside this fraction (Mighell, A 1995).

Studies shown that PCNA activity was present in the invasive margins of all the conventional grades of oral SCC. Thus assessments of PCNA labeling at the invasive margins may provide a better evaluation of tumor growth potential that may relate to prognosis and treatment of the tumor (Ohki, 2001).

Materials and Methods

This is a retrospective study, which was done by archival paraffin-embedded tissue blocks along with the histopathological reports for twenty cases with oral Squamous

cell carcinoma which were obtained from the Department of Surgical Pathology that belongs to the Hospital of AL-SHAHEED GHAZY for Specialized Surgery, in the period from January 2009 to December 2009.

Hematoxylin and Eosin stained sections were made from paraffin blocks of 5 micrometer thickness. Microscopical review of tissue sections was done.

Immunohistochemical Staining Study

Materials

The primary monoclonal antibody used in this study for P53 and PCNA is presented in liquid/ml. This antibody reaction is specific for P53 and PCNA.

Avidin-biotin complex (ABC) detection system was used in this study.

The intranuclear precipitate was visualized as brown color, and was purchased from DAKO. (DAKO COMPANY).

Methods of Immunohistochemical Assays

The following steps were applied:

Section were cut at 3 micrometer thickness from formalin-fixed, paraffin – embedded tissues blocks and prepared on coated slides. De-paraffinization by heating the slides in an oven at 60 c° for 30 minutes, tissue sections were dewaxed in two changes of xylene for 5 minutes each.

Rehydration through a descending ethanol series, two changes of absolute ethanol for 1 minute each and in 90%, 80%, 70% ethanols for 1 minute each.

Immersed in distilled water for 1 minute.

Immersed in phosphate buffer saline (PBS) for 1 minute.

Immersed in retrieval solution citrate buffer, for 15 minutes then sections were cooled for 10 minutes, and then rinsed in phosphate buffer saline for 2 minutes.

The excess buffer was tapped and wiped around sections by gauze, make around sections by pap pen.

Enough blocking reagent was applied and incubated for 5 minutes.

Tapped of excess blocking reagent.

Primary antibody was applied in dilution (1:50) and incubated for 2 hours at room temperature.

The slides were washed by PBS and sections were wiped around.

Secondary antibody was applied and incubated for 10 – 20 minutes.

Section were washed in PBS for 2 minutes, and then wiped around it.

Strept avidin – peroxidase was applied incubated for 10 – 20 minutes followed by washing with PBS and wiped around sections.

The immune recipient was visualized by polyvalent biotinylated antibody and then we incubated the section for 10 minutes an enclosed (dark field) container, followed by washing and wiping with PBS.

The sections were washed in distilled water.

Counter stained with hematoxylin for 1 minute then washed in distilled water, and then mounted with DPX.

Scoring

Staining was measured as the percentage of positively stained nucleus, and assigned to four categories as follows.

NE = No Expression.

+ = Weak Expression $0 \leq 25$

++ = Moderate Expression $26 \leq 50$

+++ = Strong Expression $51 \leq 100$

Statistical Analysis

Balanced ANOVA test (Minitab Inc. 2003. MINITAB Statistical software, Release 14 for Windows, State College, Pennsylvania).

chi-square test.

SPSS version 13.

P-value of less than 0.05 is regarded as statistically significant result.

Results and Discussion

Age Distributions

The age of patients ranged from 10 to 80 years and the mean 45 years, most of cases were in 61-70 years age group, so there is 7 (35%) cases and there 5 (25%) were found in 51-60 years age group and 3 (15%) were found in 41-50 years age group while the other cases were divided between the other age groups. Statistical analysis revealed significant difference P value <0.05 .

Histopathology and Grade of Tumor

According to WHO grading system in the oral squamous cell carcinoma there was 7 (35%) cases well differentiated tumor and 13 (65%) cases is moderately differentiated while there are no cases in poorly differentiated tumor. Statistical analysis revealed no significant difference P value

>0.05 .

P53 and PCNA Immunohistochemistry and Oral Squamous Cell Carcinoma

P53

There were 19 (95%) cases which were positive for this marker while other 1 (5%) case was negative as shown in table (1), Statistical analysis revealed no significant differences (P value >0.05).

PCNA

There were 19 (95%) cases which were positive for this marker while other 1 (5%) case was negative as shown in table (2), Statistical analysis revealed no significant differences (P value >0.05).

P53 and PCNA Immuno-reactive Staining in Relation to Intensity (Scoring)

P53

There was one (5%) case negative, 9 (45%) cases were moderate positive and 10 (50%) cases were strongly positive as shown in table (3) and figure (1), Statistical analysis revealed no significant difference P value >0.05 .

PCNA

Regarding oral squamous cell carcinoma 1 (5%) case was negative, 1 (5%) case weak positive and 18 (90%) cases were strongly positive as shown in table (4) and figure (2), Statistical analysis revealed no significant difference P value >0.05 .

P53 and PCNA Immunohistochemical Expression Relation to Age Group

P53

Positivity of this marker is increased in

frequency of age. Only 1(5%) case was positive in 10-20 years age group, 2 (10%)cases were positive in (31-40) years age group, 3(15%) cases were positive in (41-50) years age group, 5(25%) cases were positive in (51-60) years age group, 7(35%) cases were positive in (61-70) years age group, 1(5%) case was positive in (71-80) years age group and the marker was negative in only one case in (21-30) years age group, Statistical analysis revealed no significant difference P value > 0.05.

PCNA

Positivity of this marker is increased in frequency of age. Only 1(5%) case was positive in 10-20 years age group, 2 (10%)cases were positive in (31-40) years age group, 3(15%) cases were positive in (41-50) years age group, 5(25%) cases were positive in (51-60) years age group, 7(35%)

cases were positive in (61-70) years age group, 1(5%) case was positive in (71-80) years age group and the marker was negative in only one case in (21-30) years age group, Statistical analysis revealed no significant difference P value > 0.05.

P53 and PCNA Immunohistochemical Expression and Grade of Tumor

P53

Out of 20 cases of oral squamous cell carcinoma 7 (35%) cases well differentiated carcinoma were positive, 12 (60%) cases were positive in moderately differentiated tumor while only one case of moderately differentiated tumor was negative, Statistical analysis revealed no significant difference P value > 0.05.

Table.1: SP53 Expression in Oral Squamous Cell Carcinoma

Histological type of tumors	P53 expression				Total
	Positive	Percentage	Negative	Percentage	
oral squamous cell carcinoma	19	95%	1	5%	20
Total	19		1		20

P = 0.127 (P > 0.05 Not significant)

Table.2 PCNA Expression in Oral Squamous Cell Carcinoma

Histological type of tumors	PCNA expression				Total
	Positive	Percentage	Negative	Percentage	
oral squamous cell carcinoma	19	95%	1	5%	20
Total	19		1		20

P = 0.127 (P > 0.05 Not significant)

Table.3 The Intensity of P53 Immune Reactive Staining in Oral Squamous Cell Carcinoma

Type of tumor	Intensity of P53								Total
	-ve	%	Weak +ve	%	Mod.+ve	%	Strong +ve	%	
oral squamous cell carcinoma	1	5%	Zero	----	9	45%	10	50%	20
Total	1				9		10		20

P = 0.097 (P >0.05 Not significant)

Table.4 The Intensity of PCNA Immune Reactive Staining in Oral Squamous Cell Carcinoma

Type of tumor	Intensity of PCNA								Total
	-ve	%	Weak +ve	%	Mod. +ve	%	Strong +ve	%	
oral squamous cell carcinoma	1	5%	1	5%	zero	----	18	90%	20
Total	1		1				18		20

P = 0.087 (P >0.05 Not significant)

Figure.1 The Intensity of P53 Immune Reactive Staining in OSCC

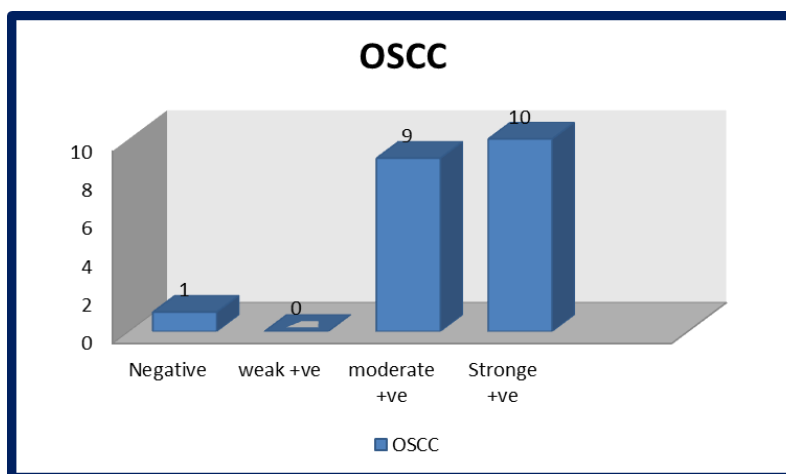


Figure.2 The Intensity of PCNA Immune Reactive Staining in OSCC

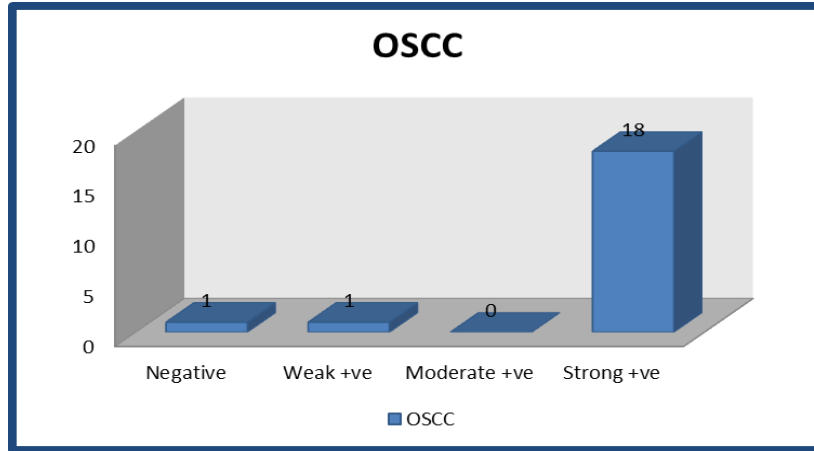


Figure.3 Well Differentiated OSCC, P53 Staining (Moderately Positive), A. Power X10, B. Power x20 and D. Power x40

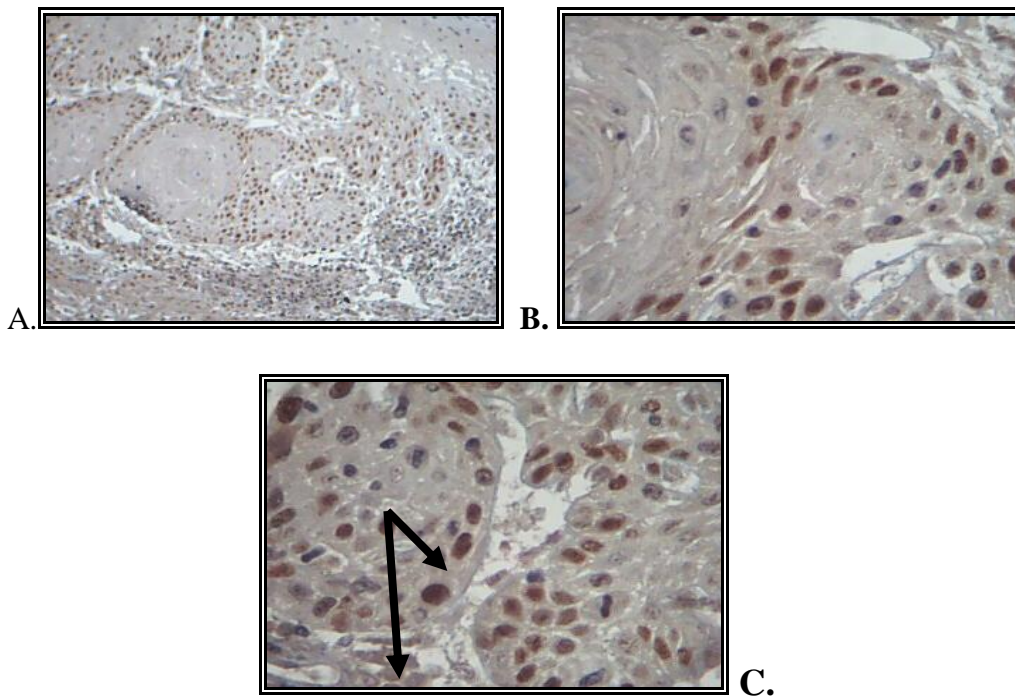
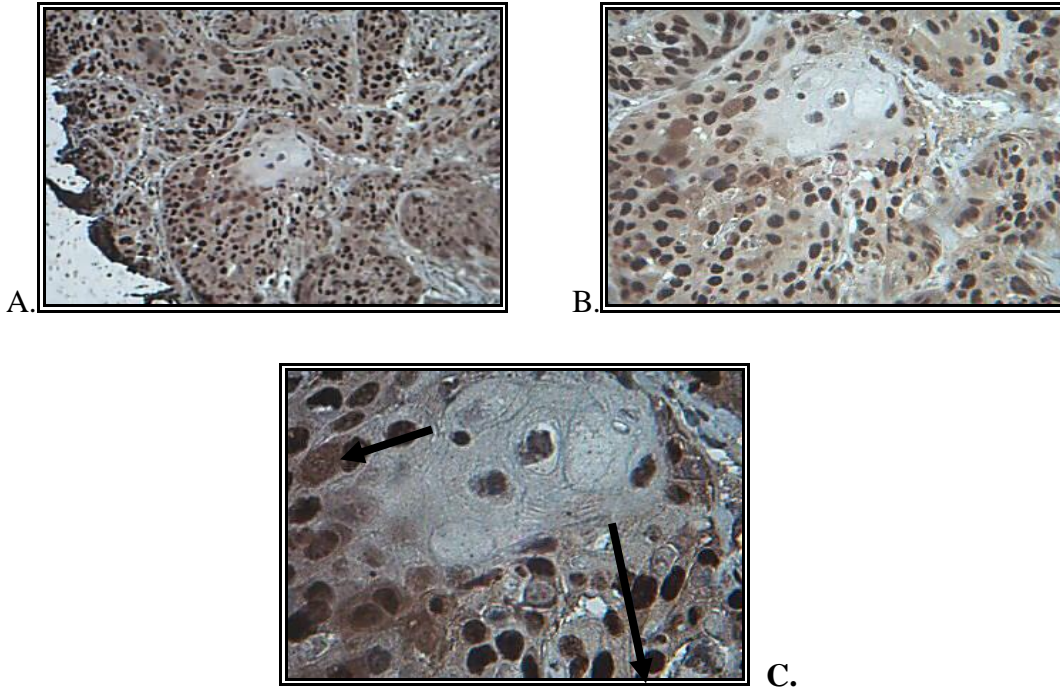


Figure.4 Well D SCC, PCNA Staining (Strong Positive), A. Power X10, B. Power x20 and D. Power x40



PCNA

Out of 20 cases of oral squamous cell carcinoma 7 (35%) cases well differentiated carcinoma were positive, 12 (60%) cases were positive in moderately differentiated tumor while only one case of moderately differentiated tumor was negative, Statistical analysis revealed no significant difference P value > 0.05.

P53 is a nuclear protein; it is a tumor suppressor gene located on short arm of chromosome 17 and is the most commonly mutated gene in tumors (Ohki, 2001). PCNA is also a nuclear protein that plays an important role in DNA synthesis, with a significant participation in cell replication. (Zhu 1997)

This study show, the peak age incidence of oral squamous cell carcinoma were between 61-70 years (35%) which is agree with (Regezi *et al.*, 1999; Scully and Porter and

Neville & Day, 2002; Regezi, 1999; Scully 2000)

In this study the expressions of both markers P53 and PCNA were positive in 19 cases (95%) out of 20 cases. Since tumor cell growth results from disturbance in the balance between the rate of proliferation and cell death apoptosis (Neville BW 2002a), so that distribution of immune reactivity for P53 was observed to be similar to that of PCNA.

Regarding the intensity of P53 staining in oral squamous cell carcinoma we have 19 (95%) cases out of 20 cases of OSCC were positive, 9 (45%) of them is moderately positive and 10 (50%) cases were strongly positive while there is only one case was negative this is agree with (Cristiana Simionescu, CL. Margaritescu, Claudia Valentina Georgescu, M. Surpateanu) (Cristiana Simionescu, 2005) regarding the intensity of PCNA staining in oral squamous

cell carcinoma we have 19 (95%) cases out of 20 cases of OSCC were positive, one (5%) case was weakly positive and 18 cases were strongly positive while there is only one cases was negative, the strong labeling explain a greater proliferative activity of these tumors and this is agree with (Fernanda C.G. Sampalo-Goes, PhD, Denise T. Oliveira, PhD, Regina G. Dorta, PhD; *et al.*, 2005; Fernanda C. G. Sampalo-Goes 2005).

P53 expression was more frequent in patients (61-70) years so we have 7 (35%) cases out of 20 cases of OSCC

Also the PCNA was more frequent in OSCC as we have 7 (35%) cases out of 20 cases in (61-70) years

These results agreed with (Giuseppe Russo, Alessandra Zamparelli, Canadace M. Howard, *et al.*, 2005; Giuseppe Russo, Alessandra Zamparelli 2005)

The present study graded the tumors in this study according to WHO grading system, so for P53 expression in OSCC we have 7 (35%) cases out of 20 cases in well differentiated grade showed positive and 12 (60%) cases in moderately differentiated grade and we have only one case negative in moderately differentiated carcinoma which is disagree with (S Kannan, *et al.*, 1996) (S Kannan, 1996). Because the size of sample in his study is differ from the size of samples in this study

PCNA results showed positive in 7 (35%) cases which were well differentiated out of 20 cases in OSCC and we have 12(60%) cases were moderately differentiated tumors which are also positive and we have only

one case negative in moderately differentiated carcinoma which is agree with (RB ZAIN, 1995) (RB ZAIN, 1996).

In conclusion, distribution of immune reactivity for P53 was observed to be similar to that of PCNA. There appears to be a relationship between P53 and PCNA expression with all malignancy grading. Expression of P53 and PCNA at oral SCC has a prognostic significance. PCNA expressions have been associated with biologically aggressive tumors. PCNA is a good indicator for detecting malignant potentiality in all grades OSCC.

References

- Celise, J.E., Celis, A. 1985. Cell cycle-dependent variations in the distribution of the nuclear protein cyclin proliferating cell nuclear antigen in cultured cells: subdivision of S phase. *Proc. Natl. Acad. Sci.*, 82(10): 3262–6.
- Cristiana Simionescu, C.L. 2005. Margaritescu, Claudia Valentina Georgescu, M. Surpateanu: HPV and P53 expression in dysplastic lesions and squamous carcinomas of the oral mucosa. *Romanian J. Morphol. Embryol.*, 46(2): 155–159.
- Fernanda, C.G., Sampalo-Goes, PhD, Denise, T., Oliveira, PhD, Regina, G., Dorta, PhD, *et al.* 2005. Expression of PCNA, P53, BAX, and BCL-X in oral poorly differentiated and basaloid squamous cell carcinoma: Relations with prognosis. Wiley inter Science, 27: 982–989.
- Giuseppe Russo, Alessandra Zamparelli, Canadace, M., Howard, *et al.* 2005. Expression of cell cycle- Regulated proteins pRB2/p130, P107, E2F4, P27, and PCNA in salivary gland tumors: prognostic and diagnostic implications. *Clinic Cancer Res.*, 11: 3265–3273.

- Hall, P.A., Levioson, D.A., Woods, A. L., Yu, C.C.W., Kellock, D.B., Watkins, J.A., Barnes, D.M., Gillett, C.E., Camplejohn, R., Dover, R., Waseem, N.H., Lane, D.P. 1990. Proliferating cell nuclear antigen (PCNA) immunolocalization in paraffin section: An index of cell proliferation with evidence of deregulated expression in some neoplasm. *J. Pathol.*, 285–294.
- Kannan, S., Jahadeesh Chandran, G., Raveendran Pillai, K., *et al.* 1996. Expression of P53 in Leukoplakia and squamous cell carcinoma of the oral mucosa: correlation with expression of Ki67. *J. Clin. Pathol., Mol. Pathol.*, 49: M170–M175.
- Kurki, P., Ogata, K., Tan, E.M. 1988. Monoclonal antibodies to proliferating cell nuclear antigen (PCNA)/ cyclin as probes for proliferating cell by immunofluorescence microscopy and flow cytometry. *J. Immunol. Methods*, 109(1): 49–59.
- Mighell, A. 1995. PCNA and P53. *Oral Oncol. Eur. J. Cancer*, 31B(6): 403–404.
- Neville, B.W., Damm, D.D., Allen, C.M., *et al.* 2002a. Oral & maxillofacial pathology. 2nd ed. Phila., PA: Saunders, 337–369.
- Neville, B.W., Terry, A., Day, *et al.* 2002b. Oral cancer and precancerous lesions. *CA Cancer J. Clin.*, 52: 195–215.
- Ohki, K., Kumamoto, H., Ichinohasama, R., Suzuki, M., Yamaguchi, T., Echigo, S., Motegi, K., Ooya, K. 2001. Genetic analysis of DNA microsatellite loci in salivary gland tumors: comparison with immunohistochemical detection of hMSH2 and P53 proteins. *Int. J. Oral Maxillofac. Surg.*, 30: 538–44.
- Raymond, J. 2009. Fonseca: Oral and maxillofacial surgery. 2nd ed. United States: Saunders Elsevier, 707.
- Regezi, J.A., Dekker, N.P., McMillan, A., Ramirez-Amador, V., Meneses-Garcia, A., Ruiz-Godoy Rivera, L.M., Chrysomali, E. 1999. Ng, I. O. L. P53, P21, Rb, and Mdm2 proteins in tongue carcinoma from patients <35 versus > 75 years. *Oral Oncol.*, 35: 379–83.
- Scully, C., Porter, S. 2000. *Oral Cancer, BMJ*, 321: 97–100.
- Silverman, S., Jr, Dillon, W.P., Fischbein, N.J. 1998. Diagnosis In: Silverman S Jr ed. *Oral Cancer*, 4th ed. Hamilton, Ontario, Canada: BC Decker Inc, 41–66.
- Tsai, S.T., Jin, Y.T. 1995. Proliferating cell nuclear antigen (PCNA) in oral squamous cell carcinomas. *J. Oral Pathol. Med.*, 24(7): 313–5.
- Zain, R.B., Sakamoto, F., Shrestha, P., Mori, M. 1995. Proliferating cell nuclear antigen (PCNA) expression in oral squamous cell carcinoma – an aid to conventional histological grading. *Malaysian J. Pathol.*, 17(1): 23–30.
- Zhu, Q., White, F.H., Tipoe, G.L. 1997. The assessment of proliferating cell nuclear antigen (PCNA) immunostaining in human benign and malignant epithelial lesions of the parotid gland. *Oral Oncol.*, 33: 29–35.

How to cite this article:

Susan N. Abdulkadir, Najat R. Ali, and Najwa J. Alchalabi: 2016. Pathological Study of Oral Squamous Cell Carcinoma by Application of P53 and PCNA (Immunohistochemical Approach). *Int.J.Curr.Microbiol.App.Sci* 5(4): 91-100.
doi: <http://dx.doi.org/10.20546/ijcmas.2016.504.013>