

Case Study

<https://doi.org/10.20546/ijcmas.2021.1003.194>

## A Case Report on, the Cat Fur Mite *Lynxacarus radovskyi* in Puducherry, India

P. Thiruselvame, R. Sreekrishnan and C. Mathivathani\*

Department of Veterinary Parasitology, Rajiv Gandhi Institute of Veterinary Education and  
Research (RIVER), Puducherry, India

\*Corresponding author

### ABSTRACT

#### Keywords

*Lynxacarus radovskyi*, Cat, Fur mite, Puducherry

#### Article Info

Accepted:  
12 February 2021  
Available Online:  
10 March 2021

A 10 year old female Persian cat was presented to a private pet clinic in Puducherry with a complaint of itching. Upon examination of hair samples under microscope, revealed the presence of eggs attached to hair and cat fur mite *Lynxacarus radovskyi* clinging onto the hairs. Fipronil spot on was used to treat successfully.

### Introduction

The domestic cat, *Felis catus* is undoubtedly a loved pet by all animal lovers. They are well-liked for its smooth soft fur. Maintaining fur's beauty and softness usually has been taken care of by the cat themselves by constant grooming. An ectoparasite infestation in cat can be a serious nuisance apart from the loss of beauty and smoothness of its fur. As in tropical country like India, ectoparasite infestation is very common due to its favorable climatic conditions. Ectoparasite-infested pets has unpleasant social effects and may be a source of infestation of the pet owners too. There are various ectoparasites

that have been reported on domestic cats like fleas, mites, louse etc.

The cat fur mite belonging to genus, *Lynxacarus* was described by Radord in 1951 from samples collected from a lynx cat in USA. There are various reports on detection of this mite worldwide. These mites are found clinging on the fur, where the eggs are also found to be attached and so it is called cat fur mite.

The cat fur mites are less than half a millimeter in length. The larvae, nymphs and adult possess sternal plates and anteriorly directed bridge on the propodosomal plate.

Foley (1991) reported that the mites were most commonly found on the tail head, tail tip and perineal area. As per reports, the small mites could be easily identified by its laterally compressed body and its characteristic grasping of the hair shaft between the gnathosoma and palpi. (Craig *et al.*, 1993)

### Materials and Methods

A 10 year old female Persian cat was presented to a private pet clinic in Puducherry with a complaint of itching in 2014. Few hair samples were collected and examined under microscope revealed the presence of *L. radovskyi* adult and its egg. The presence of eggs (Fig. 2) attached to hair, adult cat fur

mite *Lynxacarus radovskyi* clinging onto the hairs (Fig. 1 and 3) and eggs with developing mite (Fig 4) was observed.

### Results and Discussion

Based on reports, *L. radovskyi* was found to be susceptible for commonly used acaricides and treated successfully. This case was treated with Fipronil (PROTECTOR\*) spot on and found that the animal has recovered during the follow up. This case of fur mite is found to be the first report of this parasite in Puducherry region. Ectoparasite infestation on pet animals can be easily controlled with better management practices.

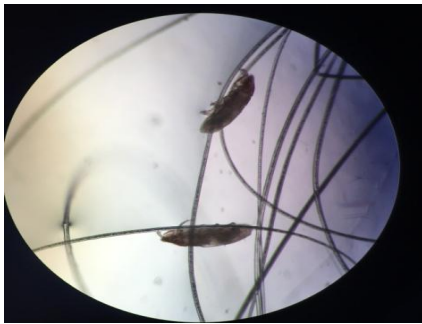

Fig 1. *Lynxacarus radovskyi* adults clinging onto the hairs

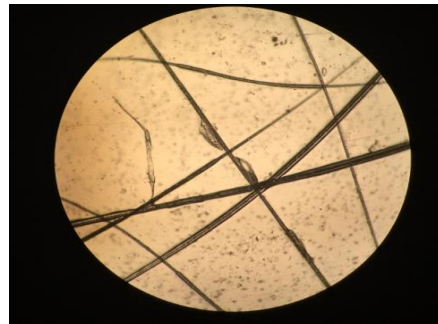

Fig 2. Eggs found attached to hairs of the host




Fig 3

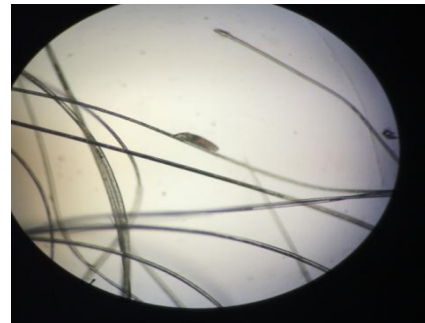

Fig 4 Egg with developing mite

Treatment and control of ectoparasites using chemicals i.e. acaricides and insecticides is still promising with certain parasites. Incidences of unusual parasites are increasing as far as pet animals are concerned.

### References

Craig T.M, Teel P.D, Dubuisson L.M., Dubuisson R.K. 1993. *Lynxacarus radovskyi* infestations in a cat

J.Am.VetMed. Assoc 202 (4); 613-614  
Foley, R.H. 1991. An epizootic of a rare fur mite in an Island's cat population. Fel.Pract. 19: 17-19  
Tenorio, J.M., 1974. A new species of

*Lynxacarus* (Acarina: Astigmata: Listro) from *Felis catus* in the Hawaiian Islands. J. Med. Ent 11: 599-604

**How to cite this article:**

Thiruselvame, P., R. Sreekrishnan and Mathivathani, C. 2021. A Case Report on, the Cat Fur Mite *Lynxacarus radovskyi* in Puducherry, India. *Int.J.Curr.Microbiol.App.Sci.* 10(03): 1563-1565. doi: <https://doi.org/10.20546/ijcmas.2021.1003.194>