

Original Research Article

<https://doi.org/10.20546/ijcmas.2021.1003.256>

Effect of Di-ammonium Phosphate on Histopathology of Some Vital Organs in Climbing Perch *Anabas testudineus* (Bloch.)

Arti Kumari^{1*} and Deep Gupta²

Department of Zoology, C.M.Sc. College, L.N.M.U., Darbhanga, India

*Corresponding author

ABSTRACT

Keywords

Di-ammonium phosphate, *Anabas testudineus*, Histopathology, Fertilizer, Pollutant

Article Info

Accepted:
18 February 2021
Available Online:
10 March 2021

The current study includes the histopathological alterations induced by chronic (20 days) exposure of the fish *Anabas testudineus* to a sublethal concentration (0.092 g/L) of inorganic fertilizer, Di-ammonium phosphate. Some vital organs were taken for the study that is kidney, liver, intestine, testis and ovary. The present study showed major histopathological alteration like vacuolar degenerative changes, necrosis etc. found in liver, intestine, testis, ovary and kidney organs dysfunction in response to DAP toxicity effect in the fish *A. testudineus*. So, it is suggested that more suitable to culture at water fertilizer, Di-ammonium phosphate concentration of < 0.092 g/l for optimum growth performance. The information will be major role on different levels of responses of organisms with respect to pollutant stress is a necessary pre-requisite for the proper management of fertilizer application in agriculture and aquaculture.

Introduction

The Rainfall washes away fertilizers and other agricultural chemicals from widespread area. Natural waters are the ultimate recipients of fertilizer residues used for agricultural purposes which are transferred from land to water. Aquatic organism can survive in very low concentrations of the pollutants. But when these concentrations increased abnormally, they become fatal to the sensitive organisms like fishes (Awasthi *et al.*, 2008).

Nitrogen pollution from agricultural sources is now considered to be a major problem in many regions of the world (Vidal *et al.*, 2000). The aquatic organisms are sensitive to environmental changes. Sub-lethal concentrations of fertilizers may cause ecological imbalance of these organisms after sufficiently long time of exposure probably as a result of cumulative impact of impaired metabolic functions (Abedi *et al.*, 2013). There is lacking in tissue level study of fertilizer pollution effects on aquatic fauna in

such past review of literature. Histopathological studies on aquatic fauna are a noteworthy and promising field to understand the structural organization that occurs in the organs due to pollutants in the environment. These structural changes vary with the body parts, nature of the pollutant, medium and duration of exposure. Water physio-chemical characteristics also influence histopathological manifestations of toxic effects (Galat *et al.*, 1985).

Anabas testudineus(Bloch.), locally known as “kawai”, which is an integral part of paddy field culture on this subcontinent, is also subjected to severe ammonia toxicity from ammonium fertilizers during the intensive fertilization of the crop fields.

Hence, in this paper efforts have been made to illustrate the histopathological alterations induced by this inorganic fertilizer, di-ammonium phosphate on the liver, kidney, intestine and gonads toxicity impact on air breathing teleost, *Anabas testudineus*.

Materials and Methods

The air-breathing teleost *Anabas testudineus* (Bloch.) procured and brought in container live from the local fish market, Darbhanga were washed with 0.1% KMnO₄ solution to remove dermal infection if any.

Healthy fish of average length (10–12cm) and weight (30–34 g) were acclimated for 15 days to laboratory conditions. Commercial diet containing 28.58% crude protein was used through the experiment period with daily ration rate 3% of fish weight in the in morning (10.00 AM). Running tap water was used in all the experiments and the fish were adjusted to natural photoperiod and ambient temperature. No aeration was done and follows the methods of APHA (1985). Static acute bioassays were performed to determine

LC₅₀ values of Di-ammonium phosphate, the mortality was recorded after 24, 48, 72 and 96 hr, and were calculated by the Finney method (1978). The LC₅₀ values for these periods were 1.10 g, 1.0 g, 0.97 g and 0.92 g respectively. 1/10th value of the LC₅₀ value for 96 hr was taken as the sublethal concentration (Sprague, 1971). Twenty acclimated fish were exposed to a sub-lethal concentration (0.092 g) of Di-ammonium phosphate for 20 days. Side by side same number of fish as that of experimental one was maintained as the control groups. At the end of exposure period the fish were anaesthetized with 1:4000 MS 222 (tricane, methane, sulfonate, sandoz) for two minutes. On 20th day fish were taken out, sacrificed and the liver, intestine, kidney, testis and ovary were excised out and fixed in 10% Neutral Buffered Formalin for 18-24 hours fixed tissue samples were then processed and paraffin embedded tissue blocks were cut into serial sections (5-7 μ thick) by a rotary microtome and all the tissues was prepared using the standard histological methods (Luna, 1968), stained with Haematoxylin and Eosin and microphotographs were taken.

Results and Discussion

Histopathology

Tissue samples liver, kidney, intestine, testes and ovary of *A. testudineus* were treated with sublethal di-ammonium phosphate concentration 0.092 g/l at 20 day after sacrificed and processed by conventional method, sectioned at 5-7 μm and stained with Haematoxylin and Eosin (Luna 1968) and microphotographs were taken showed following major significant results

Liver

Histology of control fish groups were in normal structure. The liver is composed of

hepatic lobule in which the central vein obscure. The parenchyma of the hepatic lobule is formed from hepatocytes which are arranged around the blood sinusoid in cord-like structure known as hepatic cell cord. There are bile ductile in between the cord of hepatic cells which are directed toward the periphery of the lobule to open in the bile duct (Figure 1A). *Anabas testudineus* exposed to sub-lethal concentrations of DAP- 0.092 g/L for 20 days showed varied degree of hepatic cirrhosis as evidenced by vacuolization, space formation and resulting haemorrhage, vacuolar degeneration, necrosis, hyperemia and mononuclear cells filtration in portal regions were observed (Figure 1B).

Kidney

The fish kidney consists of head and body kidneys. The head kidney is the anterior portion of the kidney and consists of lymphoid tissue. The epithelium becomes lower and more cuboidal in the intermediate segment. The distal convoluted tubules have epithelium with lightly eosinophilia and have no brush border (Figure 2A), and kidneys displayed glomerulonephritis, vacuolar degenerative changes in the tubular epithelium and slight congestion (Figure 2B).

Intestine

The intestinal wall of control fish, *A. testudineus* comprised of four distinct layers, viz. mucosa, submucosa, muscularis and serosa. The mucosal layer being thrown into finger like villi, which is made up of simple, long columnar cells and numerous goblet cells (mucous cells) with centrally placed nuclei. Sub-mucosa is thin and projected into mucosal folds constituting the lamina propria. This layer is composed of loose connective tissue with numerous collagen fibres and blood cells. Muscularis consists of inner, thick, circular, and outer, thin, longitudinal muscular layers.

Serosa is formed of peritoneal layer and blood capillaries (Figure 3A). In DAP exposed, marked histopathological changes in the intestine of *A. testudineus* have been observed in intestinal tissue, hydropic degeneration, necrosis and desquamation in epithelium cells at the apex of the villi were determined and mononuclear cell infiltration in the lamina propria was slightly observed (Figure 3B).

Testes

Histology of normal testes shows the presence of healthy seminiferous tubules, which is internally lined by tubular epithelium which gives rise to spermatocytes. Testis of control fish were composed of lobules showing active spermatogenesis. Sperm nests were found in majority of lobules (Figure 4A). Fish exposed to sub-lethal concentrations of DAP-0.092 g/L for 20 showed considerable degree of alteration in the histology of testes. In testes the seminiferous tubules are normally of varying shapes and sizes, each tubule has a definite thin fibrous wall which is not distinguished after spawning. It shows reduction in the number and condensation of spermatogonic cells as well as inflammation of cells, contraction and vacuolation of tubules (Figure 4B).

Ovaries

Histology of control fish have thick ovarian wall with increased vascular supply and conspicuous blood capillaries. The connective tissue in the stromal was evident in good volume. The germ cells become associated with small epithelial cells more into cortex. The associated epithelial cells multiply and surround the germ cell which is now called oocyte developing into the stage I, stage II, stage III etc. and they will develop into the mature ovum which is nourished by the surrounding follicular cell (Figure 5A). The present investigation was undertaken to study

the histopathological changes occurring in the ovary of *Anabas testudineus* after exposure to sublethal dose of DAP- 0.092 g/L.

Follicular cells are disrupted. Nucleolus shows condensation of crescent shaped dark granules at one side. Degeneration of epithelial cells causes vacuolation, breakdown of germinal vesical, many disrupted oogonia are the changes caused due to the exposure of ovary of *A. testudineus* to sublethal dose of DAP showing in (Figure 5B).

The liver of *A. testudineus* in the present study showed group exposed to the DAP showed hyperplastic hepatic and necrosis of hepatic cells. Similar observations were made in findings by Kalaiyarasi,(2017). Liver is the major metabolic center and any damage to this organ would subsequently do, so many physiological disturbances leading to subsequent mortality of fish (Mishra and Poddar (2016).

The Necrosis in the liver could be due to the extra work load on hepatocyte during detoxification of the cypermethrin (Ullah, *et al.*, 2015). Significant changes such as hyperplasia, disintegration of hepatic mass, and focal coagulative necrosis were found in *Labeo rohita* exposed to cypermethrin (Jee *et al.*, 2005). Tilak *et al.*, (2005) observed the similar changes in liver of *Catla catla*. Osman *et al.*, (2009) recorded congestion and hemorrhage in the hepatic sinusoids with dilation of hepatic vessels, vacuolization and degeneration of hepatic cells, due to heavy metal salts exposure.

The liver of *Clarias gariepinus* exposed to the cypermethrin showed hyperplastic hepatic and necrosis of hepatic cells (Andem *et al.*, 2016), also same effects observed in application of ammonium chloride on fish *Clarias batrachus* by Sangeeta, *et al.*, (2020). Ammonium chloride release ammonia which can be

carried by the hepatic portal vein to the liver as a nutrient and enter liver metabolic pathways (Kucuk, 1999). The above studies support the present experiment with Di-ammonium phosphate.

In our study, kidney tissues displayed glomerulonephritis and hyperemia after being exposed to different concentrations of sublethal ammonium chloride concentrations where the kidney is a one of the major organs of the toxic effects.

Thurston *et al.*, (1978) observed hydropic degeneration in the kidney of trout after exposure to 0.34 mg /l NH₃-N. Intracellular vacuolation, necrosis and shrinkage of nuclei were also apparent in the present study in di-ammonium phosphate treated *Anabas testudineus*. Nayan (2012) reported that degeneration of renal tubule epithelia, hyaline droplet degeneration, eventually may induce renal failure. Tilak, *et al.*, (2001) also reported same in *Ctenopharyngodon idellus*. The above reporting is similar to the present observation.

The intestine is the most important organs in digestion and absorption of nutrients from food, and therefore, monitoring of these organs is considered necessary (Takashima,*et al.*,1982). Histological analysis of the digestive system is considered a good indicator of the nutritional status and toxicant ingestion of fish (Caballero *et al.*, 2003).

All the pathological alterations showed a relationship with prevalence increasing with increasing di-ammonium phosphate concentration in present work. Desquamation mononuclear cell infiltration (MHI) in connective tissue was observed in treated fish at 20 days. Similar observations made by earlier workers relating to histopathological changes in intestine in response to various toxicants are being enumerated here.

Fig.1A Photomicrograph of the normal liver of control fish, *Anabas testudineus*. H. & E., 100X.

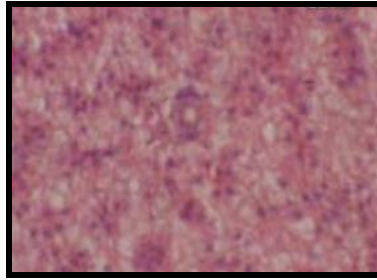


Fig.1B Photomicrograph of the liver of *Anabas testudineus* treated with DAP- 0.092 g/L for 20 days showing hemorrhagic liver tissue, blood congestion and necrotic cells. H.& E., 100X.

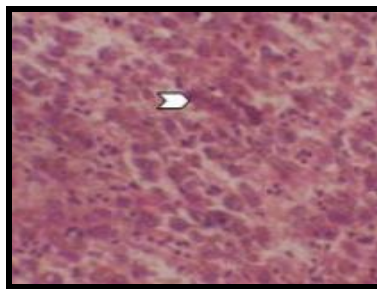


Fig.2A Photomicrograph of kidney of *Anabas testudineus* from control group showing normal. H.&E., 200X.

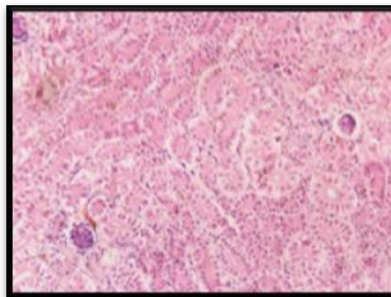


Fig.2B Photomicrograph of kidney of *A. testudineus* treated with DAP-0.092 g/l for 20 days showing degeneration of renal tubular epithelium, vacuolation and necrosis of renal tubules along with infiltration and necrosis of melanomacrophage center (arrow). H.&E., 20X.

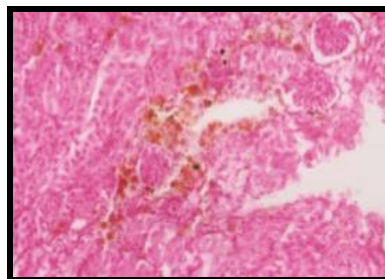


Fig.3A Photomicrograph of Intestine tissue of *A. testudineus* in control group showing normal appearance of circular muscles, longitudinal muscles, serosa and villi. H.&E., 120X.

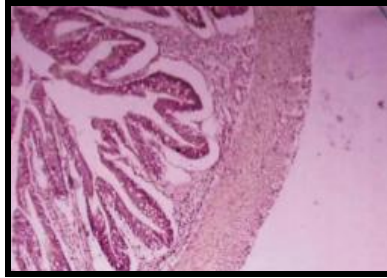


Fig.3B Photomicrograph of Intestine tissue of *A. testudineus* exposed to DAP- 0.092 g/L for 20 days showing desquamation (orange arrow) and mononuclear cell infiltration (MHI) (arrow). H.&E. 120X.

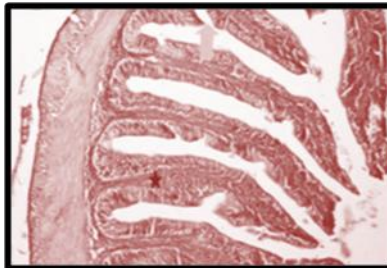


Fig.4A Photomicrograph of the testes of *Anabas testudineus* control fish showing sperm (SP), spermatogonia (SG), spermatide (ST), secondary spermatocyte (SS), primary spermocytes (PS). H.&E., 200X.

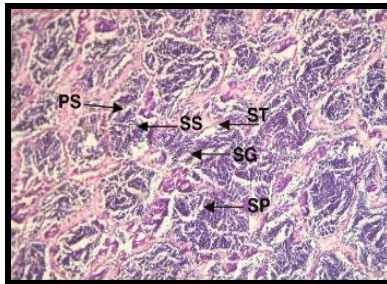


Fig.4B Photomicrograph of the testes of *Anabas testudineus* treated with DAP- 0.092 g/L for 20 days showing sperm (SP), spermatogonia condensation (SG), spermatide (ST), secondary spermatocyte vacuolation (SS). H.&E., 200x.

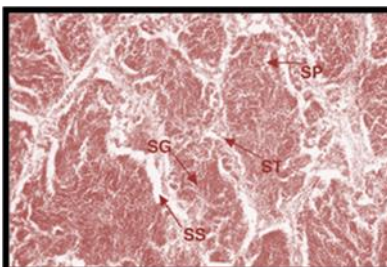


Fig.5A Photomicrograph of the ovary of *Anabas testudineus* control fish showing (OW) Ovarian wall, (FE) Follicular epithelium, (N) Nucleus, (NU) Nucleolus, (OC) Oocyte. H.&E., 200X.

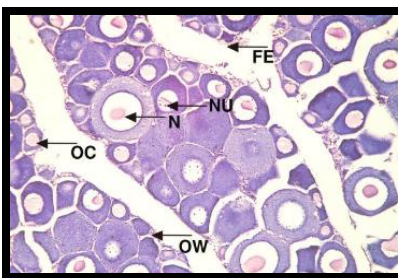
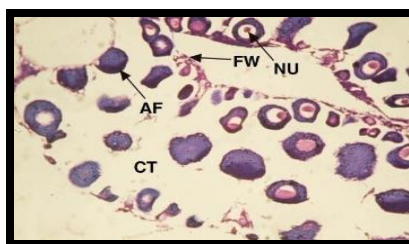


Fig.5B Photomicrograph of the ovary of *Anabas testudineus* treated with DAP- 0.092 g/L for 20 days showing (NU) Nucleolus condensed, (CT) Connective tissue degenerate (AF) Atretic follicle & (FW) Follicular wall disrupted. H.&E., 200X.



The proliferation, necrosis of serosa and mucosa and rupture of villi have been reported by Sastri and Gupta (1978) in *Channa punctatus*; Kumar and Pant (1984) in *Barbus conchoniuis*; against exposure to heptachlor, zinc and copper salt mercuric chloride, dimecron, aldicarb and furadan, respectively. The above reporting is similar to the present work. Degeneration of epithelial cells causes vacuolation, breakdown of germinal vesical, many disrupted oogonia. Maximum damage is produced exposure of DAP in the ovaries of *Anabas testudineus*.

Almost similar histological findings were reported by, Saxena and Garg (1978). The histological abnormalities in ovaries may be caused by several factors viz. ionizing radiations, electric current, parasitic infections, xenobiotic toxicants and by a variety of effluents and aquatic pollutants (Shukla *et al.*, 1984), heavy metal on *Cyprinus carpioby* Vinodhini *et al.*, (2009); fertilizer, ammonium chloride on fish *Clarias batrachus* by Sangeeta *et al.*, (2020). The above reporting is similar to the present findings.

Testicular inflammation was documented as one of the common responses in both aquatic and terrestrial animals exposed to environmental toxicants (Sokal *et al.*, 1985), in term of vacuolization of tubular cells and distortion of seminiferous cells along with inflammatory lesions. The degenerative changes in seminiferous tubules, enlarged interstitium and hemorrhage in intertubular area in albino rats exposed to pesticides have been reported (Baronia and Sahai, 1993). An identical arrest of spermatogenesis was also reported by Ahsan and Ahsan, (1974) in cadmium injected *C. batrachus*. Shyni & Sreedhar (2014) observed chronic effect of urea on testicular structure of the black clam. Zutshi (2005) observed the effect of fenthion on the testes of *Glassogobius giuris*. Lata, *et al.*, (2008) observed reduction in size with spermatids and sperms in degenerating condition, same effects observed in application of ammonium chloride on fish *Clarias batrachus* by Sangeeta, *et al.*, (2020). The above reporting is similar to the present findings. It could be concluded that *Anabas testudineus* with average weight 30.0 ± 4.0 g, exposed with

fertilizer, Di-ammonium phosphate, 0.092g/l, at histopathological observation were found the liver showed vacuolar degeneration, necrosis, hyperemia, kidneys displayed glomerulonephritis, vacuolar degenerative changes in the tubular epithelium and slight congestion, intestine showed necrosis and desquamation in epithelium cells at the apex of the villi, sperm showed very significant histopathological changes, condensation of spermatogonic cells as well as inflammation of cells, contraction and vacuolation of tubules and while ovary showed degeneration of epithelial cells causes vacuolation, breakdown of germinal vesical. So, it is suggested that more suitable to culture at water fertilizer, Di-ammonium phosphate concentration of < 0.092 g/l for optimum growth performance. The information will be major role on different levels of responses of organisms with respect to pollutant stress is a necessary pre-requisite for the proper management of fertilizer application in agriculture and aquaculture.

Acknowledgement

The authors are thankful to the Department of Zoology, C.M.Sc. College, LNM University, Darbhanga, for the provision of laboratory facilities used in this study.

References

- Ahsan, S. N. and Ahsan, J. 1974. Degenerative changes in the testis of *Clarias batrachus* (Linn) caused by cadmium chloride. *Indian J. Zool.*, 15: 39-43.
- Awasthi, S., Sriwastwa, V.M.S., Lata, S., Yadawa, A.S. and Yadawa, S. 2008. Toxicity assay of 8 carpet chemicals. *Dayanand J. Sci.*, 1: 137-143.
- Abedi, Z., Khalesi, M.K. Eskandari S.K. 2013. Biochemical and Hematological Profiles of Common carp (*C. carpio*) under sublethal Effects of Trivalent chromium. *Iran J. Toxicol.* 7: 782-792.
- APHA, 1985. Standard methods for the examination of water and waste water (16th Ed). American Public Health Assoc., Washington D.C.
- Baronia, A. K. and Sahai, Y. N. 1993. DDT induced changes in the testes of albino rat - a histopathological study. *J. Environ. Bio.*, 4(2): 153.
- Caballero M.J., Izquierdo M.S., Kjörsvik E., Montero D, Socorro J, Fernández A.J. 2003. Morphological aspects of intestinal cells from gilthead seabream (*Sparus aurata*) fed diets containing different lipid sources. *Aquaculture* ; 225:325-340.
- Finney D.J. 1978. Statistical methods in biological assay. 3rd ed. London UK: Griffin Press; p. 508.
- Galat, D.L., G. Post; T.J. Kerfe and G.R. Boucks, 1985. Histopathological changes in the gill, kidney and liver of Lohonta cut throat trout, *Salmo clarki henshawi*, living in lakes of different salinity alkalinity. *J. Fish. Biol.* 27, 533-552.
- Jee, L. H.; Masroor, F. & Kang, J.C. 2005. Responses of cypermethrin-induced stress in haematological parameters of Korean rockfish, *Sebastes schlegeli* (Hilgendorf). *Aquaculture Research*, Vol. 36, No. 9, (June 2005), pp. 898-905, ISSN 1365-2109.
- Kalaiyarasi T, Jayakumar N, Jawahar P, Ahilan B, Subburaj A. Histological changes in the gill and liver of marine spotted catfish, *Arius maculatus* from sewage disposal site, Therespuram off Thoothukudi, Southeast coast of India. *Journal of Entomology and Zoology Studies.* 2017; 5(5):1710-1715.
- Kucuk, S. 1999. The effect of diel un-ionised ammonia fluctuation on juvenile hybrid striped bass, channel catfish and tilapia. Master thesis. Mississippi State, University, Mississippi, USA.
- Kumar S., & Pant, S.C. 1984. Organal damage by Aldicarb to a freshwater teleost *Barbus conchoniis* Hamilton. *Bull Environ Contam Toxicol.* 33:50-55.
- Lata, S., Sriwastwa, V.M.S., Maurya, J.P. and Chaudhary, S.K. 2008. Urea induced testicular changes in *Mystus vittatus*. *J. Eco. Biol.*, 23:11- 17.
- Luna, G. 1968. Manual of histologic staining methods of the Armed Forces Institute of

- Pathology, 3rd Edition, Mc Grow –Hill Book Company, New York.
- Mishra A, Poddar A. 2016. Histopathology of the liver of Indian Murrel *Channa punctatus* (Bloch) exposed to Phenolic Effluents. *International Journal of Research in Chemistry and Environment*. 6(4):16-21.
- Nayan SR. 2012. Histopathological alterations in the kidney of *Cyprinus carpio* after exposure to Dimethoate (EC 30%). *Indian Journal of Scientific Research*. 3(1):127-131
- Osman, M.M., E.L.-Fiky S.A., Soheir Y.M. and A.I. Abeer, 2009. Impact of water pollution on histopathological and eletrophoretic characters of *Auriochromis niloticus* fish. *Res.J. Environ. Toxicol.*3(1). 9-23.
- Sangeeta, Anand K, Jha V., 2020. Toxicity of Ammonium chloride on fish behavior and histopathology of air breathing fish *Clarias batrachus* (Linn.). *JETIR. India*. Vol(7),11.
- Sastri K.V. & Gupta P.K. 1978. Effect of mercuric chloride on the digestive system of *Channapunctatus*: A histopathological study. *Environmental Research*; 16:270-278.
- Shukla L. A. Srivastva D. Meoxaoi and A. K. Pandey A. K. 1984. Effect of sub-lethal malathion on ovarian histopathology in *Sarotherodon mossambicus* Comp. *Physiol. Eco.* 9. 12.
- Sokal, R.Z., C.E. Madding and R.S. Swerdloff 1985. Lead toxicity and the hypothalamicpituitary testicular axis. *Biol. Reprod.*, 33, 722-728.
- Sprague, J.B., 1971. Measurement of pollution toxicity to fish. III. Sub – lethal effects and ‘safe’ concentration, *Water Res.*5: 245-266.
- Shyni SD, Sreedhar KS. 2014. Effect of urea, an agrochemical on the histology of black clam, *Villorita cyprinoides*. *Fishery Technology*. 51:162-166.
- Takashima, F., Hibiya T. 1982. An atlas of fish histology: normal and pathological features. Kodansha, distributed by Fischer, G., Tokyo; 147.
- Thurston, R. V., R. C. Russo, and C. E. Smith. 1978. Acute toxicity of ammonia and nitrite to cutthroat trout fry. *Transactions of the American Fisheries Society* 107:361– 368.
- Tilak K. S., Koteswara Rao and K. Veeraiah, 2005. Effects of chlorpyrifos on histopathology of the fish *Catla catla*, 1. *Eeotoxicol. Environ. Monit.* 15(2), 127-140
- Tilak KS, Veeraiah K, Yacobu K. 2001. Studies on histopathological changes in the gill, liver and kidney of *Ctenopharyngodon idellus* (Valenciennes) exposed to technical fenvalerate and EC 20%. *Pollution Research*. 2001; 20:387-393.
- Ullah R., Zuberi A, Naeem M, Ullah S. 2015. Toxicity to Haematology and Morphology of Liver, Brain and Gills during Acute Exposure of Mahseer (*Tor putitora*) to Cypermethrin. *International Journal of Agricultural Biology*. 17: 199–204.
- Vidal, M., Lopez, A., Santoalla, M.C. and Valles, V. 2000. Factor analysis for the study of water resources contamination due to the use of livestock slurries as fertilizer. *Agricultural Water Management*, 45: 1-15.
- Vinodhini R, Narayanan M. Heavy metal induced histopathological alterations in the selected organs of *Cyprinus carpio*. *International Journal of Environmental Research*. 2009; 3(1):95-100.
- Zutshi, B.2005. Ultrastructural studies on the effect of fenthion on pituitary (GTH cells) and testis of *Glassogobius giuris* (HAM) during breeding phase. *J. Environ. Biol.*, 26 (1), 31-36.

How to cite this article:

Arti Kumari and Deep Gupta. 2021. Effect of Di-ammonium Phosphate on Histopathology of Some Vital Organs in Climbing Perch *Anabas testudineus* (Bloch.). *Int.J.Curr.Microbiol.App.Sci*. 10(03): 2008-2016. doi: <https://doi.org/10.20546/ijcmas.2021.1003.256>